

**Case Report**

## THE FIRST REPORT OF ABERRANT CORNEAL OCCLUSION IN RABBIT IN IRAN

\*Bahador Bardshiri, Mehdi Tavana and Seyedeh Zeinab Peighambarzadeh

Department of Veterinary Medicine, Faculty of Agriculture and Veterinary Medicine, Shoushtar Branch, Islamic Azad University, Shoushtar, Iran

\*Author for Correspondence

### ABSTRACT

Formation of a conjunctival membrane over the corneal surface is a condition unique to rabbits that has been labeled aberrant corneal occlusion or pseudopterygium. In the summer of 2013, a five years old male Standard Chinchilla rabbit were presented to Karaj Central Veterinary hospital and the owner complained that his rabbit shows degrees of blindness and there were opacities on both eyes of the presented rabbit.

**Keywords:** Rabbit, Aberrant Corneal Occlusion, Surgical Treatment

### INTRODUCTION

Progressive occlusion of the cornea with a conjunctiva-like membrane is an unusual abnormality unique to rabbits. It appears as a thin double layered fold of the bulbar and palpebral conjunctiva, which progressively covers the cornea 360° (Allgoewer, 2008).

A variety of names -pseudopterygium, precorneal membranous occlusion, aberrant conjunctival overgrowth, or conjunctival centripetalization have been given to this progressive condition and it is a pain-free condition that may affect one or both eyes (Praag, 2013).

Ophthalmic examination reveals a circular membrane that originates at the limbus (the junction of the cornea and sclera) and gradually advances over the cornea. In severe cases, only a small central opening is present, allowing visibility of an otherwise normal globe (Dupont, 1995).

The definitive etiology of the disease is unknown. It appears the result of an inflammatory process or a traumatic event that leads to the adherence of a fold of the conjunctiva to the cornea, near the border of the cornea and the sclera (corneal limbus) or more centrally.

Breed, age, and sex of the rabbits seem to play a role, as male dwarfs, aged between 5 and 12 months are more particularly affected. It appears congenital in some cases. A further possible cause for pseudopterygium may be ultraviolet radiation (Allgoewer, 2008; Praag, 2013; Delaney, 1995).

Progressive membranous occlusion in rabbits has been compared with pterygium in humans. However, in humans the membrane is triangular and adherent to the cornea, whereas in rabbits it is non-adherent and circumferential from the limbus (Roze, 2004).

Herein we described the clinical presentation and therapy of aberrant corneal occlusion in a 5 years old Standard Chinchilla rabbit.

### CASES

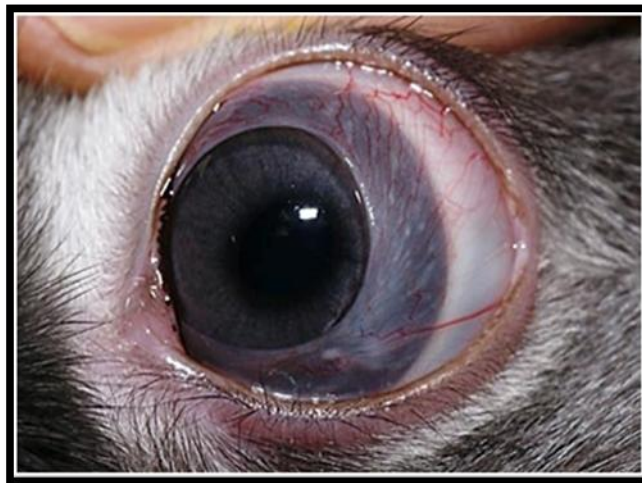#### **Case Description and Clinical Findings**

In the summer of 2013, a five years old male Standard Chinchilla rabbit were presented to Karaj Central Veterinary hospital and the owner complained that his rabbit shows degrees of blindness and there were opacities on both eyes of the presented rabbit.

Ophthalmic examination of the affected eyes revealed a conjunctival fold stretching over the cornea of both eyes.

The fold originated from limbus and it was vascularized and centrally thickened. There were no attachments to the corneal epithelium and the fold could be easily lifted (figure 1).

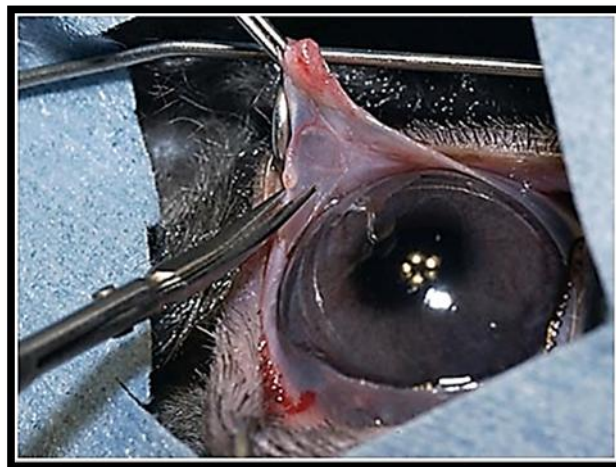
### **Case Report**



**Figure 1: Conjunctival fold stretching over the cornea**

### **Treatment**

Surgery was performed under general anesthesia. The conjunctival fold was incised centrifugally up to its attachment at the limbus and the lid margin using small scissors (figure 2). The central rim of the segment was then replaced to its normal position in the fornix and fixed with mattress sutures (7/0) passing through outside skin. After the surgery, eye drops containing dexamethasone, gentamicin and polymixin were applied twice daily up to 3 weeks and after this period the sutures were removed. Within the observation period (8 months) no recurrence was noted.



**Figure 2: Surgery was performed on eyes and conjunctival fold was incised**

### **DISCUSSION**

As previously described, the Etiopathogenesis of aberrant corneal occlusion remains unclear. Collagen dysplasia has been postulated as a possible cause for the deranged conjunctival growth resulting in centrifugally constricting sheet of conjunctival tissue. This everted conjunctival part, covers variable percentages of the corneal surface (Allgoewer, 2008). Because treatment with topical antibiotic or antibiotic-steroid medications has no effect, the membrane should be resected surgically and treated with topical antibiotics postoperatively; this usually results in quick recurrence of the membrane. However, if the membrane is resected a few millimeters beyond the limbus and the eye is then treated with a topical antibiotic-steroid combination, recurrence may be prevented (Allgoewer, 2008; Praag, 2013). Good

### **Case Report**

results have also been obtained with surgical resection and the use of topical cyclosporine with or without corticosteroids. Another described surgical technique is to incise the membrane into four to six quadrants and suture each quadrant of the membrane to the inside of the eyelid. With this technique, recurrence may be prevented for at least 1 year (Allgoewer, 2008). Within the observation period (8 months) no recurrence was noted for this rabbit.

### **REFERENCES**

- Allgoewer I, Malho P and Schulze H et al., (2008).** Aberrant conjunctival stricture and overgrowth in the rabbit. *Veterinary Ophthalmology* **11** 18-22.
- Delaney KH (1995).** Diagnostic exercise: Apparent corneal occlusion in a New Zealand white rabbit. *Contemporary Topics in Laboratory Animal Science* **34** 76-77.
- Dupont C, Carrier M and Gauvin J (1995).** Bilateral precorneal membranous occlusion in a dwarf rabbit. *Journal of Small Exotic Animal Medicine* **3** 41-44.
- Praag EV (2013).** Aberrant corneal occlusion or pseudopterygium. Available: [www.medirabbit.com](http://www.medirabbit.com).
- Roze M, Ridings B and Lagadic M (2001).** Comparative morphology of epicorneal conjunctival membranes in rabbits and human pterygium. *Veterinary Ophthalmology* **4** 171-174.