

**Research Article**

## **AUTOMATIC TRACKING OF VENUS VALVE MOVEMENT IN ULTRASOUND IMAGES**

**\*Hossein Malekinezhad<sup>1</sup>, Soghra Lazemi<sup>2</sup> and Ali Azimi Kashani<sup>3</sup>**

<sup>1</sup>*Department of Computer Engineering, Naragh Branch, Islamic Azad University, Naragh, Iran*

<sup>2</sup>*Department of Computer Engineering, University of Kashan, Kashan, Iran*

<sup>3</sup>*Department of Computer Engineering, Shoushtar Branch, Islamic Azad University, Shoushtar, Iran*

*\*Author for Correspondence*

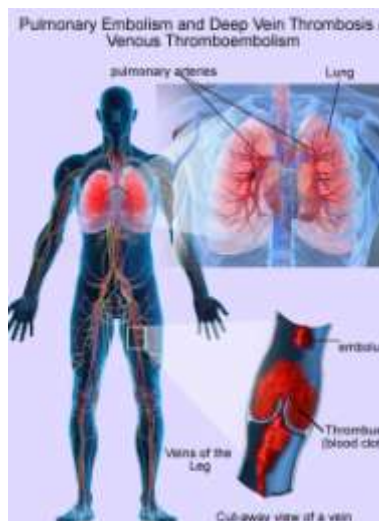### **ABSTRACT**

The diagnosis of Deep Vein Thrombosis (DVT) is commonly conducted by monitoring the blood velocity and present of thrombus in vessel from B-mode ultrasound image associated with the Doppler ultrasound. Since it is difficult to recognize the vessel condition at the early stage of DVT, this study is proposed to evaluate the vein mechanism at the early stage of DVT. The venous valve behavior is considered to be the important parameters to construct a clinical model of DVT risk factor, thereby constitutes an important contribution for predicting probability of Deep Vein Thrombosis (DVT). However, manual visualization in clinical experiment depends on subjective assessment leads to false alarm in diagnostic of early stage of DVT. In this paper, an image-processing algorithm is proposed to automate the process of tracking the venous valve movement from the ultrasound image. Initially an adaptive histogram equalization and filter are used to enhance the ultrasound image for accurate and better image. Next, the venous valve region is extracted from the background by using global threshold method applied on preprocessing image. Following that, information from the ROI area is extracted using morphological operator to determine the venous valve features. Taken together, the experimental results provide important insights of image processing to monitor venous valve behavior. These findings have important implications as a base for future application of image processing in early stage of DVT diagnostic.

**Keywords:** *Deep Vein Thrombosis \* Ultrasound Image processing \* Segmentation \* Morphological*

### **INTRODUCTION**

Venous thromboembolism (VTE) is an important cause of morbidity and mortality. VTE consists of 2 related conditions: 1) deep vein thrombosis (DVT) and 2) pulmonary embolism (PE) as shown in Figure 1. DVT occurs when a deep vein is partially or completely blocked by a blood clot, most commonly in the legs. The clot may break off and travel to the vessels in the lung, causing a life-threatening PE.

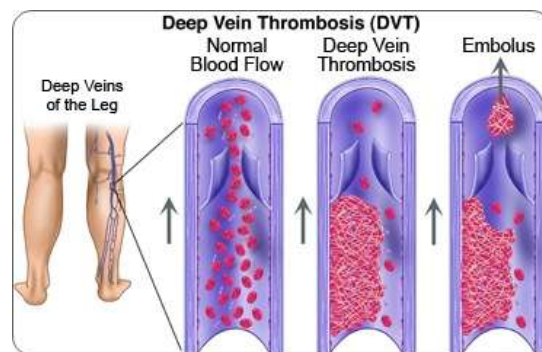


**Figure 1: Venous Thromboembolism (Med India, 2013)**

## Research Article

DVT can be diagnosed using non-invasive technique such as ultrasonography. One of the techniques is venous duplex ultrasound (VDUS) (Gornik and Sharma, 2014). This technique is combination of two components which are colour Doppler imaging (CDI) and brightness-mode (B-mode) compression maneuverers. CDI is applied to evaluate blood circulation while B-mode is used to detect 2D structure image of vein to identify blood clot presence.

One of the factors that contribute to DVT is deep vein valve insufficiency. Deep vein is travel deep within the muscle of the leg. A proximal lower-extremity DVT (defined as occurring in the popliteal vein and above) is linked to an estimated 50% risk of PE if not treated; while approximately 20% to 25% of calf vein thrombi propagate (in the absence of treatment) to involve the popliteal vein or above. Approximately 10% of all DVT cases involve the upper extremities (Kucher, 2011). Complications are more common following DVT in the upper extremities than in the lower. The popliteal vein valve is located at the level of the groin, near the middle of the thigh, behind the knee and in the smaller veins in the calf. The healthy vein valves control blood flow direction towards the heart. Valvular reflux occurs when valves not competent or unhealthy which allows blood to flow in the reverse direction (Goldhaber, 2002). Figure 2 illustrates incompetence of venous valve.



**Figure 2: Incompetence of venous valve (Verillo and Scitzler, 2005)**

Many researchers have been done to study the diagnosis and treatment of patients with high risk of developing VTE. However, far too little attention has been paid to methods of early prevention of the disease especially on deep vein valve behavior. Therefore, this project will focus on detection and tracking venous valve movement on deep vein ultrasound images (B-mode image) which will contribute to further research on early diagnosis of DVT. Finally, a new clinical model of DVT risk factors based on venous valve behavior can be proposed thereby constitutes an important contribution for predicting probability of Deep Vein Thrombosis disease.

In this paper, a quantitative evaluation based on image processing to track venous valve movement is proposed. This procedure significantly reduces the tedious manual diagnostic of DVT. The rest of the paper is organized as follows: Section 2 presents the overview of image enhancement and vessel tracking following by development of venous valve tracking algorithm in Section 3; Next, Section 4 shows experimental results with discussion; and finally, the conclusions and future research are presented in Section 5.

### Image Enhancement and Vessel Tracking

#### Ultrasound Imaging

Basically, ultrasound imaging system used high frequency sound waves as imaging method. This ultrasound device is non-ionized system therefore it is quite popular for non-invasive diagnostic device. The device is capable to display structure and movement of the human's internal organs including blood vessels. This imaging system is consists three basic types of data which are Radio Frequency (RF) signals, B-Mode images and envelope-detected signals. In medical application, there are many available modes of ultrasound such as A-mode, B-mode, Colour Doppler and Continuous Doppler (Pizer et al., 1990).

### **Research Article**

Noble and Bokkeroui (2006) suggest that the ultrasound image can contain noise such as speckle noise. This noise degrades the fine details and edge definition of ultrasound images. There will be difficult to detect small and low contrast lesions in body due to the noise ability of limits the contrast resolution. All noises that developed is due to air gap between ultrasound transducer and body is occur during imaging process, during beam forming process and during stage of signal processing. Therefore, image enhancement process need to apply before further analysis can be applied to the ultrasound images.

### **Image Enhancement**

Basically, image enhancement is an image processing technique to get a better and accurate image to interpret correctly. The examples of image enhancement's techniques are noise filtering, contrast stretching and histogram modification (Rao, 2006). Usually, any filter type such as median filter or mean filter can be used to remove the unwanted information from an image. Contrast stretching is a technique can be used for image that has homogenous histogram.

The techniques will expanse the narrow range to the entire of the existing dynamic range. Histogram is important to image processing as it gave the characteristic of image such as intensity and pixels. The modification of histogram can change the image's characteristics.

One of histogram modification technique is histogram equalization which redistributes pixel values to create flat histogram. Contrast-Limited Adaptive Histogram Equalization (CLAHE) is one of promising technique of histogram equalization (Pizer *et al.*, 1990).

Vanithamani *et al.*, (2010) propose modified Hybrid Median Filter to reduce speckle noise. In moving window of 5x5 pixel neighbourhood, the maximum value of 45° neighbours creating an "X" form and median value of 90° neighbours creating an "+" form are compared with the central pixel to get median value. Then, the value is saved as the new pixel value.

The proposed filter capable to reduce speckle noise efficiently compared to others filter without blurring the edges of image. Particle Swarm Optimization (PSO) technique is introduced to reduce speckle noise in ultrasound image (Roomi and Rajee, 2011).

The technique minimized the variance value in the sample uniform area of image by optimized the selection of weighting factors of neighbourhoods of each corrupted pixel.

Thangavel *et al.*, (2012) apply particle filter technique for segmentation process of Common Carotid Artery (CCA) B-mode images. Combination of Gaussian noise and anisotropic diffusion filter is used to remove speckle noise.

The Gaussian noise is added to the image and then the image is filtered with Speckle reducing anisotropic diffusion (SRAD) technique.

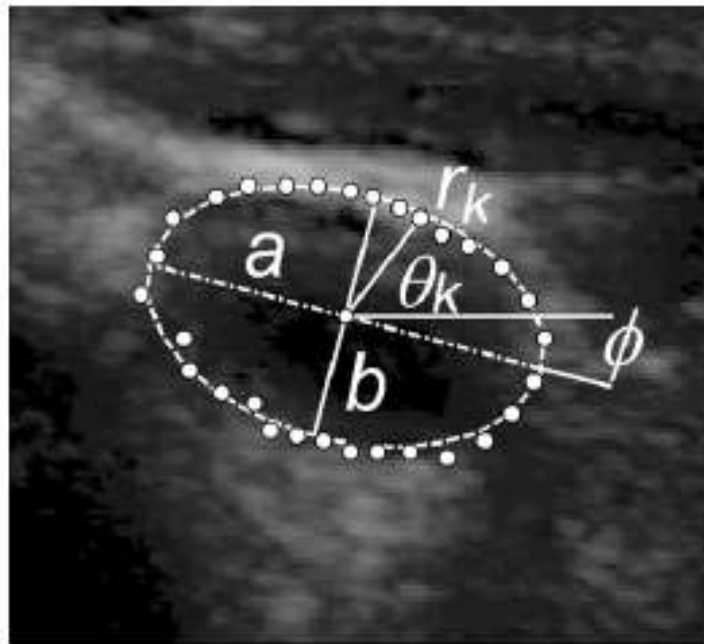
The SRAD technique is performed simultaneously for enhancement of contrast and reduction of noise. For segmentation and tracking, initialized seed points start the contour segmentation. The circular shape is used as basic idea for contour extraction method due to shape of artery is resemble to circular shape.

The function of particle filter will create based on intensities of pixels inside and outside the contour. From the experiments result, the purposed technique is accomplished to segment and identify the CCA wall from the ultrasound images.

Guerrero *et al.*, (2007) propose the segmentation and tracking of vessel in ultrasound images using Kalman Filter. In this method, vessel boundary and ellipse parameters for vessel are determined by using extended Kalman filter and elliptical vessel model as shown in Figure 4.

Ellipse model is used rather than circle model as edge contour for vein due to compression of vein during ultrasound imaging. The edge of the ellipse model for vein and its parameters is calculated by the extended Kalman filter.

## Research Article



**Figure 4: Ellipse model for transverse vessel area. The parameters for elliptical model are  $a$ ,  $b$ ,  $\phi$ . Each contour point can be described in polar coordinates (Guerrero *et al.*, 2007)**

### Object Detection and Tracking

Object detection and tracking (OD&T) is one of the primary objectives for this study. It is used in many applications such as face detection, road traffic control and medical imaging. Karasulu (2010) defines the object tracking in videos as the process of segmenting an object of interest from a sequence of video scenes.

Motion, orientation, occlusion and others information for the video should keep during this process. OD&T techniques can be divided generally into two groups, which are target object is behaved independently and not behaved independently (Mihaylova *et al.*, 2007).

The venous valve movement can be categorized as behaved independently because the movement of valve only on their own path and not overlapped with each other path.

For tracking technique, the objects need to be represented either by their appearances or shapes (Yilmaz *et al.*, 2006).

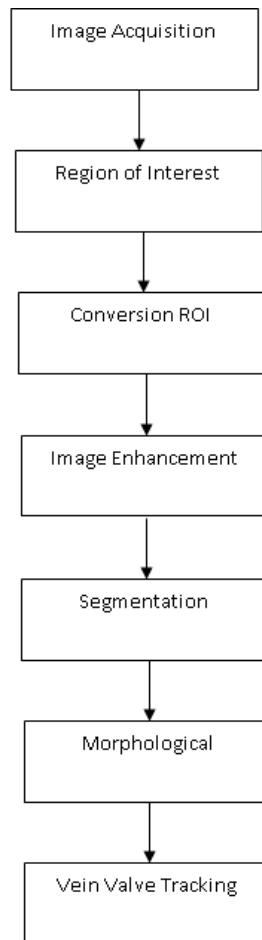
There is strong relationship between tracking algorithm and object representation. The selection of object's features for tracking is important. The object's features for tracking can be edge contour, intensity and texture.

The tracking technique also requires object detection mechanism such as point detectors, segmentation, background modelling and supervised classifier.

### Venous Valve Image Processing

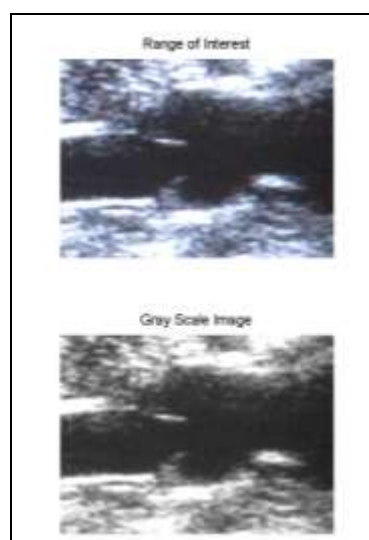
Figure 5 provides a flowchart of proposed venous valve image processing. It starts with image acquisition from ultrasound devices and end with vein valve tracking by using particle filter.

**Research Article**



**Figure 5: Venous Valve Image Processing**

The ultrasound machine with the linear transducer with frequency range of 6MHz to 12MHz is used to acquire the ultrasound image. Patients are placed in either prone position, or seated on the edge of the bed with the knee flexed and the foot supported.



**Figure 6: Conversion from RGB Image to Grayscale Image**

**Research Article**

The sonographic evaluation is performed by compressing the vein directly under the transducer while watching for complete apposition of the anterior and posterior walls. Initially, the region of interest (ROI) is identified since the venous valve movement is relatively small and difficult to track as shown in Figure 6. Next, the captured RGB image is converted into a grayscale image to make it convenient for the next processing as shown in Figure 6.

**Image Enhancement**

A contrast enhancement method and noise filtering are applied to accentuate the image features for subsequent analysis. For contrast enhancement, Contrast-limited Adaptive Histogram Equalization (CLAHE) is used to modify histogram of ROI image. Next, the hybrid median filter is used to filter the unnecessary information from the image.

**Contrast-limited Adaptive Histogram Equalization (CLAHE)**

CLAHE is a type of adaptive histogram equalization. The original image is divided into a contextual region (M x N). Each pixel of original image is in the centre of the contextual region. The original histogram is clipped and the clipped pixels are restructured to each gray level. The equation below describes the average number of pixels in each gray level:

$$N_{aver} = \frac{N_{CR-xp} \times N_{CR-yp}}{N_{gray}} \tag{1}$$

Where,

$N_{aver}$  is the average number of pixels;

$N_{gray}$  is the number of the gray level in the contextual region;

$N_{CR-xp}$  is the number of pixels in the x dimension of the contextual region;

$N_{CR-yp}$  is the number of pixels in the y dimension of the contextual region;


Therefore, from equation 1, the actual clip-limit  $N_{CL}$  can be calculated as below:

$$N_{CL} = N_{CLIP} \times N_{aver} \tag{2}$$

$N_{clip}$  is the maximum multiple of average pixels in each gray level of the contextual region.

**Hybrid Median Filter**

Hybrid Median Filter (HMF) is nonlinear and adaptive filter. In moving window of 5x5 pixel neighbourhood as shown in Figure 7, the median values of 45° neighbours creating an “X” form and median value of 90° neighbours creating an “+” form are compared with the central pixel to get a median value. Then, the value is saved as the new pixel value.



**Figure 7: Example for window 5x5**

The concept of the HMF algorithm as follow:

1. Find the median MR for the marked R pixels and central pixels C in the window 5x5.
2. Find the median MD for the marked D pixels and central pixel C in the window 5x5.
3. Compute  $M = \text{median} (MR, MD, C)$
4. Filter value  $y_{i,j} = M$

### Research Article

After the enhancement image process, the image is inverted so that the venous valve colour is changed from white to black, as it is much easier to process the black colour image.

### Image Segmentation

The purpose of image segmentation is to get an image into meaningful non-overlapping regions. The concept of segmentation is based on these assumptions:

- Different regions have different intensity value.
- Within each region, which represents the corresponding object in a scene, the intensity values are similar.

The thresholding is used to extract an object from its background by assigning an intensity value  $T$  (threshold) for each pixel such that each pixel is either classified as an object point or a background point. The  $T$  is usually located at the valley or one of the valleys. The value of  $T$  is determining based on mode of histogram either single threshold or multiple threshold. As shown in Figure 8, it shown that the valley of histogram is not clearly distinguishes. Therefore, the optimal thresholding technique which is Otsu's Thresholding Method is applied.

Basically, the threshold is chosen to minimize the within-class variance of the thresholded black and white pixels. It operates directly on the gray level histogram. The method is based on these assumptions:

- Histogram is bimodal.
- No use of spatial coherence, or any other notion of subject structure.
- Assumes stationary statistics, but can be modified to be locally adaptive.
- Assumes uniform illumination, so the bimodal brightness behavior arises from object appearance differences only.

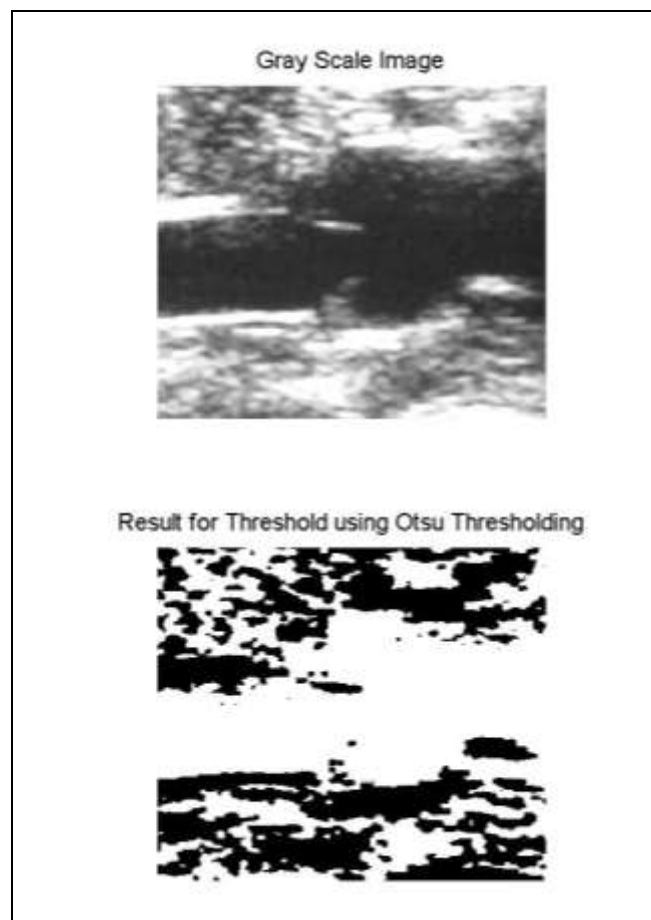

Figure 8: Thresholding process

## Research Article

### Morphological Operation

Morphological is image processing that based on shapes. A structuring elements (SE) is applying to input image and creating same size of output image. The concept is output image's pixels are based on comparison of input image's pixels with its neighbours. In this process, the linear structural element is suggested to use with length of 5 pixels with angle of  $90^\circ$ . Dilation and erosion is basic morphological operation where dilation adds pixels while erosion removes pixels on object boundaries. The number of pixels removed or added is based on shape and size of structural element used during image processing.

### Venous Valve Tracking

A particle filter is proposed to track venous valve movement. The particle filter is one type of Bayesian filters that frequently use for dynamic system to estimate its state. The idea of this technique is any probability density function (pdf) can be represented as set of samples (particles). Each particle has one set of values for state variables (hypotheses). The particle will propagate after drawn based on the transition model. A weight assignment process is applying to each particle using likelihood model. Quality of a particle is based on the weight value. Good particle is assign with large weight while bad particle is assign with small particle.

### Preliminary Results

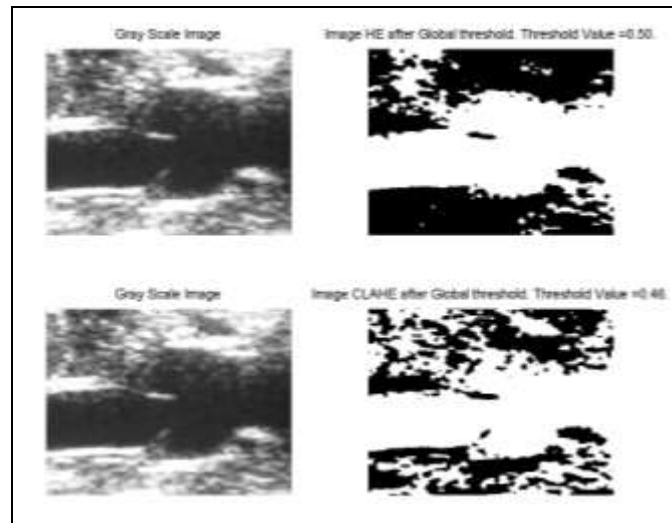


Figure 9: Comparison of Otsu's method on HE and CLAHE images

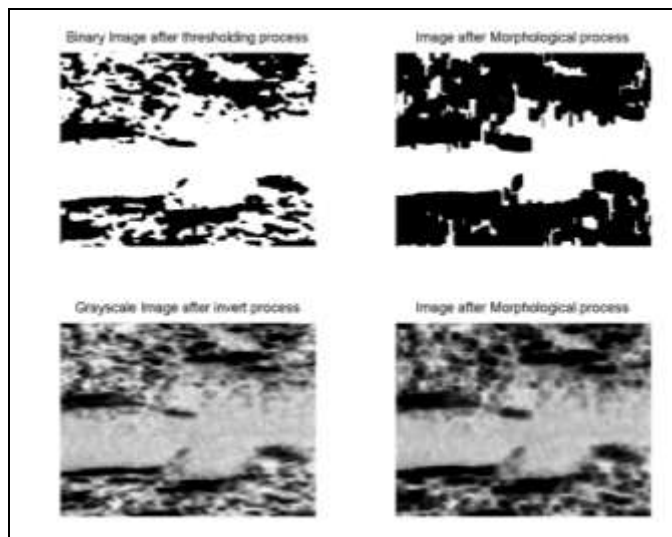


Figure 10: Morphological process result of binary and grayscale images



### Research Article

In this section, the performance of proposed algorithm is evaluated from raw image obtained from the ultrasound machine. The qualities of two main image-processing steps (segmentation and morphological) are presented to identify the best method for further development of venous valve tracking algorithm. The histogram tonal distribution measurement is used to evaluate the quality of proposed image processing algorithm.

An automatic global threshold (Otsu's Method) is used for segmentation process. Figure 9 show that the threshold value for histogram equalization (HE) image is 0.5 while the CLAHE image is 0.46. From the images, it shown that the venous valve in CLAHE image can be seen clearly compared to the HE image.

As for morphological process of ROI image, the applied EEEDE process shows a good performance to enhance venous valve features (area and shape) in both binary and grayscale images as shown in Figure 10. The process is conducted heuristically involving three times erode, one time dilates and one time erodes. The structural element used is linear shape with length of 5 pixels and angle of 90°.

### Conclusion

In this paper, a framework for automatically to track venous valve movement is proposed. The developed algorithm for each block of venous valve image processing blocks gave a good performance during task completion with an acceptable error. Otsu segmentation and morphological methods applied on ROI image with a series of pre processing (contrast enhancement and filter) is found to effectively extract solid venous valve shape from the background. Apparently, it can be concluded that the developed algorithm shows more promising result to complete overall venous valve tracking algorithm.

### REFERENCES

- Goldhaber SZ (2002).** Pulmonary Embolism and Deep Vein Thrombosis, *Circulation* **106**(12) 1436–1438.
- Gornik HL and Sharma AM (2014).** Duplex ultrasound in the diagnosis of lower-extremity deep venous thrombosis, *Circulation* **129**(8) 917–21.
- Guerrero J, Salcudean SE, McEwen J, Masri B and Nicolaou S (2007).** Real-time vessel segmentation and tracking for ultrasound imaging applications, *IEEE Transactions on Medical Imaging* **26**(8) 1079–90.
- Karasulu B (2010).** Review And Evaluation Of Well-Known Methods For Moving Object Detection And Tracking In Videos, *Journal of Aeronautics and Space Technologies* **4**(4) 11–22.
- Kucher N (2011).** Clinical practice. Deep-vein thrombosis of the upper extremities. *The New England Journal of Medicine* **364** 861-869.
- Med India (2013).** Pulmonary Embolism and Deep Vein Thrombosis/Venous Thromboembolism. Health Information.
- Mihaylova L, Brasnett P, Canagarajah N and Bull D (2007).** Object Tracking by Particle Filtering Techniques in Video Sequences. *Advanced and Challenges in Multisensor Data and Information, NATO Security Through Science Series (IOS Press) Netherlands* **8** 260-268.
- Noble JA and Boukerroui D (2006).** Ultrasound image segmentation: a survey, *IEEE Transactions on Medical Imaging* **25**(8) 987–1010.
- Pizer SM, Johnston RE, Erickson JP, Yankaskas BC and Muller KE (1990).** *Contrast-Limited Adaptive Histogram Equalization: Speed and Effectiveness*, edited by Stephen M Pizer, Eugene Johnston R and James.
- Rao KMM (2006).** Overview of Image Processing, *Readings in Image Processing* 1–7.
- Roomi SMM and Rajee RBJ (2011).** Speckle noise removal in ultrasound images using Particle Swarm Optimization technique, *2011 International Conference on Recent Trends in Information Technology* 926–931.
- Thangavel M, Chandrasekaran M and Madheswaran M (2012).** Analysis of B-mode transverse ultrasound common carotid artery images using contour tracking by particle filtering technique, *2012 International Conference on Devices, Circuits and Systems* 470–473.
- Vanithamani R, Umamaheswari G and Ezhilarasi M (2010).** Modified Hybrid Median Filter for Effective Speckle Reduction in Ultrasound Images (1) 166–171.

**Research Article**

**Verillo M and Shnitzler D (2005).** Interventional Radiology Clot-busting Treatment Prevents Permanent Leg Damage [Online]. Available: <http://www.sirweb.org>.

**Yilmaz A, Javed O and Shah M (2006).** Object tracking, *ACM Computing Surveys* **38**(4) 13–es.