

**Research Article**

**NEW STUDY OF STAPS OSSICLES AND IT' S ULTRASTRUCTURAL FEATURES IN HEARING AND MIDDLE EAR BY SCANNING ELECTRON MICROSCOPE. (SEM)**

**\*Reihane Heidari<sup>1</sup>, Seead Mehdi Hejazi <sup>2</sup>, Hassan Mahboubipoure <sup>3</sup>**

<sup>1</sup>*Amiralam Hospital, School of Medicine, Tehran University of Medical Sciences, Tehran Iran*

<sup>2</sup>*Anatomy Department, School of Medicine, Shahid Beheshti University of Medical Sciences, Tehran, Iran*

<sup>3</sup>*Noor Eye Hospital, Tehran, Iran*

*\*Author for Correspondence*

**ABSTRACT**

The method of microanalysis of element by X-ray is a high technology instrument. This method helps to researcher for element microanalysis of bony structure to have a pattern of normal histological structure. May be in the case of hearing loss one of the problem be histological ultra structure in bony structure. The objective of this study was to evaluate the normal microchemical structure pattern of the Stapes by Scanning Electron Microscopy images and Energy-Dispersive X-Ray microanalysis. In our Observations study, 3 stapes bone autopsy from middle ear of males cadavers (45-70years old). After standard SEM process, fixed ossicles and put in the microscope chamber. After taking microphotograph by (Zise, DSM.940) with an energy-dispersive x-ray analyzer equipment (Oxford Instruments Analytical). The data evaluated by Oxfords software and data obtained as: O=42.75%, Ca 21.95%, C=16.70%, P=10.15%, Si=3.49%, Al=2.85%, Fe=1.29%, Mg=0.71 %, K=0.14% Carbon from 0.25 ~ 2.52, Oxygen from 0.80 ~ 8.02, Magnesium from -0.02 ~ 0.13, Calcium from 0.45 ~ 6.30, Aluminum from -0.09 ~ 0.18, Selenium from 0.03 ~ 0.86, Potassium from 0.00 ~ 0.05, Iron from 0.02 ~ 0.45, Phosphor from 0.58 ~ 1.42. This finding shows in the each other of samples, Elman contents and rats are different (Figure 1, 2, 3) and also this study show that Oxygen, Calcium, Carbon and Phosphorous as the four main mineral composition of the Stapes; The elements Selenium, Aluminium, Iron, Magnesium and Potassium are also present in lesser degree. Comparison of information of our study with study of the Vallejo shows statistical Difference it may be related to difference of race, to researches.

We suggest that this kind of modern study maybe help to ENT specialist and prothesiset in the case of hearing loss and developed patient treatments.

**Keywords:** *Ear Ossicles, Electron Microscope, Ultra structure, steps*

**INTRODUCTION**

One of the important reason in hearing loss or inherited disease is belong to ultra structural changing of steps , bass to report of researchers, This is an. Otosclerosis can result in conductive and/or sensorineural hearing loss. The primary form of hearing loss in otosclerosis is conductive hearing loss (CHL) whereby sounds reach the ear drum but are incompletely transferred via the ossicular chain in the middle ear, and thus partly fail to reach the inner ear (cochlea). This usually will begin in one ear but will eventually affect both ears with a variable course. On audiometry, the hearing loss is characteristically low-frequency, with higher frequencies being affected later. Sensorineural hearing loss (SNHL) has also been noted in patients with otosclerosis; this is usually a high-frequency loss, and usually manifests late in the disease. The causal link between otosclerosis and SNHL remains controversial (WHO, 1996; Peter, 1995).

Approximately 0.5% of the population will eventually be diagnosed with otosclerosis. Post mortem studies show that as many as 10% of people may have otosclerotic lesions of their temporal bone, but apparently never had symptoms warranting a diagnosis. Caucasians are the most affected race, with the prevalence in the Black and Asian populations being much lower. In clinical practice otosclerosis is encountered about twice as frequently in females as in males, but this does not reflect the true sex ratio.

### **Research Article**

When families are investigated it is found that the condition is only slightly more common in women (Peter, 1995). Usually noticeable hearing loss begins at middle-age, but can start much sooner. The hearing loss was long believed to grow worse during pregnancy, but recent research does not support this belief (Valdezate *et al.*, 2000; Moore, 1995).

### **Pathophysiology**

The pathophysiology of otosclerosis is complex. The key lesions of otosclerosis are multifocal areas of sclerosis within the endochondral temporal bone. These lesions share some characteristics with Paget's Disease, but they are not thought to be otherwise related. Histopathologic studies have all been done on cadaveric temporal bones, so only inferences can be made about progression of the disease histologically. It seems that the lesions go through an active "spongiotic"/ hypervascular phase before developing into "sclerotic" phase lesions. There have been many genes and proteins identified that, when mutated, may lead to these lesions. Also there is mounting evidence that measles virus is present within the otosclerotic foci, implicating an infectious etiology (this has also been noted in Paget's Disease (Moore, 1998; Aitchison *et al.*, 1988; Valdezate *et al.*, 2000).

CHL in otosclerosis is caused by two main sites of involvement of the sclerotic (or scar-like) lesions. The best understood mechanism is fixation of the stapes footplate to the oval window of the cochlea. This greatly impairs movement of the stapes and therefore transmission of sound into the inner ear ("ossicular coupling"). Additionally the cochlea's round window can also become sclerotic, and in a similar way impair movement of sound pressure waves through the inner ear (acoustic coupling) (Peter, 1995; Valdezate *et al.*, 2000).

HL in otosclerosis is controversial. Over the past century, leading otologists and neurotologic researchers have argued whether the finding of SNHL late in the course of otosclerosis is due to otosclerosis or simply to typical presbycusis. There are certainly a few well documented instances of sclerotic lesions directly obliterating sensory structures within the cochlea and spiral ligament, which have been photographed and reported post-mortem. Other supporting data includes a consistent loss of cochlear hair cells in patients with otosclerosis; these cells being the chief sensory organs of sound reception. A suggested mechanism for this is the release of hydrolytic enzymes into the inner ear structures by the spongiotic lesions (Peter, 1995; Aitchison *et al.*, 1988; Valdezate *et al.*, 2000).

In the Grey's Anatomy episode "Perfect Little Accident", Dr. Sloan diagnoses otosclerosis in a car accident victim after a fortuitous glance at her cranial CT scans. He subsequently restores her hearing with surgery (WHO, 1996; Peter, 1995; Valdezate *et al.*, 2000)

## **MATERIALS AND METHODS**

In our Observation study, 3 stapes bone autopsy from middle ear of males cadavers (45-70years old).

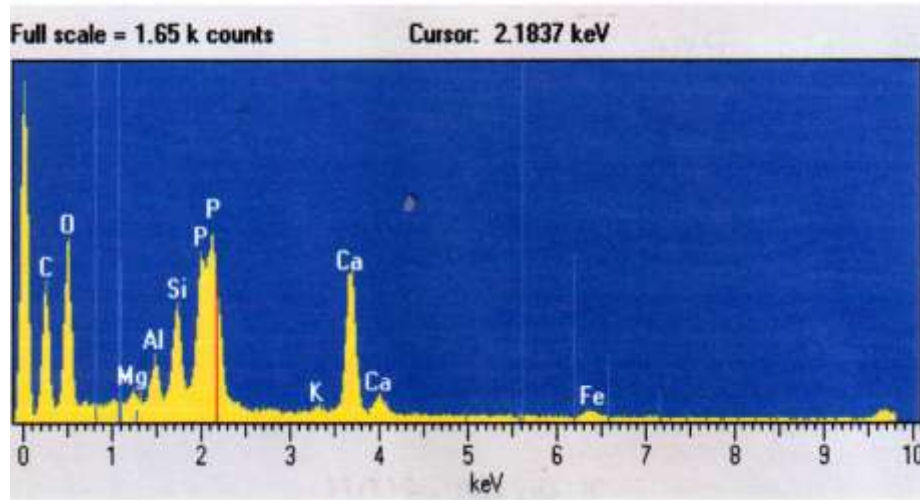
After standard SEM process, fixed ossicles and put in the microscope chamber and study by (Zise, DSM.940) with an energy-dispersive x-ray analyzer equipment (Oxford instruments Analytical).

## **RESULTS AND DISCUSSION**

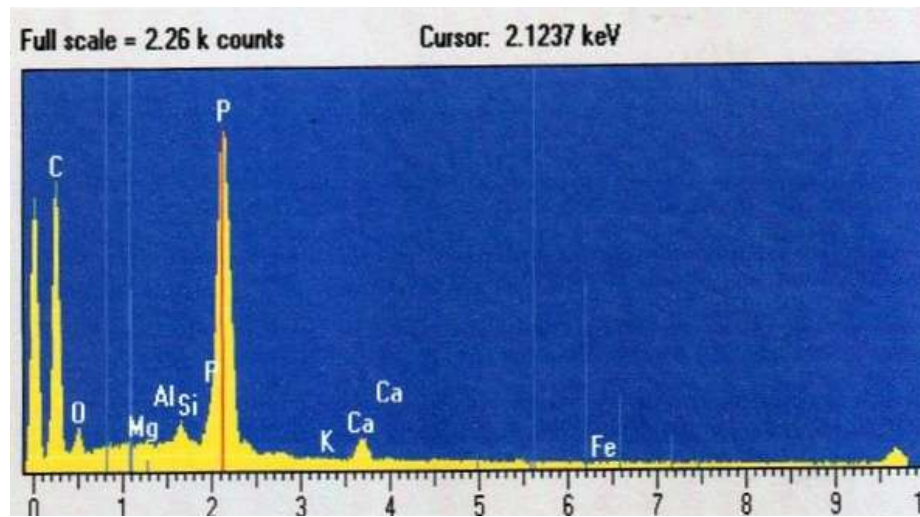
The data evaluated by Oxfords software and data obtained as: O=42.75%, Ca 21.95%, C=16.70%, P=10.15%, Si=3.49%, Al=2.85%, Fe=1.29%, Mg=0.71 %, K=0.14% (Fig 1)

The average of Carbon from 0.25 ~ 2.52, Oxygen from 0.80 ~ 8.02, Magnesium from -0.02 ~ 0.13, Calcium from 0.45 ~ 6.30, Aluminium from -0.09 ~ 0.18, Selenium from 0.03 ~ 0.86, Potassium from 0.00 ~ 0.05, Ferro from 0.02 ~ 0.45, Phosphor from 0.58 ~ 1.42(Fig 2,3) (Table.1)

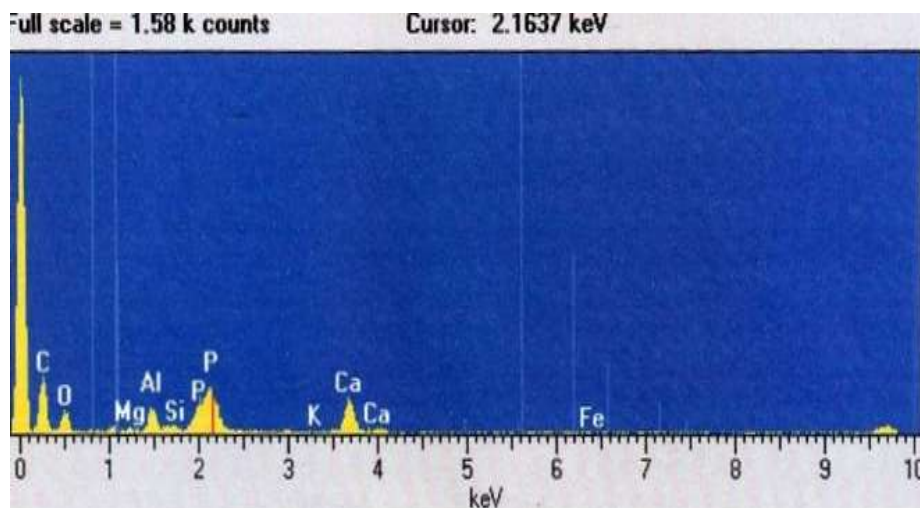
**Research Article**



**Figure 1: Microanalysis of sample No.1, show the count of elements Comparisons each others**



**Figure 2: Microanalysis of sample No.2, show the count of elements Comparisons each others**



**Figure 3: Microanalysis of sample No. 3, show the count of elements Comparisons each others**

**Research Article**

**Table 1 : percent of elements in the 3 sample**

Sample No.	Microelements								
	C	O	Mg	AL	Si	P	K	Ca	Fe
1	16.70%	42.75%	0.71 %	2.85%	3.49%	10.15%	0.14%	21.95%	1.29%
2	27.13%	21.00%	0.95%	1.22%	1.05%	45.05%	0.05%	6.55%	0.5%
3	09.23%	07.21%	0.15%	1.02%	0.76%	05.56%	0.00%	3.21%	0.00%

This finding shows Oxygen, Calcium, Carbon and Phosphorous as the four main mineral composition of the Stapes; The elements Silicium, Aluminium, Iron, Magnesium and Potassium are also present in lesser degree.

Comparison of information of our study with study of the Vallejo shows statistical Difference it may be related to difference of race, topodemic, echodemic, socio economic of sample of to researches (Valdezate *et al.*, 2000; Moore, 1998)

The chemical elements of the bones and specially the ossicles of ears have a significant role in the strength of the bones (WHO, 1996; Peter, 1995) there are different elements in each 3 specimens and the amount of these differs from each to another so it represents that by the change of the level of each element a disorder could happen. this could be a genetically or an acquired disorder (Valdezate *et al.*, 2000; Moore, 1995, 1998) in the wonder home syndrome a genetic deficit in physical and chemical structure leads to hearing loss (Moore, 1998; Aitchison *et al.*, 1988) another research shows that functional disturbance like loss of wave conduction to the inner ear endolymph could leads to hearing loss, hearing dissociation and tinnitus. So as in the sclerosis disease such defects and changing of the elements persists and by knowing these we can help the healing methods (Valdezate *et al.*, 2000) the results of this study is confirmed and show that in every person, there are different anatomical structure of ossicles and it would be useful for physicians to treatment.

**Conclusion**

We suggest that this kind of modern study maybe help to ENT specialist and prothesiset in the case of hearing loss and developing patient treatments.

**ACKNOWLEDGMENTS**

This study was financially supported by electron microscopy center of Shahid Beheshti University of Medical Sciences and the authors are thankful of head of EM Center and Miss Raziee Rohani for excellent technical assistance.

**REFERENCES**

**Aitchison K, Ogilvie D and Thompson E (1988).** Homozygous osteogenesis imperfecta unlinked to collagen I gene structure. *Human Genetics* **78** 233-236.  
**Moore Keith L (1995).** *The Developing Human: Clinically Oriented Embryology* (Saunders) 1375.  
**Moore Keith L (1998).** *Clinically Oriented Anatomy* (Saunders) 776.  
**Peter L Williams (1995).** *Gray s Anatomy* (Churchill livingstone) 1375.  
**Vallejo-Valdezate LA, Jesús Martín-Gil, Manuel José-Yacamán, Francisco Javier Martín-Gil and Luis Maria Gil-Carcedo (2000).** Scanning Electron Microscopy Images and Energy-Dispersive X-Ray Microanalysis of the Stapes in Otosclerosis and VDHS. *The Laryngoscope* **110**(9) 1505–1510.  
**WHO (1996).** *Trace Elements in Human Nutrition and Health* (Word Health Organization, Geneva) **1** 5.