

Research Article

THE EFFECT OF SCOLICIDAL AGENTS ON THE SCOLEX IN THE HYDATID CYST

***Garedaghi Yagoob¹ and Firouzvand Yaghuob²**

¹*Department of Veterinary Parasitology, Collage of Veterinary Medicine, Tabriz Branch, Islamic Azad University, Tabriz, Iran*

²*Department of Veterinary Medicine, Collage of Veterinary Medicine, Malekan branch, Islamic Azad University, Malekan, Iran*

**Author for Correspondence*

ABSTRACT

The aim was to perform an in vitro study of the effects of various scolicidal agents on scolices in both crystal-clear fluid and daughter cysts of hydatid cyst. A 2-staged procedure, using 15% NaCl, 3% NaCl, Betadine, 1% NaOCl, and alcohol, was performed on the cysts. Into bottles containing 10 cysts, 20 mL of each agent, including crystal-clear fluid, was added. A single daughter cyst was then taken from the bottles after 5, 10, 15, 20, 40, 60, and 120 min and the injected samples were examined microscopically for viability using activity and eosin staining. In the second stage of the study, the direct effects of the scolicidal agents on the scolices were investigated at 1, 5, 10, 15, 20, 40, and 60 min. The scolices became inactive and were stained after 1 and 2 min in 15% NaCl and povidone iodine, respectively. The scolices stained completely after 20 min with 3% NaCl, while 1% NaOCl affected the scolices at 5 min. On the other hand, alcohol affected them at 65 min. Scolices in the control group remained viable for 36 h. In the second stage, scolices in the control group were inactivated at 30 min. Complete staining was observed at 5 min with 15% NaCl and at 20 min with 3% NaCl, as in Betadine solution. It was found that 1% NaOCl immediately inactivated the scolices. Lastly, with alcohol, scolices were stained completely at 8 min. It was seen that 1% NaOCl, 15% hypertonic saline, and povidone iodine solutions were effective scolicidal agents against the scolices, both in the crystal-clear fluid and the daughter cysts. On the other hand, 3% hypertonic saline was not effective enough as a scolicidal agent. Alcohol was ineffective, especially on the scolices in the daughter cysts.

Keywords: *Scolicidal Agents, Scoles, Hydatid Cyst.*

INTRODUCTION

Both surgical treatment and percutaneous drainage (PD) have recently been used for the treatment of hydatid cysts (Yorganci and Sayek, 2002; Akhan and Özmen, 1999; Canyigit *et al.*, 2011). Inactivation of the parasite with protoscolicidal agents is an important component of the treatment in both methods. Many agents have been used for such purposes during surgical intervention as well as in PD. The most frequently used agents are hypertonic saline, alcohol, and povidone iodine. As is known, many living protoscolices exist in both crystal-clear fluid and daughter cysts. During surgical treatment and PD, it is important that the agents injected into the cyst be effective on the protoscolices both in the crystal-clear fluid and in the daughter cysts. As the daughter cysts are small samples of the cyst, they are extremely resistant structures and responsible for the survival of the cyst. The effect of protoscolicidal substances on protoscolices in the daughter cysts are not sufficiently well known, though they are, in practice, used very frequently (Karayalçın *et al.*, 1999). In this study, the effects of several protoscolicidal agents on the protoscolices in crystal-clear fluid and daughter cysts were investigated.

MATERIALS AND METHODS

Protoscolicidal substances such as 15% NaCl, 3% NaCl, absolute alcohol, and povidone iodine used in PD and surgery, and 1% NaOCl solution, which was proven in our previous studies (Karaoglanoglu *et al.*, 2004) to be effective on the cystic formations, were used in this study. In the present study, daughter cysts obtained from patients operated on due to liver hydatid cysts were used. The study was performed in 2

Research Article

stages. In the first, the daughter cysts were placed into 6 bottles, with 10 cysts in each. To the first 5 bottles, 20 mL of each protoscolicidal agent was added, and 20 mL of crystal-clear fluid was added to the sixth bottle, which was used as the control group. After the addition of the solutions, a single daughter cyst was removed from the bottles at 5, 10, 15, 20, 40, 60, and 120 min, placed into a 20-mL glass tube, and deflated with an injector needle. The sample that was obtained with a Pasteur pipette from the bottom of the liquid emptied from the daughter cyst was dropped onto a microscope slide and covered with a lamella. The evaluations were performed under light microscopy. In each of the observations, the whole microscope field was scanned. Protoscolices were studied and controlled for signs of viability. The viability was evaluated with respect to the movement of the fire cells in the protoscolices and eosin intake.

If there were not enough protoscolices in the first sample, more samples were prepared. If necessary, the same procedure was continued in order to prepare more samples from the second daughter cyst. When the protoscolices became inactive, 1% eosin stain was dropped from the edge of the slide and diffused. The stained protoscolices were considered as nonviable and the others as viable. When all of the protoscolices were stained, the examination was terminated. The end-time was recorded for the activity and the completion of the staining. If the protoscolices were nonviable during 5 min of examination, the 1-min examinations were performed as well. For the daughter cysts in the crystal-clear fluid sample, however, the evaluation was continued after 2 h, into hours 6, 12, 24, and 36. In the second stage, the direct effects of the protoscolicidal agents on the protoscolices were investigated. Therefore, one of the daughter cysts kept in the crystal-clear fluid was transferred to another tube and deflated there. One of the protoscolicidal agents was added to the tube in the same amount as the crystal-clear fluid. Samples were taken from the mixture at 1, 5, 10, 15, 20, 40, and 60 min for evaluation. The evaluation was continued until all of the protoscolices were inactive and stained. For the periods in which the protoscolices were observed as nonviable, examinations were performed in the previous time intervals. Hence, the period in which the protoscolices in the crystal-clear fluid mixed with each agent were viable was recorded in terms of minutes.

RESULTS AND DISCUSSION

Results

In the first stage of the study, all of the protoscolices in the daughter cysts (Figure 1) of the control group were viable for 24 h. However, all of them were observed to have lost their activity and were stained completely at 32 h. The unprocessed protoscolices in the daughter cysts lost their viability between 24 and 32 h. All of the protoscolices obtained from the daughter cysts in the 15% NaCl and povidone iodine solutions at 5 min became inactive and were stained completely (Figure 2). In the investigation performed at earlier periods, on the other hand, it was observed that the protoscolices obtained from the daughter cysts became inactive and stained at 1 and 2 min in 15% NaCl and povidone iodine, respectively. During the investigation at 5 min, all of the protoscolices obtained from the daughter cysts (20%) in 3% NaCl were observed to be viable and active. At 10 min, 2 of the 10 protoscolices in the sample obtained were active, but none of them were stained. However, all of the protoscolices in the sample obtained at 15 min were inactive, but only 10% of them stained. Meanwhile, the protoscolices were deformed and stained completely at 20 min. At 5 min, 1% NaOCl solution smashed 8 of 10 daughter cysts (80%). The study of the contents of the remaining 2 whole daughter cysts (20%) revealed that the protoscolices were viable. However, all of the protoscolices were deformed in the NaOCl solution with the smashed daughter cysts. The protoscolices in the daughter cysts in the alcohol remained viable up for up to 60 min. The investigation at 65 min, however, indicated that all of the protoscolices were inactive and stained completely. In the second stage of the study, the direct effects of the protoscolicidal substances on the protoscolices were investigated. In the control group, the protoscolices in the daughter cysts, which were placed into another tube and deflated there without the addition of any agents into the tube, became inactive at 30 min and began staining. At 38 min, they were stained completely. In the first examination of the 15% NaCl solution at the first seconds (approximately 1 min), the activities stopped but the

Research Article

protoscolices did not stain. The examination at 5 min showed that all of the protoscolices disintegrated and stained completely. The activity of the protoscolices in 3% NaCl solution lasted for 12 min. The staining began at 13 min and was completed at 20 min. The activities of the protoscolices in Betadine solution halted at 2 min and staining with butadiene began. The process finished at 5 min. Because Betadine functioned as the painting agent, eosin was not necessary at 12 min. The staining began at 13 min and was completed at 20 min. The activity in the protoscolices mixed with 1% NaOCl solution ended immediately. They were deformed and smashed almost instantly. In the alcohol sample, all of the protoscolices were active for 5 min, but the activity started to decrease from 6 min onward. Activity halted completely and the protoscolices were stained at 8 min. To be sure of our results and to investigate the likelihood of any differences among cysts, the study was repeated with the daughter vesicles of cysts obtained from 3 patients at different times. There were slight differences among the duration periods with respect to the effect of protoscolicidal agents on the cysts. However, it did not cause any change in the order of the efficacy of the agents used. It was thought that the difference in the duration could be associated with some factors such as the age, type, size, and membrane thickness of the cyst. In case of any difference among the results, the closest value to the mean was considered.

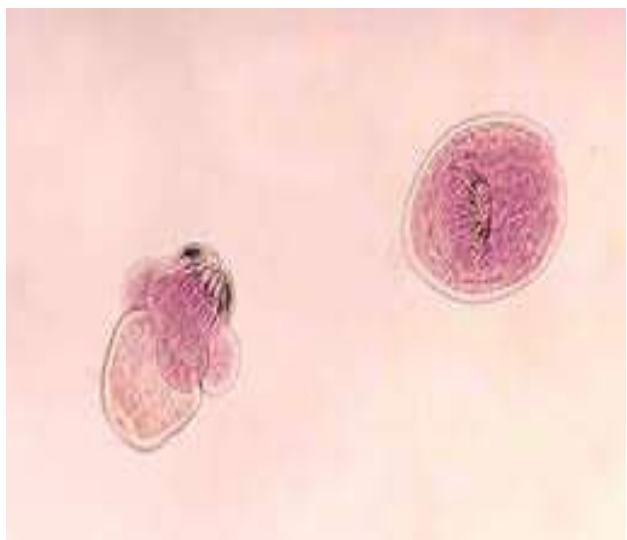


Figure 1: Protoscolices of hydatid cyst, 40X.

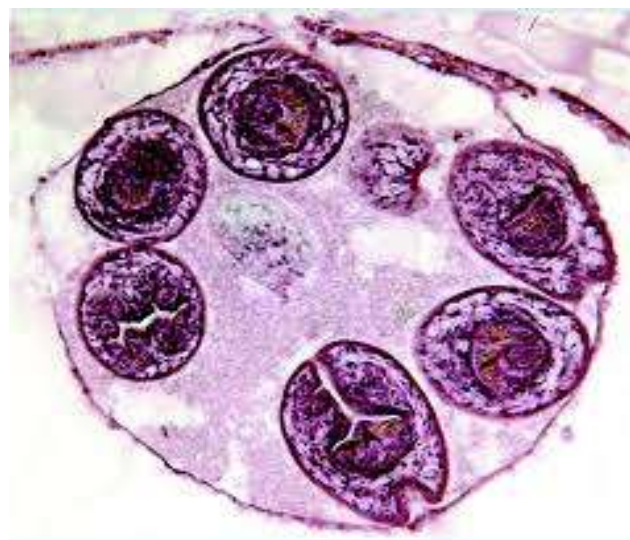


Figure 2: Daughter cyst of hydatid cyst, 40X.

Discussion

Gharbi *et al.*, (1981) ultrasonographically classified the liver hydatid cyst into 5 types (Gharbi *et al.*, 1981). Daughter vesicles are important components of hydatid cysts types 3 and 4. Being smaller examples of the larger cysts, such structures are made up of the germinal layer of the main cyst by sprouting. It is obvious that daughter cysts left intact during PD or surgical treatment may cause recurrence.

Various protoscolicidal substances have been used in both surgery and PD to inactivate the cysts.

They are expected to destroy the protoscolices as early as possible. Their injection into the cyst during surgery kills the protoscolices and prevents further propagation of the viable protoscolices. Therefore, other abdominal organs are wrapped using compresses with povidone iodine or hypertonic saline prior to surgical drainage. Following the drainage, the abdomen is irrigated with the mentioned solutions. It is a common practice to irrigate the cyst cavity with

Betadine or hypertonic saline solutions and to clean it with the tampons (Prabhudessai *et al.*, 2009). It is vital that the daughter vesicles in the main cyst be inactivated. A daughter vesicle escaping into the abdomen or forgotten in the cystic cavity during the surgical drainage may trigger the formation of a new cyst and thus cause a recurrence. A small daughter vesicle contains thousands of viable protoscolices,

Research Article

which may initiate the fertilization of the cyst. In PD applications, as well, the main objective of the treatment in the puncture, aspiration, injection, and respiration (PAIR) method and the catheterization method is the inactivation of all of the protoscolices with protoscolicidal substances. Therefore, diffusion of the used protoscolicidal substance through the membrane of the daughter vesicle to thus affect the protoscolices in the daughter vesicle is of vital importance. As mentioned above, any viable protoscolices left in the daughter cyst may cause the survival of the cyst and result in an ineffective treatment. In this study, the protoscolicidal agents frequently used in surgery and PD, as well as the sodium hypochlorite solution proven effective in our previous study, were used. Hypertonic saline, povidone iodine, and alcohol are known as the most commonly used protoscolicidal agents. One of the most significant results of this study was the finding that alcohol affected the protoscolices in the daughter cyst very late. While alcohol was effective on the protoscolices in the crystal-clear fluid at 6 min, it was at 65 min that it affected them in the daughter cyst. Therefore, despite its use as a proto scolicidal agent in the literature (Ustünsöz *et al.*, 1999; Men *et al.*, 1999; Ormeci *et al.*, 2001), it is thought that alcohol alone would not be an appropriate agent to be used, especially in PD, and would be ineffective, especially on the cysts containing daughter vesicles. As it does not create the desired effect in a short time, its use during surgical drainage is not recommended, either. Another significant result of the study was the observation of the late effect of 3% hypertonic saline solution, which did not affect the protoscolices in crystal-clear fluid until 15 min, a very long duration. Therefore, we are of the opinion that its use in surgery or PD is not recommended. Several other studies have also shown that increasing the concentration of the saline increases its effect, as well (Deger *et al.*, 2000). When the given solution mixed with the crystal-clear fluid becomes diluted, it can be inferred that the low concentration of hypertonic saline would not be suggested for the treatment of hydatid cysts.

In the crystal-clear fluid, 15% NaCl had a fast effect on the protoscolices and diff used through the membrane of the daughter vesicles, causing rapid inactivation of the protoscolices in the vesicle. Hypertonic saline has been found to be highly effective on hydatid cysts in vitro (Adas *et al.*, 2009; Caglar *et al.*, 2008). Therefore, 15% NaCl seems to be a suitable protoscolicidal agent for use in both PD and open surgery. However, experimental studies have reported that hypertonic saline at high concentrations may have toxic effects on bile. Furthermore, it has been reported that it may also cause fatal hyperthermia in clinical use (Bosanac and Lisanin 2000). During PD, the aspiration of hypertonic saline injected into the cystic cavity may decrease its toxic effects, because the hypertonic saline inactivates the protoscolices in the crystal-clear fluid and daughter vesicles in a few minutes. Therefore, it is not necessary to keep it in the cyst cavity for a long period of time. In this study, povidone iodine was determined to be a very effective protoscolicidal agent. Several studies have also reported the same result (Arıbaş *et al.*, 2011). However, it has been reported that it may have some toxic effects on bile (Aygün *et al.*, 2001). NaOCl solutions were observed to be effective protoscolicidal agents. In our previous studies, it was determined that they were effective on the macroscopic structure of the hydatid cyst membrane and daughter vesicles (Karaoğlanoğlu *et al.*, 2004). To our surprise, NaOCl inactivated the protoscolices in the crystal-clear fluid rapidly but did not have any effect on the protoscolices in the non deformed daughter cyst. Most likely, NaOCl did not diff use through the daughter cyst membrane, and, hence, it could not deform the inaccessible protoscolices. Therefore, it was envisaged that this agent may not diffuse through the laminar membrane and pericyst and may not cause any toxic effect in the hosting tissue. It is required that further studies be carried out regarding this issue to investigate the in vivo effects of the solution (Mustafa *et al.*, 2011; Garedaghi, 2013; Garedaghi and Bahavarnia, 2009).

Conclusion

It was determined in this study that 1% NaOCl, 15% hypertonic saline, and povidone iodine solutions were effective protoscolicidal agents against the protoscolices, both in the crystal-clear fluid and the daughter cysts. On the other hand, 3% hypertonic saline was not effective enough as a protoscolicidal agent. Alcohol was ineffective, especially on the protoscolices in the daughter cysts, and, hence, it is believed that alcohol alone is not appropriate for the treatment of type 3 and type 4 hydatid cysts.

Research Article

ACKNOWLEDGMENTS

The authors wish to thanks the Islamic Azad University, Tabriz Branch, Tabriz, Iran for the financial supports, and all laboratory technicians for technical aids in this project.

Competing Interests

Authors have declared that no competing interests exist.

REFERENCES

- Adas G, Arikan S, Kemik O, Oner A, Sahip N and Karatepe O (2009).** Use of albendazole sulfoxide, albendazole sulfone, and combined solutions as scolical agents on hydatid cysts (in vitro study). *World Journal of Gastroenterology* **15** 112-6.
- Akhan O and Özmen MN (1999).** Percutaneous treatment of liver hydatid cysts. *European Journal of Radiology* **32** 76-85.
- Arıbaş BK, Dingil G, Köroğlu M, Üngül Ü and Zaralı AC (2011).** Liver hydatid cyst with transdiaphragmatic rupture and lung hydatid cyst ruptured into bronchi and pleural space. *Cardiovascular and Interventional Radiology* **34**(Suppl. 2) 260-5.
- Aygün E, Sahin M, Odev K, Vatansev C, Aksoy F and Paksoy Y et al., (2001).** The management of liver hydatid cysts by percutaneous drainage. *Canadian Journal of Surgery* **44** 203-9.
- Bosanac ZB and Lisanin L (2000).** Percutaneous drainage of hydatid cyst in the liver as a primary treatment: review of 52 consecutive cases with long-term follow-up. *Clinical Radiology* **55** 839-48.
- Caglar R, Yuzbasioglu MF, Bulbuloglu E, Gul M, Ezberci F and Kale IT (2008).** In vitro effectiveness of different chemical agents on scolices of hydatid cyst. *Journal of Investigative Surgery* **21** 71-5.
- Canyigit M, Gumus M, Cay N, Erol B, Karaoglanoglu M and Akhan O (2011).** Refractory cystobiliary fistula secondary to percutaneous treatment of hydatid cyst: treatment with N-butyl 2 cyanoacrylate embolization. *Cardiovascular and Interventional Radiology* **34**(Suppl. 2) 266-70.
- Deger E, Hokelek M, Deger BA, Tutar E, Asil M and Pakdemirli E (2000).** A new therapeutic approach for the treatment of cystic echinococcosis: percutaneous albendazol sulphoxide injection without reaspiration. *The American Journal of Gastroenterology* **95** 248-54.
- Garedaghi Y and Bahavarnia SR (2011).** Seroepidemiological Study of human Hydatitosis by ELISA Method in East-Azarbaijan Province (2009). *Iranian Journal of Epidemiological* **7**(2) 25-29.
- Garedaghi Yagoob (2013).** Prevalence and fertility of hydatid cyst in slaughtered Farm animals of Tabriz city, Iran. *Life Science Journal* **10**(5s) 190-193. (ISSN:1097-8135).
- Gharbi HA, Hanine W, Brauner MW and Dupuch K (1981).** Ultrasound examination of the hydatid liver. *Radiology* **139** 459-63.
- Karaoğlu M, Akinci ÖF, Bozkurt S, Deniz Ş, Karataş G and Coşkun A et al., (2004).** Evaluating the effect of different pharmacological and chemical agents on the integrity of hydatid cyst membranes. *American Journal of Roentgenology* **183** 465-9.
- Karayalçın K, Besim H, Sonisik M, Erverdi N, Korkmaz A and Aras N (1999).** Effect of hypertonic saline and alcohol on viability of daughter cysts in hepatic hydatid disease. *European Journal of Surgery* **165** 1043-4.
- Men S, Hekimoğlu B, Yücesoy C, Arda IS and Baran I (1999).** Percutaneous treatment of hepatic cysts: an alternative to surgery. *American Journal of Roentgenology* **172** 83-9.
- Mustafa Karaoğlu, Ömer Faruk Akinci and Mustafa Ulukanligil et al., (2011).** Hydatid cyst viability: the effect of scolical agents on the scolex in the daughter cyst. *Turkish Journal of Medical Sciences* **41**(6) 1001-1006.

Research Article

Ormeci N, Soykan I, Bektas A, Sanoğlu M, Palabiyikoğlu M, Hadi Yasa M *et al.*, (2001). A new percutaneous approach of the treatment of hydatid cysts of the liver. *The American Journal of Gastroenterology* **96** 2225-30.

Prabhudessai SC, Patankar RV and Bradoo A (2009). Laparoscopic treatment of renal hydatid cyst. *Journal of Minimal Access Surgery* **5** 20-1.

Ustünsöz B, Akhan O, Kamiloğlu MA, Somuncu I, Uğurel MS and Cetiner S (1999). Percutaneous treatment of hydatid cysts of the liver: long-term results. *American Journal of Roentgenology* **172** 91-6.

Yorganci K and Sayek I (2002). Surgical treatment of hydatid cysts of the liver in the era of percutaneous treatment. *The American Journal of Surgery* **184** 63-9.