

Research Article

INFLUENCE OF CASSIA FISTULA SEEDS EXTRACT ON UTERINE HISTOARCHITECTURE AND BIOCHEMICAL CONSTITUENTS OF OVARIECTOMIZED FEMALE RATS

***Rajesh Yadav¹ and G. C. Jain²**

¹Department of Zoology, Mahatma Gandhi Institute of Applied Sciences, JECRC campus, Opp. EPIP gate, Shri Ram Ki Nangal via Sitapura, Tonk Road, Jaipur (India) -302022

²Reproductive Physiology Laboratory, Centre for Advanced Studies in Zoology, University of Rajasthan, Jaipur (India)

*Author for Correspondence

ABSTRACT

In the present investigation, uterine histoarchitecture and biochemical constituents of immature bilaterally ovariectomized female albino rats treated with aqueous extract of *Cassia fistula* seeds administered in the presence and absence of estradiol valerate (EDV) have been studied. Ovariectomy resulted in the decrease of glycogen and protein content in the uterus. Administration of aqueous extract of *Cassia fistula* seeds alone at the dose 100mg/kg b.wt. increased glycogen, protein and sialic acid contents with increasing uterine wet weights ($p<0.05$) and luminal epithelial cell height ($p<0.001$) but did not induce premature opening of the vagina, whereas, the glycogen, protein and sialic acid contents decreased on conjoint treatments of the extract with EDV (0.1mg/kg b.wt.). This suggests that the extract exhibited a mild estrogenic activity when given alone, but when the extract was administered conjointly with EDV, it significantly ($p<0.001$) prevented the estrogen-induced uterotrophic effect, thus showing an antiestrogenic nature of the extract in the presence of a strong estrogen. Thus, the results of the present study indicate that the extract possesses pregnancy terminating effect by virtue of antiimplantation activity and the antiestrogenic property of the extract may be responsible, at least partly, for this anticonceptive effect.

Key Words: *Cassia Fistula, Glycogen, Sialic Acid, Protein, Cholesterol, Uterus, Female Rats*

INTRODUCTION

Cassia fistula Linn (Hindi-Amaltas; English-Golden Shower or Indian Laburnum), a medium-sized tree belonging to the Family – Caesalpiniaceae, is widely cultivated throughout India as an ornamental plant and is used for its medicinal properties. Different parts of this plant have been used extensively in the folklore medicine for the treatment of a variety of diseases (Chopra *et al.*, 1992 and Barthakur *et al.*, 1995). Pharmacologically, the plant has been investigated for its anti-diabetic (Esposito *et al.*, 1991 and Einstein *et al.*, 2013), hypocholesterolaemic (El-Saadany *et al.*, 1991), antitumour (Gupta *et al.*, 2000), hepatoprotective (Bhakta *et al.*, 2001; Das *et al.*, 2008), antioxidant (Luximon-Ramma *et al.*, 2002), laxative (Akanmu *et al.*, 2004), anti-inflammatory (Raju *et al.*, 2005), antibacterial and Antifungal activity (Duraipandivan and Ignacimuthu (2007), antifertility (Yadav and Jain, 2009), anthelminthic (Moshahid *et al.*, 2010), antimicrobial (Aneja *et al.*, 2011), antifeedant and larvicidal (Duraipandiyan *et al.*, 2011) activity. The plant is rich in phenolic antioxidants such as anthraquinones, flavonoids and flavan-3-ol derivatives (Bahorun *et al.*, 2005).

Although a variety of synthetic contraceptive agents are available, but these cannot be used continuously because of their side effects. In recent years, relatively more emphasis is being laid on the examination of natural products including substances of plant origin for their post-coital antifertility activity. So, natural plant substances possessing mild inherent estrogenic and antiestrogenic properties offer themselves as an effective non-conventional source of contraception with less deleterious side effects. Many of these plant products having inherent estrogenic or antiestrogenic effects possibly bring about alteration in tubal

Research Article

transport of blastocyst or hormonal milieu of the uterus making the uterine environment hostile for implantation or fetal development. Ovarian hormones are also known to alter biochemical constituents of female reproductive tract. Administration of estrogen or progesterone to adult or ovariectomized rats is known to elevate significantly wet weight of uterus, cervix and vagina albeit the estrogen is found to exert more pronounced action (Kholkute and Udupa, 1976 and Pakrashi and Saha, 1977). On the basis of this inherent virtue, the estrogenic and antiestrogenic nature of many contraceptive agents has been assessed. In our earlier communication (Yadav and Jain, 1999), it has been reported that post-coital administration of aqueous extract of seeds of *Cassia fistula* at the dose 500mg/kg b.wt./day prevented cent percent implantation in female rats by virtue of anti-implantational property along with antiestrogenic activity. In the view of its remarkable antiimplantation and antiestrogenic activity the present study attempts to analyze the possible modulatory influence of aqueous extract of *C. fistula* seeds on the histological and biochemical constituents of uterus of ovariectomized female rats which may play an important role in implantation and fetal development.

MATERIALS AND METHODS

Plant Collection and Extraction

Pods of *Cassia fistula* “Amaltas” were collected during the season and were thoroughly dried in the shade. The plant was authenticated at the Department of Botany, University of Rajasthan, Jaipur (India). The seeds separated from the shade dried pods were ground to coarse powder. The powdered seeds (500g) were extracted with distilled water in a Soxhlet apparatus for 36 hrs at 100°C. The crude extract (32g) so obtained was concentrated under reduced pressure and low temperature. The residue thus, obtained was then utilized for evaluating the estrogenic/antiestrogenic activity by suspending in appropriate volume of olive oil.

Animal Stock

Colony bred bilaterally ovariectomized immature female rats (21-24 days old) were used as an experimental animal model for bioassay studies. All the animals were housed in standard laboratory conditions (temperature 22 ±3°C and 14hr light/10hr dark cycle) with free access of food (Lipton India Ltd) and tap water *ad libitum*. All the experimental procedures were performed according to the guidelines for the care and use of experimental animals and approved by the Institutional Ethical Committee for Animals Care and Use, University of Rajasthan, Jaipur (India).

Estrogenic / Antiestrogenic Activity

Estrogenic or antiestrogenic activity of the extract was assessed by uterine wet weight, vaginal cornification and premature vaginal opening in sexually immature bilaterally ovariectomized female rats. Crude aqueous extract of the test substance was subjected to standard bioassay procedures for assessment of estrogenic or antiestrogenic activity in terms of the rat uterotrophic assay (Dorfman and Kincl, 1966, WHO protocol). Colony-bred immature female albino rats (21-24 days old) were bilaterally ovariectomized by dorsolateral approach, under light ether anaesthesia and semisterile conditions. After a rest period of seven days, these were randomly divided into four groups of seven animals each and treated as follows:

Group I: Control group, receiving olive oil only (0.2ml/rat/day), orally.

Group II: Estradiol valerate (EDV, 0.1 mg/kg b.wt./day), intramuscularly (i.m.).

Group III: Extract alone (100 mg/kg b.wt./day), orally.

Group IV: Extract (100 mg/kg b.wt./day, orally) + EDV (0.1 mg/kg b.wt./day, i.m.), conjointly.

The extract was administered orally by using a curved needle and a tuberculin syringe. All these rats received treatment twice daily for 3 consecutive days. These treated rats were sacrificed 24 hours after the last dose administration. Their body weights were recorded. Uteri were carefully dissected out, freed from adherent tissues, blotted on filter paper and were weighed quickly to nearest milligrams on digital pan-balance. Condition of vaginal opening was also recorded. A part of the uterine horns were fixed in

Research Article

Bouin's fixative for histological/histometrical evaluations and the remaining halves of the uterine horns were frozen for tissue biochemical analysis.

Histometric Analysis

Haematoxylin- eosin stained slides were observed microscopically for luminal epithelial cell height. One hundred luminal epithelial cells from 25 sections were measured randomly with an ocular micrometer at x400. Two diagonal and one medial length were measured, averaged and expressed as mean epithelial cell height and were then calibrated with a stage micrometer.

Biochemical Estimation

The following biochemical parameters were assessed in the frozen uterine tissue samples of bilaterally ovariectomized immature rats for bioassay studies: Protein (Lowry *et al.*, 1951); Cholesterol (Oser, 1965); Glycogen (Montgomery, 1957) and Sialic acid (Warren, 1959).

Statistical Analysis

All the values are expressed as the mean \pm SEM and significance was analyzed statistically by Students 't' test and $p < 0.05$ was considered as statistically significant.

RESULTS AND DISCUSSION

Uterine Weight and Vaginal Opening

The results of uterine bioassay test carried out in bilaterally ovariectomized immature female rats are summarized in Table 1. Oral administration of the extract (100mg/kg b.wt./twice daily) to ovariectomized immature female rats produced a slightly significant ($p < 0.05$) increase in the uterine wet weight. However, the extract did not induce premature opening of the vagina, thus, suggesting a mild estrogenic activity of the extract. But, when the extract was administered conjointly with estradiol valerate (EDV, 0.1mg/kg b.wt./twice daily), it significantly ($p < 0.001$) prevented the estrogen-induced uterotrophic effect, thus, reflecting antiestrogenic nature of the extract in the presence of a strong estrogen.

Table 1: Showing changes in the wet uterine weight, vaginal opening and Luminal epithelial cell height of bilaterally ovariectomized immature female rats after treatment with Estradiol Valerate and / or aqueous extract of *Cassia fistula* seeds

Group	Treatment group	Treatment dose of extract (Mg/kg b. wt.)	Estradiol valerate (0.1mg/kg b. wt.)	Uterine weight (mg/100 gm b. wt.)	vaginal opening	Luminal epithelial cell height (μ m)
1	Control	Olive Oil	-	38.36 \pm 1.63	Close	10.45 \pm 0.32
2	Estradiol Valerate (EDV)	-	0.1	529.36 \pm 23.91 ^{aaa}	open	42.50 \pm 0.29 ^{aaa}
3	Aqueous extract	100	-	44.73 \pm 1.21*	close	16.45 \pm 0.31 ^{***}
4	Aqueous EDV	+ 100	0.1	329.20 \pm 15.48 ^{###}	open	37.32 \pm 0.20 ^{###}

(Tabular values represent the mean \pm SEM of 5 animals)

1. ^a Estradiol treated rats (group 2) were compared with controls of group 1.
^{aaa} $p < 0.001$ (Highly significant)
2. * Extract treated groups were compared with controls of group 1.
^{*} $p < 0.05$ (slightly significant) ^{***} $p < 0.001$ (Highly significant)
3. # (Extract + Estradiol valerate both) treated groups were compared with controls of group 2
^{###} $p < 0.001$ (Highly significant)

Research Article

Following surgery, in the ovariectomized controls which lack estrogens, the uterine weight was reduced. Treatment of estradiol valerate (EDV) to these ovariectomized immature female rats induced a significant increase in uterine weight and accelerated premature vaginal opening in all these animals confirming well known sensitive bioassays of estrogenicity (Jordan *et al.*, 1985, Clark & Markaverich, 1988). Estradiol valerate treatment to ovariectomized rat produced significant hypertrophy and hyperaemia of the uterine tissue and accumulation of uterine luminal fluid which may cause increase in uterine weight. Furthermore, the gain in uterine weight may be due to biosynthesis of RNA and protein actively (Turner and Bagnara, 1976).

The results obtained during this study were in accordance with several earlier reports describing estrogenic and/or antiestrogenic properties of a number of contraceptive plant preparations in uterine bioassay test (Sharma *et al.*, 1976; Chandhoke & Gupta, 1978; Jacob *et al.*, 1986, 1988; Dhar *et al.*, 1992, Sisodia & Prakash, 1994; Sarita & Bhagya, 2012).

Thus, the hormonal profile (estrogenic / antiestrogenic) of the test plant substance, like other such agents support the conjecture that estrogenic / antiestrogenic substances act as pregnancy interceptory agents.

Uterine Histoarchitecture

The mammalian uterus appears to be an ideal organ for measuring estrogenicity of a substance as after estrogen administration; the atrophic uterus of the ovariectomized rat is rapidly converted into a growing structure (Muller *et al.*, 1958).

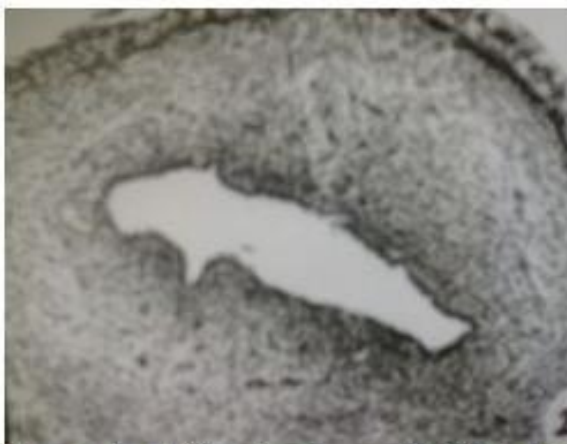


Figure 1: T.S. of uterus of bilaterally ovariectomized control rats showing infantile appearance with reduced luminal epithelial cell height, compact stroma and atrophic endometrium.




Figure 2: T.S. of uterus of bilaterally ovariectomized rats treated with EDV alone, illustrating the hypertrophy of the endometrial epithelium, uterine lumen lined with tall columnar epithelial cells and few enlarged uterine glands lined with columnar cells in the loose edematous stroma.

The extract when administered alone to ovariectomized rats induced a mild stimulation of all the uterine constituent elements and a highly significant ($p < 0.001$) increase in uterine luminal epithelial cell height when compared with ovariectomized controls only, thus, showing the estrogenic nature. But when the extract was administered conjointly with EDV, it showed antagonism of EDV-induced hypertrophy of the uterine constituent elements and a highly significant ($p < 0.001$) decline in uterine luminal epithelial cell height in comparison to EDV alone treated rats (Group II). In the present study, the uterine histoarchitecture of ovariectomized control rats showed an infantile appearance, compact stroma with

Research Article

atrophic endometrium and few, small, inactive uterine glands. The lumen was narrow and lined with cuboidal epithelial cells (Figure 1). Thus, confirmed well known estrogen deprivation effect (Sud and Setty, 1974). However, treatment with estradiol valerate (EDV) to ovariectomized rats resulted in hypertrophy and hyperplasia of the endometrial epithelium. The uterine lumen became enlarged and lined with tall columnar epithelial cell. Enlarged uterine glands were also present in loose and edematous stroma (Figure 2). These results were in accordance with the well known effect of estrogens on the uterus of ovariectomized animals (Ljungkvist, 1971 and Weitlauf, 1988).

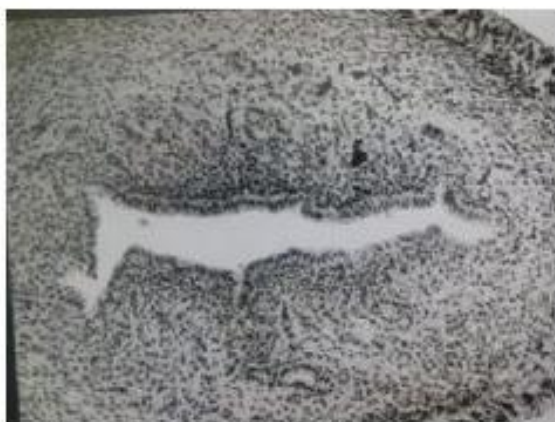

Figure 3: T.S. of uterus of bilaterally ovariectomized rats treated with aqueous extract of *cassia fistula* seeds illustrating the mild stimulation of all the constituent elements.

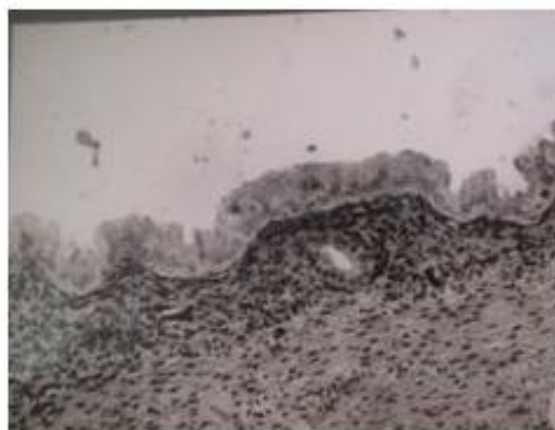


Figure 4: T.S. of uterus of bilaterally ovariectomized rats treated with aqueous extract of *cassia fistula* seeds along with EDV, displaying antagonism of EDV induced hypertrophy of the uterine constituents.

Administration of aqueous extract of *Cassia fistula* seeds alone to ovariectomized rats, in general, resulted in slight increase in the size of uterine lumen, number of uterine glands and the luminal epithelial cell height (Figure 3). Whereas administration of the extract conjointly with EDV to ovariectomized rats prevented EDV induced hypertrophy of the uterine constituents i.e. It produced a reduction in the size of uterine lumen, number of uterine glands and the luminal epithelial cell height (Figure 4), thus, suggesting antiestrogenic nature of the extract. There are many reports which highlight similar antiestrogenic effect on uterine histology of ovariectomized female rats after administration of various plant extracts (Pakrashi and Chakraborty, 1978; Chandhoke and Gupta, 1978 and Shukla *et al.*, 1988).

Thus, besides uterine wet weight bioassay, uterine histoarchitecture of ovariectomized immature rats receiving extract alone or in combination with estradiol valerate also supported estrogenic and / or antiestrogenic property of the extract tested during this study.

Biochemical Estimation

The values of the uterine biochemical parameters of the bilaterally ovariectomized immature female rats treated with aqueous extracts of seeds of *Cassia fistula* alone and/or in combination of estradiol valerate (EDV) are summarized in Table 2. Proteins are considered to be the building material and are involved in the alteration of almost every physiological function. In the reproductive system, the total protein contents run parallel to the growth of the reproductive organs and are estrogen sensitive (Telfer, 1953 and Davis *et al.*, 1956). Biochemical studies on the uterus and other tissues responsive to estrogen indicate that steroid stimulates the synthesis of mRNA, proteins and DNA (Turner and Bagnara, 1976).

Research Article

Table 2: Showing Biochemical Changes in the Uterus of Bilaterally Ovariectomized Immature Female Rats after Treatment of Aqueous Extract of *Cassia Fistula* Seeds Alone/Conjointly With Edv

Group	Treatment group	Protein (mg/kg)	Sialic acid (mg/kg)	Glycogen (mg/kg)	cholesterol (mg/kg)
1	Control	130±13.54	3.15±0.16	2.85±0.10	6.24±0.19
2	Estradiol Valerate (EDV)	240±23.11 ^{aa}	4.32±0.17 ^{aaa}	4.61±0.21 ^{aaa}	7.49±0.25 ^{aa}
3	Aqueous extract	146.6±3.03*	3.39±0.21 ^{NS}	3.26±0.19 ^{NS}	6.50±0.16 ^{NS}
4	Aqueous + EDV	214.2±3.87 [#]	4.01±0.18 ^{ns}	4.23±0.18 ^{ns}	7.38±0.12 ^{ns}

(Tabular values represent the mean ± SEM of 5 animals)

1. ^a Estradiol treated rats (group 2) were compared with controls of group 1.
^{aa}p<0.01 (Significant), ^{aaa}p<0.001 (Highly significant)
2. ^{*}Extract treated groups were compared with controls of group 1.
^{NS} = Non-Significant, ^{*}p<0.05 (slightly significant)
3. [#] (Extract + Estradiol valerate both) treated groups were compared with controls of group 2
^{ns} = Non-significant, [#]p < 0.05 (Slightly significant)

Uterine protein content usually increases during the preimplantation period in most mammalian species. High protein concentration is caused by a decrease in water content and increased viscosity due to influence of progesterone. The proteins in luminal uterine secretions are derived from blood plasma proteins and from endometrial secretory products (Beier *et al.*, 1991). In the present study, the protein content in uterus of bilaterally ovariectomized immature control rats was very low. Following EDV treatment, a significant increase (p<0.01) in protein content was noticed. A slight significant increase (p<0.05) in uterine protein content was also noticed after treatment with extracts alone in ovariectomized immature rats. However, treatment of the extract conjointly with EDV to ovariectomized rats depicted a slightly significant decrease (p<0.05) in the uterine protein content when compared with EDV alone treated rats. Thus, showing the estrogenic nature of the test substance when given alone to ovariectomized rats but in presence of a strong estrogen the extract showed the antiestrogenic property. The above results are in agreement with many earlier reports (Dixit, 1977; Seshadri *et al.*, 1979; Wadhwa, 1982; Shukla *et al.*, 1987 and Ahirwar *et al.*, 2007).

Sialic acid has a vital role in embryo implantation in the uterus by acting as an immuno-barrier between mother and embryo (Pant and Raman, 1983). It has been suggested that the uterine sialic acid concentration is directly proportional to estrogen and inversely proportional to progesterone concentration (Coppola and Ball, 1966). An increase in the uterine sialic acid is associated with the estrogen treatment in immature and mature rats (Dugan *et al.*, 1968) and also in ovariectomized rats (Galleti and Gardi, 1973). The observation in the present study revealed that the level of sialic acid in uterus of ovariectomized immature rats was comparatively low. Administration of estradiol valerate to ovariectomized rats raised the level of sialic acid significantly (p<0.001). Administration of the extract alone produced a non-significant increase in the uterine sialic acid levels. But, when the extract was given in combination with EDV to the spayed female rats, a non-significant decreases in sialic acid was observed as compared to EDV alone treated spayed rats, suggesting mild antiestrogenic nature of the extract in presence of a strong estrogen. Thus, review of literature reveals that the increase or decrease in sialic acid concentration of uterus may be due to inherent hormonal property of the test substances. The change in uterine sialic acid content may result in change of uterine milieu, making it unsuitable for implantation (Lal, 1976; Wadhwa, 1982 and Ghosh, 1994). Glycogen is a polysaccharide, present in uterine tissues which provide energy for various metabolic processes. The metabolism and the mobilization of glycogen in the female reproductive organ is controlled and regulated by the ovarian

Research Article

hormones where estrogen plays an important role. In general, the exogenous estrogen increases the glycogen contents of the mammalian uterus (Hibbard and Harriet, 1966 and Bo *et al.*, 1967). In the present study, administration of EDV to ovariectomized rats also caused a highly significant increase ($p < 0.001$) in uterine glycogen concentration. Whereas, treatment of the extract alone to ovariectomized rats induced a non-significant increase in the uterine glycogen content as compared to the ovariectomized controls. Conjoint administration of the extract with EDV to ovariectomized rats in general produced a non-significant decrease in the uterine glycogen concentration as compared to the ovariectomized EDV treated controls. These results are in agreement with those of earlier findings (Wadhwa, 1982; Sharma, 1993 and Prakash and Pathak, 1994). The importance of cholesterol as a precursor molecule in the synthesis of steroid hormones is well known. Cholesterol derived from different sources is the precursor for the steroidogenesis of ovarian endocrine tissue (Strauss *et al.*, 1981). Emmelot and Bosch (1954) have reported an increase in the cholesterol content of the rat uterus after estrogen administration. In contrast to this, Leatham (1959) did not observe any change in the uterine cholesterol after estradiol dipropionate treatment. The results of the present study in general demonstrated a non-significant change in uterine cholesterol concentration in ovariectomized female rats after administration of the extract alone and conjointly with EDV, indicating no adverse effect on uterine cholesterol metabolism. It has been observed that the plant products having estrogenic nature appear to elevate and that of antiestrogenic nature tend to reduce the cholesterol level in the uterus of intact and ovariectomized rats (Wadhwa, 1982).

In our earlier communication (Yadav and Jain, 1999) it has been reported that postcoital administration of aqueous extract of *Cassia fistula* seeds at the dose 500mg/kg b.wt./day from day 1-5pc resulted in cent percent anti-implantational activity. In the present investigation, the crude aqueous extract of *Cassia fistula* seeds in ovariectomized female rats showed mild estrogenicity when administered alone but when given conjointly with estradiol valerate it produced estrogen antagonistic effects. Thus, like other relatively weak estrogenic substances it behaved as an antiestrogen in the presence of relatively more potent estrogen by possibly affecting the uterine estrogen receptor binding. A number of plants possessing antiestrogenic activity have also been reported to interrupt pregnancy (Dao *et al.*, 1996; Badami *et al.*, 2003; Sharma *et al.*, 2005; Ravichandran *et al.*, 2007). Antiestrogens with weak estrogenic activity administered early in pregnancy may interfere with implantation by altering the normal pattern of hormonal conditioning of uterus required for conception (Psychoyos and Prepas, 1987).

On the basis of the above observations it may be concluded that aqueous extract of seeds of *Cassia fistula* owing to its antiestrogenic nature alters the biochemical milieu of the reproductive tract especially uterine environment (Rao *et al.*, 2005) which lead to change the normal status of reproduction in female reproductive tract of rat and thus produce significant antifertility effect. Although it would be premature to correlate the changes in the uterine biochemical constituents and the antinidational effect of the extract but the changes in the activity of the uterine biochemical milieu could conjecturally be playing a role in the prevention of pregnancy. The antiestrogenic efficacy of the aqueous extract of *Cassia fistula* seeds in presence of a strong estrogen produced inhibitory effect which merely supports the contention that aqueous extract of *Cassia fistula* seeds offer itself as a very promising substance for further research in pregnancy interception.

ACKNOWLEDGEMENT

The authors are thankful to the Head of Department and Coordinator, Centre for Advanced Studies in Zoology for providing necessary laboratory facilities and also the University of Rajasthan for financial support to Ms Rajesh Yadav.

REFERENCES

Ahirwar D, Ahirwar B and Kharya MD (2007). Influence of *Calotropis procera* roots on biochemistry of reproductive organs of ovariectomized rats. *Indian Journal of Pharmaceutical Sciences* 69(3) 459-461.

Research Article

- Akanmu MA, Iwalewa EO, Elujoba AA and Adelusola KA (2004).** Toxicity potentials of *Cassia fistula* fruits as laxative with reference to Senna. *African Journal of Biomedical Research* **7**(1) 23-26.
- Aneja KR, Sharma C and Joshi R (2011).** *In vitro* efficacy of amaltas (*Cassia fistula* L.) against the pathogens causing otitis externa. *JJM* **4**(3) 175-183.
- Badami S, Aneesh R, Sankar S, Sathishkumar MN, Suresh B and Rajan S (2003).** Antifertility activity of *Derris brevipes* variety coriacea. *Journal of Ethnopharmacology* **84**(1) 99-104.
- Bahorun T, Neerghen VS and Aruoma OI (2005).** Phytochemical constituents of *Cassia fistula*. *African Journal of Biotechnology* **4** 1530-1540.
- Barthakur NN, Arnold NP and Alli I (1995).** The Indian laburnum (*Cassia fistula* L.) fruit: an analysis of its chemical constituents. *Plants Food Human Nutrition* **47** 55-62.
- Beier HM, Elger W, Hartung CH, Mootz IJ and Hellwig KB (1991).** Dissociation of corpus luteum, endometrium and blastocyst in human implantation research. *J Reprod Fert* **92** 511-523.
- Bhakta T, Banerjee S and Subhash C (2001).** Hepatoprotective activity of *Cassia fistula* leaf extract. *Phytomedicine* **8** (3) 220-224.
- Bo WJ, Maraspin CE and Smith MS (1967).** Glycogen synthetase activity in the rat uterus. *J Endocrinol*, **38** 33-37
- Chandhoke, N and Gupta S (1978).** Estrogenic activity of DQ₁-A steroidal lactone - Isolated from *Datura quercifolia*. *Indian J Exp Biol*, **16** 648-652.
- Chopra RN, Nayar SL and Chopra IC (1992).** Glossary of Indian medicinal plants, Publication and information Directorate, CSIR, New Delhi. p 54.
- Clark JH and Markaverich BM (1988).** Action of ovarian steroid hormones. In *The Physiology of Reproduction Vol. I*, eds. E Knobil and J Neill, *et al* Raven Press, New York, Chapter **17** 675-724.
- Coppola JA and Ball JL (1966).** Uterine sialic acid in relation to ovarian steroids. *Steroids* **8** : 345-352.
- Dao B, Vanage G, Marshall A, Bardin CW and Koide SS (1996).** Antiimplantation activity of antiestrogens and mifepristone. *Contraception* **54** 253-258.
- Das S, Sharma G and Barman S (2008).** Hepatoprotective activity of aqueous extract of fruit Pulp of *Cassia fistula* (AFCF) against carbon tetrachloride (CCL₄) induced liver damage in albino rats. *J Clin Diag. Res* **2** 1133-1138.
- Davis JS, Meyer RK and Meshan WH (1956).** The effects of aminoprotein and estrogen on the phosphate metabolism of rat uterus. *Endocrinology*, **59** 505-515.
- Dhar JD, Setty BS, Lakshmi V and Bhakuni DS (1992).** Postcoital antifertility activity of the marine plant *Achrostichum aureum* L in rat. *Indian J Med Res*, **96**(B) 150-152.
- Dixit VP (1977).** Effect of chronically administered *Malva viscus conzattii* flower extract on the female genital tracts of Gerbil (*Meriones hurrianae jerdon*). *Indian J Exp Biol*, **15** 650-652.
- Dorfman RI and Kincl FA (1966).** Uterotrophic activity of various phenolic steroids. *Acta Endocr* (Kobenhavn) **52**:619.
- Dugan FA, Radhakrishnamurthy B, Rudman RA and Berenson GS (1968).** Stimulation of synthesis of glycoprotein enzyme in the rat uterus by estradiol. *J Endocrinol*, **42** 261-226.
- Duraipandivan V and Ignacimuthu S (2007).** Antibacterial and antifungal activity of *Cassia fistula* L. : An ethnomedicinal plant. *Journal of Ethnopharmacology*, **112**, 590-594.
- Duraipandiyar V, Ignacimuthu S, and Gabriel Paulraj M (2011).** Antifeedant and larvicidal activities of Rhein isolated from the flowers of *Cassia fistula* L. *Saudi Journal of Biological Sciences* **18** 129– 133.
- Einstein JW, Rais MM and Mohd MA (2013).** Comparative evaluation of the antidiabetic effects of different parts of *Cassia fistula* Linn, a Southeast Asian plant. *Journal of Chemistry* volume2013,ArticleID 714063,10pages.
- El-Saadany SS, el-Massry RA, Labib SM and Sitohy MZ (1991).** The biochemical role and hypocholesterolaemic potential of the legume *Cassia fistula* in hypercholesterolaemic rats. *Nahrung* **35** 807-815.

Research Article

- Emmelot P and Bosch L (1954).** The influence of oestrogen on the protein and lipid metabolism of mouse uterus studied with acetate I-C 14. *Res Trav Chim*, **73** 874-877.
- Esposito Avella M, Diaz A, deGracia I, de Tello R, and Gupta MP (1991).** Evaluation of traditional medicine: effects of *Cajanus cajan* L and of *Cassia fistula* L on carbohydrate metabolism in mice. *Rev Med Panama* **16** 39-45.
- Galleti F and Gardi R (1973).** Effect of Ovarian hormones and synthetic progestins on vaginal sialic acid in rat. *J Endocrinol*, **57** 193-198.
- Ghosh P (1994).** Pregnancy interceptor evaluation of certain substances of plant origin in the mouse. Ph. D. Thesis, University of Rajasthan, Jaipur.
- Gupta M, Mazumder UK, Rath N and Mukhopadhyay DK (2000).** Antitumour activity of methanolic extract of *Cassia fistula* L seeds against Ehrlich ascites carcinoma. *J Ethnopharmacology* **72** 151-156.
- Hibbard EW and Harriet TP (1966).** Effects of estradiol on glycogen synthetase in the rat uterus. *Endocrinology*, **78** 786-790.
- Jacob D, Dhir RN, Vyas DK and Bhatt S (1988).** The possible mode of pregnancy interceptory action of *Carica papaya* seeds extract in the rat. *The Indian Zoologist*, **12** 99-102.
- Jacob D, Sharma S and Vyas DK (1986).** Estrogenic and Postcoital antifertility effect of *Carica papaya* seed extract in the rat. *The Indian Zoologist*, **10** 127-129.
- Jordan VC, Mittal S, Gosden B, Koch R and Liberman ME (1985).** Structure- activity relationship of estrogen. *Enviro. Health Perspect*, **61** 97-110.
- Kholkute SD and Udupa KN (1976).** Antiestrogenic activity of *Hibiscus rosa sinensis* Linn flowers. *Indian J Exp Biol*, **14** 175-176.
- Lal G (1976).** Evaluation of postcoital antifertility substances and their effects on histochemistry and biochemistry of the rabbits. Ph.D. Thesis, Univeristy of Rajasthan, Jaipur.
- Leathem JH (1959).** Some biochemical aspects of the uterus. *Ann NY Acad Sci*, **75** 463-471.
- Ljungkvist L (1971).** Attachment reaction of rat uterine luminal epithelium- The effect of estradiol, estrone and oestriol on the morphology of the luminal epithelium of spayed virgin rats. *Acta Society of medicines*, Uppsala, **76** 139-157.
- Lowry OH, Rosenbrough MJ, Farr AL and Randall RJ (1951).** Protein measurement with folin-phenol reagent. *J Biol Chem*, **193** 265-275.
- Luximon- Ramma A, Behorun T, Soobrattee MA and Aruoma OI (2002).** Antioxidant activities of phenolic, proanthocyanidins and flavonoid components in extracts of *Cassia fistula*. *J Agric Food Chem* **50** 5042-5047.
- Montgomery R (1957).** Determination of glycogen. *Arch Biochem Biophys*, **67** 378-381.
- Moshahid AR, Irshad M and Singh M (2010).** Assessment of anthelmintic activity of *Cassia fistula* L. *Middle-East Journal of Scientific Research*, **5(5)** 346-349.
- Muller GC, Ailene MH and Kristian FJ (1958).** Studies on the mechanism of action of oestrogens. *Recent prog Horm Res*, **14** 95-139.
- Oser BL (1965)** In Hawk's "Physiological Chemistry", ed. Oser, B.L. (McGraw Hill, New Delhi), P. 246.
- Pakrashi A and Chakraborti B (1978).** Antiestrogenic and antimplantation effect of aristolic acid form *Aristolochia indica* (Linn). *Indian J Exp Biol*, **16** 1283-1285.
- Pakrashi A and Saha C (1977).** Antimplantation and antioestrogenic activity of a sesquiterpene from roots of *Aristolochia Indica* Linn. *Indian J Exp Biol*, **15** 1197-1198.
- Pant M and Raman L (1983).** Plasmic sialic acid during normal and abnormal pregnancies. *Indian J Med Res*, **76** 361-364.
- Prakash AO and Pathak S (1994).** Uterotrophic response at a single administration of hexane fraction of *Ferula jaeschkaena* in rats. Abstract, in National Symposium on Reproductive Health Care, Jaipur (India) 50.

Research Article

- Psychoyos A and Prepas I (1987).** Inhibition of egg development and implantation in rats after post-coital administration of the progesterone antagonist RU 486. *J reprod fertil.* **80** 487-491.
- Raju I, Moni M and Subramanian V (2005).** Anti-Inflammatory and Antioxidant activities of *Cassia fistula* Linn Bark Extracts. *Afr J Trad CAM* **2** (1) 70 – 85.
- Rao MV, Sunder RS and Chawla SL (2005).** Reproductive toxicity of a fungicide combination (Metalaxyl + Mancozeb) in adult rats. *J Cell Tissue Res* **5** 299-302.
- Ravichandran V, Suresh B, Satishkumar MN, Elango K and Srinivasan R (2007).** Antifertility activity of hydroalcoholic extract of *Ailanthus excelsa* (Roxb): An ethnomedicine used by tribals of Nilgiris region in Tamilnadu. *Ethnopharmacology*, **112** 189-191.
- Sarita M and Bhagya M (2012).** Antiimplantation and anti-estrogenic activity of *Eugenia jambolana* lam Seed. *Journal of Pharmacy Research*, **5**(5) 2607-2609.
- Seshadri C, Suganthan D and Santakumari G (1979).** Biochemical Changes in the uterus and cervix of ovariectomized rats treated with Embelin. *Indian J Exp Biol*, **17** 1389- 1390.
- Sharma MP (1993).** Some plant products as contraceptives in the female albino rats. Ph.D., Thesis, University of Rajasthan, Jaipur.
- Sharma JD and Bhinda A (2005).** Antifertility activity of steroidal extract of *Trigonella foenum graecum* (seeds) in female rats. *Asian J Exp Sci* **19**(1) 115-120.
- Sharma MM, Lal G and Jacob D (1976).** Estrogenic and pregnancy interceptory effects of *Daucus carota* Seeds. *Indian J Exp Biol*, **14** 506- 508.
- Shukla S, Mathur R and Prakash AO (1988).** Antifertility profile of aqueous extract of *Moringa oleifera* roots. *J Ethnopharmacol.* **22**:51-62.
- Shukla S, Mathur R and Prakash AO (1987).** Physiology and biochemistry of female genital tract of ovariectomized rats treated with butanolic extract of *Pueraria tuberosa*. *J Ethnopharmacol* **58** : 9-22.
- Sisodia B and Prakash AO (1994).** Anitfertility profile of *Zingiber roseum* in rats. Abstract, in National Symposium on Reproductive health Care, Jaipur , India, 46.
- Strauss JF III, Schuler LA and Tanaka T (1981).** Cholesterol metabolism by ovarian tissue. *Advances in Lipid Research* **18**: 99.
- Sud NK and Setty BS (1974) :** Histochemical evaluation of estrogenic and antiestrogenic properties of some non-steroidal postcoital antifertility agents. *Indian J Med Research* **62** 1437 -1442.
- Telfer, M.A. (1953):** Influence of estradiol on nucleic acids, respiratory enzymes and the distribution of nitrogen in the rat uterus. *Arch Biochem*, **44** 111-119.
- Turner CD and Bagnara JT (1976):** General Endocrinology , W.B. Saunder Company, Philadelphia - London, 225- 257
- Wadhwa M (1982) :** Contraceptive effects of phytosteroids in female albino rats. Ph.D. Thesis, University of Rajasthan, Jaipur.
- Warren L (1959):** The thiobarbituric acid assay of sialic acids. *Journal of Biological Chemistry* **234** 1971- 1975.
- Weitlauf HM (1988) :** Biology of implantation: In " The Physiology of Reproduction" ed. E. Knobil and J. Neil *et al.* Revan Press, Ltd., New York. 231- 254.
- Yadav R and Jain GC (1999).** Antifertility effect of aqueous extract of seeds of *Cassia fistula* in female rats. *Advances in Contraception* **15** 292-301.
- Yadav R and Jain GC (2009).** Antifertility effect and hormonal profile of petroleum ether extract of seeds of *Cassia fistula* in female rats. *International Journal of PharmTech Research* **1**(3) 438-444.