

EFFECT OF AN OINTMENT MADE FROM SHEA BUTTER AND EXTRACTS FROM *TERMINALIA MANTALY* H. Perrier BARK

*Ouattara Sitapha¹, Bagre Issa¹, Kra Adou Koffi Mathieu¹, Ouattara Watan-Tee Cheick Ismaël Kader¹, Yapo Adou Francis¹, Yapi Ahoua¹, Djaman Allico Joseph^{1,2}

¹Biology and Health Laboratory, Felix Houphouët-Boigny University, Cocody, Abidjan, Ivory Coast, 22 BP 582 Abidjan 22

²Medical and fundamental Biochemistry, Pasteur Institute/Company, Cocody, Abidjan, Ivory Coast, 01 BP 490 Abidjan 01

*Author for Correspondence: sitaphao@yahoo.fr

ABSTRACT

The skin affections appear as a source of ill-being because they put at evil the self-image. This study aimed to formulate an antifungal ointment based on a medicinal plant which is the *Terminalia mantaly* in order to fight against skin diseases such as ringworm, scabs and pimples caused by fungi.

During the work, we proceeded to the hydroalcoholic extraction 70% of the stem barks of from *Terminalia mantaly* which added to the Shea butter allowed to obtain a stable and homogeneous ointment.

Then the formulated ointment was tested on 27 individuals suffering from skin diseases of fungal origin (ringworm, scabs and pimples). In view of the quite satisfactory results, we deduce that the ointment presents a good antifungal activity.

The accessibility of the plant, the lower cost of the excipient (shea butter) and with a proven effectiveness are encouraging characteristics for the development of a traditional medicine.

Keywords: *Terminalia mantaly*, Shea butter, Skin, Antifungal

INTRODUCTION

Man has always relied on plants to ensure his survival and maintain a good appearance. This explains why traditional medicine remains very widespread in developing countries, and its use is also constantly increasing in industrialized countries despite the constant evolution of modern medicine, drug prescriptions, surgery or other forms of therapy in constant evolution (Orsot *et al.*, 2021).

But according to the Who (2013) worldwide, and even in industrialized regions, more than 50% of the population had recourse, at least once, to complementary medicine. In Ivory Coast, according to recent studies, over 80% of the population prefer herbal recipes for their healthcare (Traoré, 2013). Herbal medicines are widely used throughout the world in therapeutic management. And recognition of their pharmacological, clinical, pharmaceutical and economic value continues to grow, although this varies greatly from country to country (Hancock, 2007; Bourdy *et al.*, 2011; Guessennnd, 2013). Indeed, the richness of Africa's flora and fauna is a real asset. Hence the interest of ethnopharmacology, which brings together the ancestral knowledge of traditional medicines and current scientific knowledge. It allows us to obtain a traditional medicine that has been modified to improve its presentation, taste, packaging and methods of use, while maintaining its efficacy and safety (Who, 2013).

Today, it is no longer a question of opposing plant-based treatments and chemical-based medicines, but of using them as a complement (Chevallier, 2016). In a context of growing poverty, disease resistance, lack of access to imported therapeutics and shortage of medicines in health facilities, and to help populations by deriving real benefit from the use of medicinal plants. It is becoming imperative to initiate scientific research work for the rational exploitation of the indisputable virtues of the plants in our pharmacopoeia in order to achieve the production of new plant-based preparations (phytomedicines) that would be effective against skin ailments at lower cost and accessible to all (Bene *et al.*, 2013).

Terminalia mantaly (Combretaceae) is widely used in traditional medicine, notably for gastroenteritis, high blood pressure, diabetes, oral and skin ailments (Yaye *et al.*, 2011). Skin pathologies are very numerous, and around 70% of the population is affected by a dermatosis at some point in their lives. Several microorganisms are implicated in skin infections, including bacteria (*Staphylococcus aureus*, β -hemolytic *Streptococcus*, etc.), viruses (varicella-zoster virus, proxviruses, etc.), fungi (*Trichophyton*, *Candida*, etc.) and, above all, the emergence of resistance.

The health hazards and inconveniences caused by microorganisms, and the large number of skin problems they cause in our society, prompt our team to commit to reducing their incidence, particularly that of ringworm and scabies in the general population.

The aim of the project is to make our contribution to the search for new molecules by exploiting the antifungal properties of the trunk's bark from *Terminalia mantaly* (figure 1), through the formulation of an ointment, with a view to treating people suffering from a number of skin ailments caused by fungi.

MATERIALS AND METHODS

MATERIALS

Biological material

The plant material consists of bark from *Terminalia neotaliala* Capuron (synonym: *Terminalia mantaly*); collected on 15 March 2022 from a stand of the tree located at the Felix Houphouet-Boigny University in Cocody (Ivory Coast). The plant has been identified at the Floristic National Center (FNC) under herbarium number UCJ003173.



Figure 1: *Terminalia mantaly*

Animal material

The therapeutic study involved 27 individuals, including sixteen (16) girls and eleven (11) boys. Their ages ranged from 6 to 62 years. In the case of minors, written consent was obtained from their parents. All the volunteers tested came from the Abidjan district. In the case of ringworm, seven (7) people were affected, including five (5) males and two (2) females. The choice of localities, individuals and gender was random.

METHODS

Preparation of total hydroalcoholic extract

T. mantaly bark was cut into small pieces and dried for 16 days in the sun and away from humidity. After drying, the bark was ground to a fine powder using a Retsch GM300 electric grinder. The 70/30

hydroalcoholic extract was obtained using the method of Zirihi *et al.* (2003) combined with the exhaustion method, which consists of macerating the pomace several times.

To this end, 100 g of plant powder were vigorously stirred in 1L of 70% ethanol/water using a BINATONE 365 electric mixer. The macerate obtained after several agitation cycles was wrung out on a square of cloth, then filtered four times successively on hydrophilic cotton and once on Whatman 3 mm paper. The filtrate obtained was concentrated in an oven at 50°C for 24 hours. The powder thus obtained constituted the total hydroalcoholic extract.

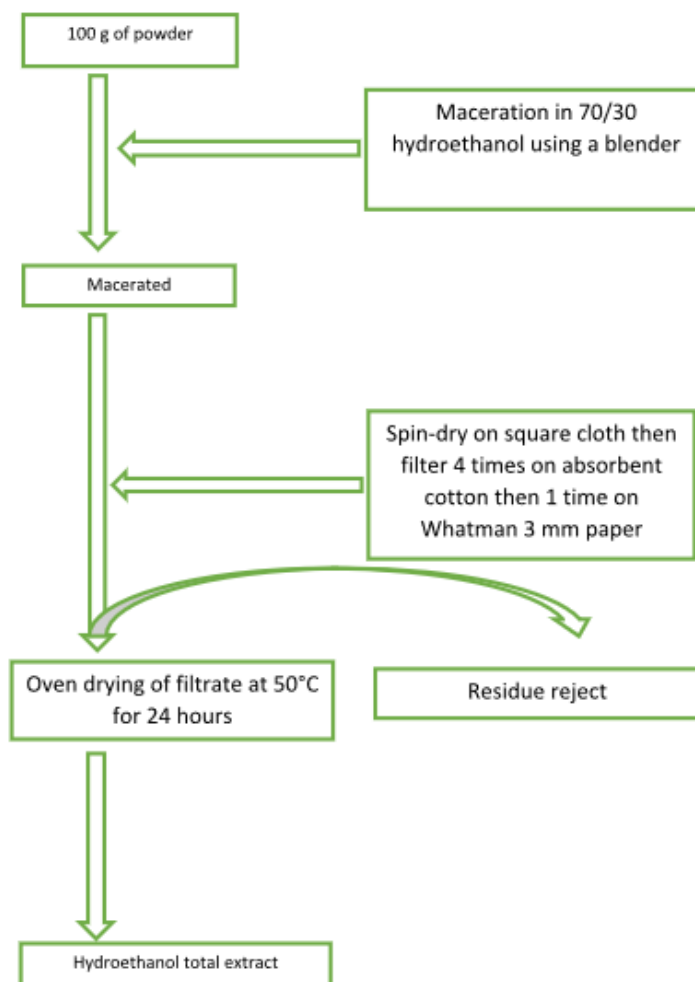


Figure 2 : Hydroethanol extraction method (Zirihi *et al.*, 2003)

Ointment formulation

Different concentrations have been chosen according to previous studies and marketing conditions. For the actual formulation, the following plant extract masses were used: 0.10g - 0.20 g - 0.30 g - 0.40 g - 0.50 g - 0.60 g - 0.70 g - 0.80 g - 0.90 g - 1 g and 1.5g, were crushed in a mortar using a porcelain pestle and mixed with 30 mL of melted shea butter on a hot plate at 40°C.

The treatment consisted of two (2) applications per day on the affected area over a 4-week period that we set ourselves. A follow-up visit was made after the first two days of treatment, and then every week until the end of the treatment.

Eleven ointments with respective concentrations C1: 0.0033 g/mL - C2: 0.0067 g/mL - C3: 0.01 g/ mL - C4: 0.013 g/mL - C5: 0.016 g/mL - C6: 0.02 g/mL - C7: 0.023 g/mL - C8: 0.027 g/mL - C9: 0.03 g/mL

- C10: 0.033 g/mL and C11 :0. 05g/mL were obtained and packaged in 40 mL plastic jars for solidification at room temperature.

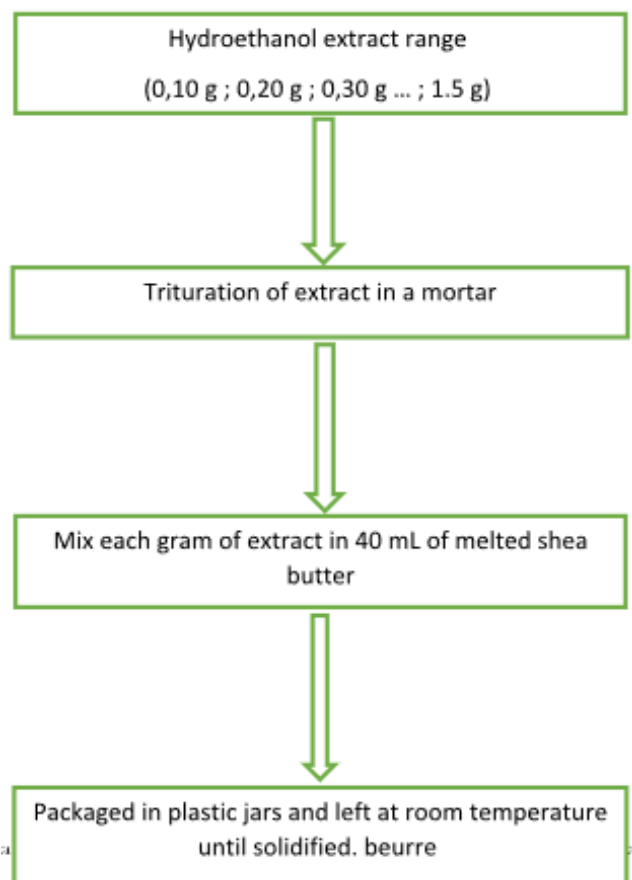


Figure 3: Ointment formulation method

RESULTS

Treatment of ringworm, scabs and pimples

Twenty-seven (27) volunteers applied the treatment. An improvement in the treatment of their skin conditions was observed after three days. However, three (3) volunteers taken at random from each group of treated pathologies received an ointment consisting solely of shea butter.

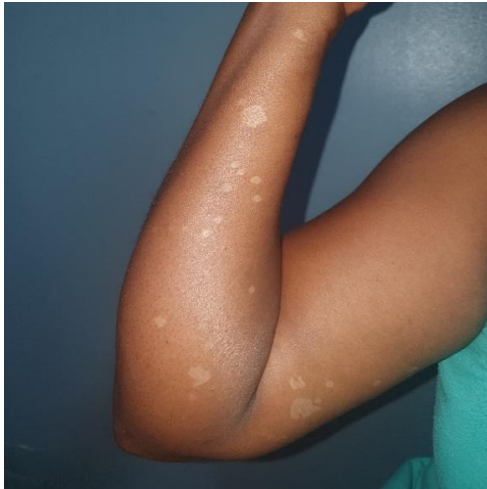After an average of 21 days, healing was observed in volunteers who had received shea butter and *Terminalia mantaly*. For the three (3) volunteers suffering from ringworm, scabies and pimples respectively, who received shea butter alone, there was no healing.

The other 24 volunteers treated with the ointment (shea butter+ *Terminalia mantaly*) were all cured of their ailments.

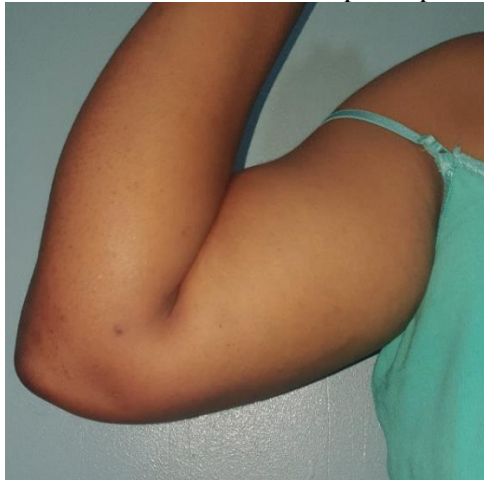In the case of scab, the lesions were small, superficial, well-defined spots a few millimeters in diameter, sometimes joined together or not, which were lighter or darker than the surrounding skin. These lesions were localized and extended over several parts of the body: the arm, forearm and face, but also over the entire surface of the back and front trunk, from the chest to the abdomen (**Figure 4A**).

Treatment of ringworm on areas without pilosity (shoulder and elbow crease) shows healing even with low concentrations. But the concentration of 0.05g/mL showed the best activity (**Figure 4B**). The pimples showed characteristics that are more or less similar to eczema, urticaria or food allergies. Indeed, eruptions of itchy red patches can be observed. These lesions were localized on different parts of the body, such as the skin of the hand and neck (**Figure 4C**).

Healing was observed after 4 and 6 days of treatment, depending on the progress of the condition and the concentration of the ointment. With the different concentrations, there was rapid improvement.



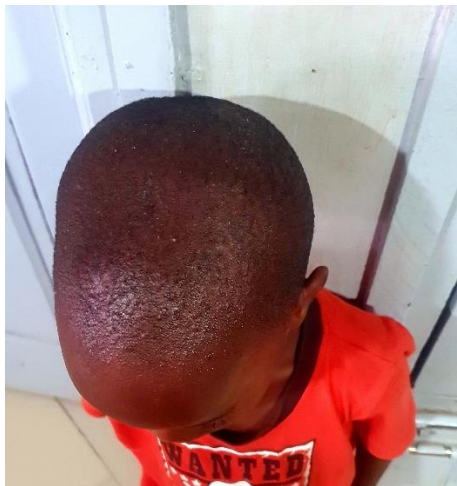A : Before treatment of scabs



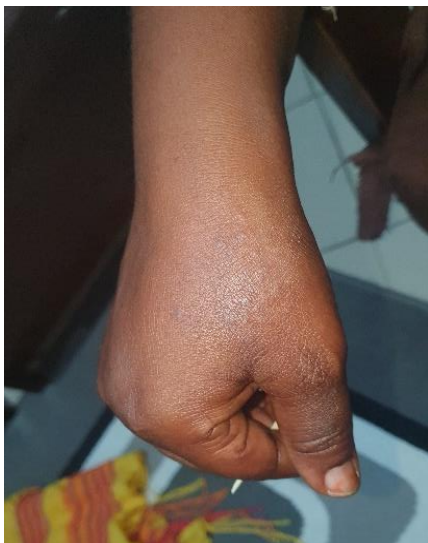A' : After 21 days of treatment



B : Before ringworm treatment



B' : After 24-days treatment



C : Before pimple treatment



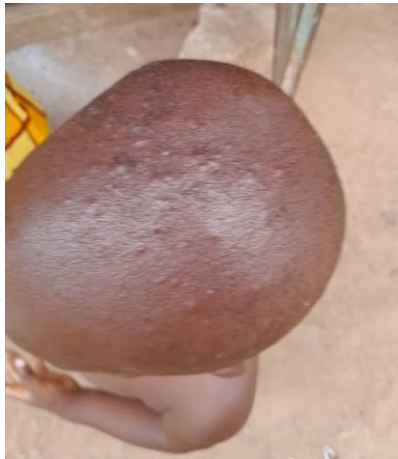C' : After 5-days treatment

Figure 4: Treatment of various skin conditions

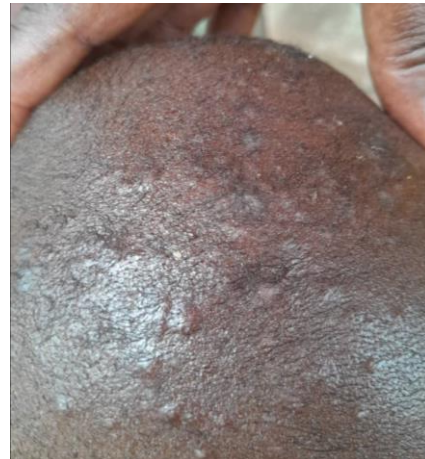These patients were each treated with seven (7) ointments of respective concentrations C1: 0.0033 g/mL - C2: 0.0067 g/mL - C3: 0.01 g/ mL - C6: 0.02 g/mL - C7: 0.023 g/mL - C8: 0.027 g/mL -C10: 0.033 g/mL.

Treatment of controls

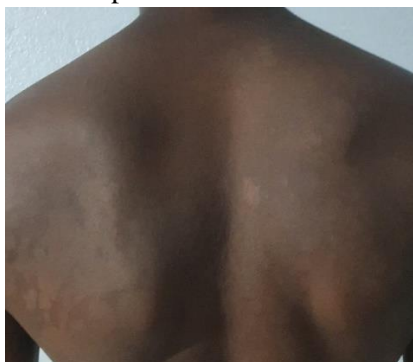
The various volunteers in the therapeutic trial were divided into three (3) groups according to the condition from which they were suffering. Then, within each group, we randomly selected a patient who received an ointment containing only shea butter, i.e. no *Terminalia mantaly* extract in the ointment. After a treatment of ten (10) days for the patient with pimples, and twenty-eight (28) days for the patients with ringworm of the scalp and with scab, no healing was observed (**figure 5**).



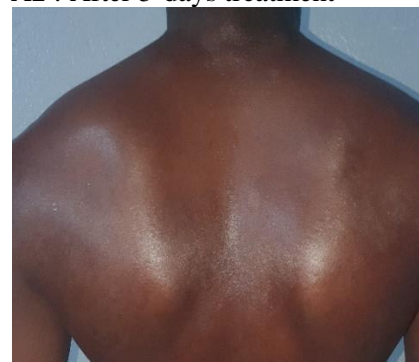A1 : Pimples on the skin



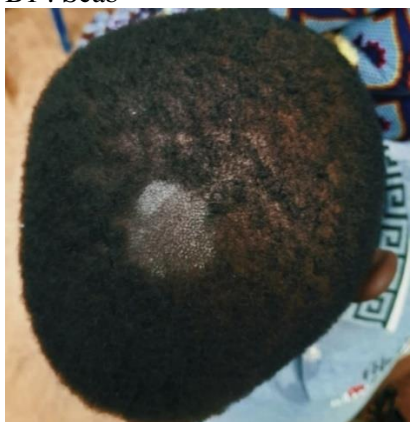A2 : After 5-days treatment



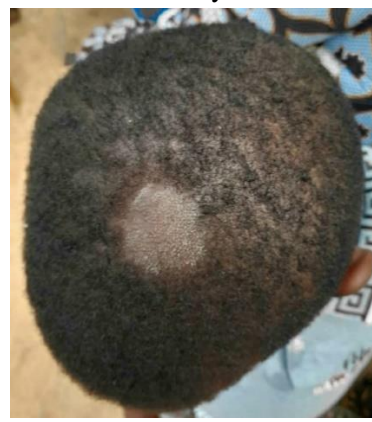B1 : Scab



B2 : After -20 days treatment



C1 : Moths



C2 : After -20 days treatment

Figure 5: Diffèrent patients who received only shea butter

DISCUSSION

Shea butter has been used as an excipient because it protects the skin, fights chapping, avoids allergic reactions and easily releases the active ingredient, given that the cell membrane is mainly made up of phospholipids. According to Eyang (2007), shea butter is preferred to other excipients such as vaseline and palm kernel oil because it releases the active ingredients better, is "organic" compared to vaseline, less messy and has a more pleasant or acceptable odor than palm kernel oil, which is more frequently used externally (Kporou *et al.*, 2021; N'Guessan, 2019).

The skin is not irritated, as the pH values of the ointments obtained (4.30 - 4.93) are in the order of those of Eyang (2007), who stipulates that a good ointment should have a pH between 4.2 and 5.8. These values would be linked to compatibility between the extract and the shea butter.

The ointment has been used to treat ringworm of the scalp, pimples and scabs.

Among the four children with scalp ringworm, aged between 3 and 15 years, only one girl (25%) had ringworm. The other three (75%) were boys, and there were no adult cases. This observation concurs with that of Boumhil *et al.*, (2010). According to him, scalp ringworm mainly affects children before puberty, particularly males, and is very rare in adults. For the prevention of scalp ringworm, it is no longer necessary to isolate the patient (Chabasse and Guiguen, 2019). Only good hygiene practices are recommended.

For cases of ringworm of the scalp, treatment lasted an average of 28 days. The majority of patients had alopecic scaly patches (50%), as demonstrated by Boumhil *et al.*, (2010) and Mebazza *et al.*, (2010), who found that the most common appearance was alopecic scaly patches. Other clinical aspects are less frequent.

The shortest treatment duration (4 days) was observed in the case of people with pimples. This result is in line with the findings of Lakhiari (2009), who used dermocorticoids for ten (10) days - a significantly longer duration.

According to N'Guessan (2019), dermatophytes of the skin were treated in 17 days, the same for Bene *et al.* (2013) and 21 days for Akakpo-akué *et al.* 2009. Although the ointment was made in a similar way to that of the Bene *et al.* (2013), the duration of treatment is better and this difference could be attributable to the secondary metabolites present in the extract and to the Combretaceae family, which is known for its antifungal and antibacterial properties. This difference could also be due to the different nature of the extract.

For the treatment of scabs, daily application of the antimicrobial ointment (0.05g/mL) resulted in healing after 21 days. This treatment time is similar to that of the ointment by (N'Guessan, 2019) and the DAEL cream by (Akakpo-Akué *et al.*, 2009). The treatment duration (21 days) is slightly shorter than that of Bene *et al.* (2013) who treated scabs in (23 days). This slight difference may be linked to the difference in the plant, the area affected, the extent of the condition and the form of medication used. The patient's physiological state also has an influence on the treatment of an ailment. These 21 days of treatment are roughly equal to the duration of treatment with modern medicines, which is generally 20 days.

All concentrations (C1: 0.0033 g/mL - C2: 0.0067 g/mL - C3: 0.01 g/mL - C4: 0.013 g/mL - C5: 0.016 g/mL - C6: 0.02 g/mL - C7: 0.023 g/mL - C8: 0.027 g/mL - C9: 0.03 g/mL - C10: 0.033 g/mL - C11 :0.05g/mL) used to formulate the ointment were all active on the various mycoses treated. This analysis shows that the formulated ointment has good activity on dermatoses. Concentrations ranging from C4 to C10 had the best activity on all dermatoses, as did concentration C11, which cured a patient who, after several years of treatment, was still suffering from scabs.

The duration of treatment varies from case to case, since the extent of the condition, the affected area and the dose are not the same. This treatment time for pimples is due to the absence of hair in the affected areas. Hair is an area where dermatoses proliferate, making it difficult for the drug to penetrate and reach the site of action (Kporou *et al.*, 2021). This variability in treatment duration may also be linked to non-compliance with dosage during treatment.

ACKNOWLEDGMENTS

At the end this study, financial support to research and pedagogy unity of biochemical of pharmacodynamics, the national center of floristics from department of University Felix HOUPHOUET BOIGNY in Cocody-Abidjan (Ivory Coast) and unit of fundamental Medical Biochemistry of Pasteur institute (in Cocody-Abidjan; Ivory Coast) are gratefully acknowledged.

CONFLICTS OF INTEREST

The author declares no conflict of interest regarding the publication of this article.

CONCLUSION

This study shows that the 70% hydroethanol extract of *Terminalia mantaly* bark does indeed have antifungal properties. The extract incorporated with shea butter preserved the activity of the active ingredients, while shea butter enhanced activity by facilitating penetration of the active ingredient through the skin.

The most active concentrations are C4: 0.013 g/mL - C5: 0.016 g/mL - C6: 0.02 g/mL - C7: 0.023 g/mL - C8: 0.027 g/mL - C9: 0.03 g/mL - C10: 0.033 g/mL. C11 :0.05g/mL).

However, the C11:0.05g/mL concentration gives the best results in the treatment of our various dermatoses (ringworm, scabies, pimples).

REFERENCES

- Akakpo-Akue M, Gbery IP, Kra AKM, Zirihi GN, Yapi FH and Djaman AJ (2009).** Evaluation of the antifungal activity and clinical trial of a cream formulated with *Terminalia catappa* extract X12, on some superficial mycoses, *Ivorian Journal of Science and Technology*, **13**, 175-190.
- Bene K, Camara D, Soumahoro IA, Kanga Y and Zirihi GN (2013).** Galenical formulation of an antimicrobial ointment based on a hydroethanolic extract of *Bersama abyssinica* Fresen. *Ethnopharmacologia*, **(58)** 60-69.
- Boumhil L, Hjira N and Naoui H (2010).** Scalp ringworm at the Mohammed V Military Hospital. *Journal of Medical Mycology*. **20**(2) 97-100.
- Chabasse D and Guiguen C (2019),** Dermatophytes: interpretation difficulties and pitfalls of mycological diagnosis. *French-speaking Laboratories Journal* **(510)** 26-35.
- Chevallier L (2016).** Less drugs, more plants. Fayard Edn., France 384pp.
- Bourdy G, Fleurentin J and Weniger B (2011).** Therapeutic traditions and tomorrow's Medicine / The challenges of ethnopharmacology, Ouest-France Edn, Rennes, 72-73.
- Eyang EM (2007).** Study of the phytochemistry and antibacterial and antifungal activities of five medicinal plants used in the traditional treatment of dermatoses in Mali, Doctoral thesis from the Faculty of Medicine, Pharmacy and Odontostomatology, University of Bamako, Mali,175p.
- Guessennd NK (2013),** Study of multi-resistant bacteria in hospital effluent from a University Hospital Center (CHU) in Abidjan (Côte d'Ivoire), *Journal of Applied Biosciences*, **69**, 5456 – 5464,
- Hancock REW (2007),** The end of an era, *Nature Reviews Drug Discovery*, **6**, 28.
- Kporou KE, Ouattara S, Gbogbo M, Guedji YP, Kra AKM and Djaman AJ (2021).** Quality, safety and activity of an ointment formulated from *Butyrospermum parkii* and *Ricinus communis* oils on rabbits hair growth. *RAMReS review – Traditional African Pharmacopoeia and Medicine*" series **20**(1) 38-46.
- Lakhiari M (2009).** Allergic contact dermatitis: from pathophysiology to treatment. Ph thesis. Mohamed V University. Maroc 100pp.
- Mebazaa A, Fathallah A and El Aouamri K (2010).** Epidemioclinical profile of scalp ringworm in central Tunisia. Review of a 16-year retrospective study (1990-2005). *Journal of Medical Mycology* **20** (2): 91-96.
- N'guessan CDR (2019).** Formulation of an ointment from hydroethanol extract of *Terminalia ivorensis* and therapeutic trial on volunteers suffering from ringworm. *Master's degree. University Felix Houphouet Boigny. Ivory Coast.* 49p

- Orsot B, Coulibaly K, Sanogo Y and Zirihi G (2021)**, Medicinal plants, an alternative treatment for skin diseases in Ivory Coast. *Journal of Animal & Plant Sciences*, **49**(1) 8754-8773
- Traoré K (2013)**, Ivory Coast: traditional medicine prized by 80% of the population AFRIK.COM: Ivory Coast - Population. Paris. [Accessed 7 August 2015]
- Who (2013)**, Strategy for traditional medicine 2014-2023. Progress report, 75 p.
- Yaye G, Kra A, Ackah B and Djaman A (2011)**, Evaluation of antifungal activity and active ingredient purification tests of *Terminalia Mantaly* H. Per., combretaceae extract on the *in vitro* growth of *candida albicans*, *Royal Society Bulletin of Liege City Sciences*, **80** 953-964
- Zirihi NG, Kra MKA and Guede-Guina F (2003)**, Evaluation of the Antifungal activity of *Microglossa pynfolia* (LAMARCK) O. KUNZE (Asteraceae) "PYMI" on the *in-vitro* growth of *Candida albicans*, *African Review of Medicine and Pharmacocology* (**17**) 11-18