

Case Report

UNUSUAL SITE OF CUTANEOUS CYSTICERCOSIS – A CASE REPORT

Joshi N., Nag B.P., *Agrawal R. and Dubey D.

Department of Pathology, Mahatma Gandhi Medical College & Hospital, Sitapura – Jaipur, Rajasthan
(India) 302022

*Author for Correspondence

ABSTRACT

We report a case of cutaneous cysticercosis of cheek an unusual site which was clinically reported as sebaceous cyst. Here lies the importance of histopathological examination which gave the final diagnosis.

Key Words: *Cysticercus Cellulosae*, *Taenia Solium*, *Cysticercosis*

INTRODUCTION

Cysticercosis is an infection with larval stage of *Taenia solium* in human. The clinical disorder is named after the parasite at this larval stage *cysticercus cellulosae*. The larva of tapeworm *Taenia solium* have predilection for skeletal muscle, central nervous system and subcutaneous tissue (Singrodiya *et al.*, 2008). In India the first case of cutaneous cysticercosis was reported by Combell and Thomson in 1912n (Arora *et al.*, 1990).

CASES

A 28yrs old male presented with a painless solitary swelling on right side of cheek of 2yrs duration. The swelling was insidious in onset, gradually increasing in size, not associated with pain or fever. Examination revealed a 1cmx1cm round smooth swelling non tender, not attached to the underlying muscle. General and systemic examination was within normal limits.

Clinically diagnosed as sebaceous cyst, removed and sent for histopathological examination in the department of pathology. Grossly, it was single grey white cystic piece measuring 0.5x0.5cm in size. Microscopic examination revealed a tortuous body of larva which was continuous with cystic layer, (figure1 and figure 2), and diagnosed as *cysticercus cellulosae*, *Taenia solium* larva.

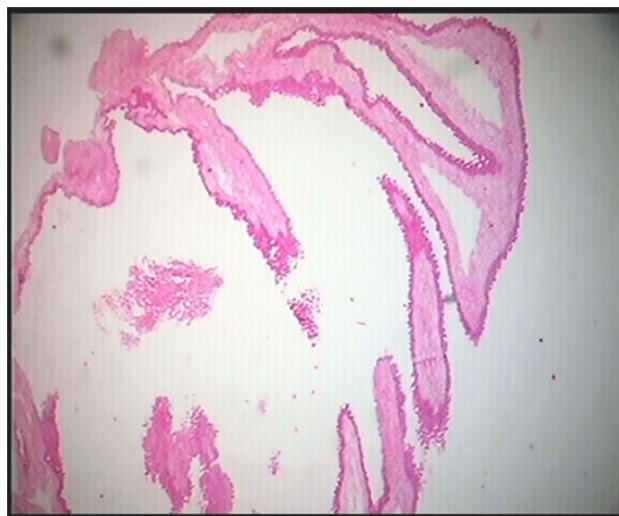

Figure 1: HE x100 Microphotograph of a cyst. cyst wall of *cysticercus cellulosae*.

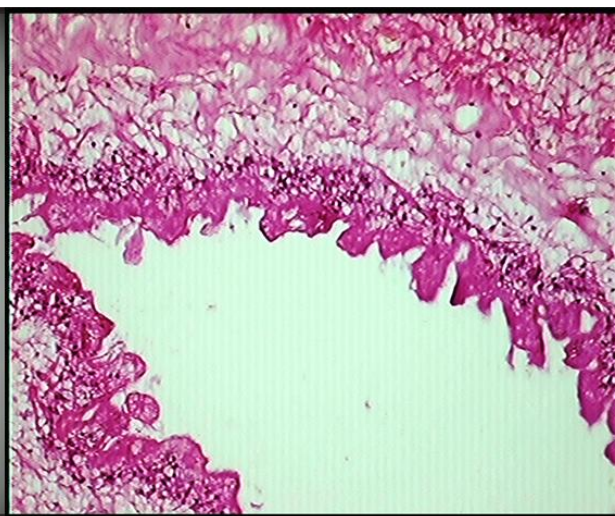


Figure 2: HE x400 Microphotograph showing

Case Report

DISCUSSION

Cysticercosis is an infection with *cysticercus cellulosae* the larval stage of *Taenia solium* or pork tape worm. *Taenia solium* passes its life cycle in two hosts. The definite host is human who harbours the adult worm and intermediate host is pig which harbours the larval stage (Patel *et al.*, 2011). Human infection with *cysticercus* is due to ingestion of eggs in contaminated food or drink or by reverse peristalsis of eggs or proglottides from the intestine to stomach.

On reaching the stomach these eggs rupture and oncospheres are liberated. They penetrate the wall and enter the systemic circulation (Arun C Inamadar and Yelikar, 2001). Auto infection occurs mostly by hand and mouth with person's own faeces. Cutaneous cysticercosis does not carry any risk to the patient's health but they are often a pointer to the involvement of internal organs like brain which causes seizures (Falanga and Kapoor, 1985).

In the series of 33 patients reported by Arora *et al.*, (1990) 27 patients with multiple cysts had involvement of brain. In the present case there was no involvement of brain possibly indicating that solitary lesion will not be associated with internal organ cysticercosis (Mishra *et al.*, 1970). Cytomorphological spectrum of subcutaneous intramuscular cysticercosis was reported by Gill *et al.*, (2010) in 22 cases and authors emphasized the importance of fine needle aspiration in the diagnosis of cysticercosis. The importance of this case lies not only in its unusual site of presentation but also emphasize the value of histopathological examination in establishing the diagnosis since neither clinical examination nor history suggested the diagnosis other than the benign lesion.

REFERENCES

- Arora PN, Sanchette PC, Ramkrishnan KR and Venkataraman S (1990). Cutaneous, mucocutaneous and neurocutaneous cysticercosis. *Indian Journal of Dermatology, Venereology and Leprology* **50** 115-118.
- Arun C Inamadar and BR Yelikar (2001). Cysticercosis Cellulosae cutis. *Indian Journal of Dermatology, Venereology and Leprology* **67** 198-199.
- Falanga V and Kapoor W (1985). Cerebral Cysticercosis - Diagnostic Value of subcutaneous nodule. *Journal of the American Academy of Dermatology* **12** 304.
- Gill M, Dua S, Gill PS, Gupta V, Gupta S and Sen R (2010). Cytomorphological spectrum of subcutaneous and intramuscular cysticercosis. A study of 22 cases, *Journal of Histochemistry & Cytochemistry* **27**(4) 123-126.
- Mishra RS and Dharmpal Bikchandani R (1970). A review of cysticercosis cellulosae with two case reports. *Indian Journal of Dermatology, Venereology and Leprology* **36** 164.
- Patel K, Shah M, Patel B and Doshi N (2011). Subcutaneous oral cysticercosis. *National Journal of Community Medicine* **2**(2) 311-313.
- Singrodia S, Joshi RG, Solanki RB and Rawat RC (2008). Subcutaneous nodules preceding convulsions due to neural cysticercosis. *Indian Journal of Dermatology, Venereology and Leprology* **74** 385-6.