

Case Report

TIBIOFASCIALIS ANTICUS- A RARE VARIATION

***Anjali Jain, Aprajita Sikka and Neeru Goyal**

Department of Anatomy, Christian Medical College, Ludhiana

**Author for Correspondence*

ABSTRACT

Tibialis anterior, the most medial and superficial dorsiflexor, is a slender muscle that lies against the lateral surface of tibia. During routine dissection in the Department of Anatomy, Christian Medical College, Ludhiana, an unusual course and insertion of tibialis anterior was noticed in the left lower limb of an adult male human cadaver. The tendon of the muscle passed superficial to the inferior extensor retinaculum instead of passing deep to it. And it also gave off a slip which passed above the tendon of extensor hallucis longus and got inserted on to the deep fascia covering the extensor hallucis brevis on the dorsum of the foot. Tendon of tibialis anterior is commonly used in tendon transfer as a treatment of various clinical conditions. So knowledge of such rare variations in the course and attachment of the muscle is of academic and clinical significance.

Key Words: *Inferior Extensor Retinaculum, Tibialis Anterior, Tendon Transfer*

INTRODUCTION

Tibialis anterior, the most medial and superficial dorsiflexor, is a slender muscle that lies against the lateral surface of tibia (Moore and Dalley, 2006). It arises from the lateral condyle and proximal half to two-thirds of the lateral surface of the tibial shaft, from the adjoining anterior surface of the interosseous membrane, from the deep surface of the fascia cruris and from the intermuscular septum between it and extensor digitorum longus. The muscle descends vertically to end in a tendon in the lower third of the leg; the tendon passes through the medial compartments of the superior and inferior extensor retinacula, inclines medially, and inserts into the medial and inferior surfaces of the medial cuneiform and the adjoining part of the base of the first metatarsal bone (Standring *et al.*, 2008). Standard textbooks of anatomy describe that the tendon of tibialis anterior passes deep to the inferior extensor retinaculum (Moore and Dalley, 2006; Standring *et al.*, 2008; Sinclair, 1991; Rosse and Roose, 1997). The present case reports a rare relation of the tendon of tibialis anterior with the inferior extensor retinaculum and also describes an unusual variation in the mode of insertion of the muscle. The tendon of tibialis anterior is commonly used in tendon transfer as a treatment of recurrent congenital clubfoot and paralytic equinovarus foot deformities in cerebral palsy and arthroscopy. So the knowledge of variations in course and attachment of this tendon is of academic and clinical significance to anatomists, orthopaedicians, radiologists and surgeons.

CASES

During routine practical classes for MBBS students in the Department of Anatomy, Christian Medical College, Ludhiana, an unusual course and insertion of tibialis anterior was noticed in the left lower limb of an adult male human cadaver. In this case the tibialis anterior muscle after taking origin descended down vertically and passed deep to the superior extensor retinaculum after which it became tendinous. The muscle then took a rare and unusual course by passing superficial to the proximal and distal limbs of the inferior extensor retinaculum instead of passing deep to it (Figure 1). Subsequently it passed medial to extensor hallucis longus and again showed an unexpected variation by giving off a slip which passed above the tendon of extensor hallucis longus and got inserted on to the deep fascia covering the extensor hallucis brevis on the dorsum of the foot. The other thick part of the tendon crossed the medial border of foot, passed medial to the extensor hallucis longus and got inserted on to the medial cuneiform and first metatarsal. Origin, course and insertion of the muscle were usual on the right side.

Case Report

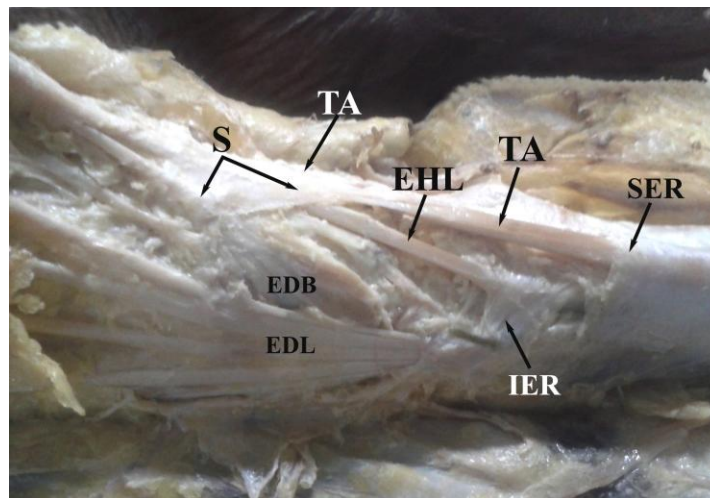


Figure 1: Variation in course and insertion of tibialis anterior. EDB- Extensor digitorum brevis; EDL- Extensor digitorum longus; EHL- Extensor hallucis longus; IER- Inferior extensor retinaculum; SER- Superior extensor retinaculum; S-Slip from the tendon of tibialis anterior; TA- Tibialis anterior.

DISCUSSION

Tibialis anterior is the primary dorsi flexor of the ankle and an adequate knowledge of its normal anatomy and variations in attachments and course is required for clinicians. Ebraheim et al. (2003) found the muscle to be a relatively easy flap to use for covering anterior tibial open wounds. It is also used in tendon transfer as a treatment of recurrent congenital clubfoot and paralytic equinovarus foot deformities in cerebral palsy and arthroscopy (Ikiz and Üçerler, 2005).

Thompson *et al.*, (2009) stated that recurrent dynamic and structural deformities following clubfoot surgery are commonly due to residual muscle imbalance from a strong tibialis anterior muscle and weak antagonists. They used the tibialis anterior tendon transfer to restore muscle balance in recurrent clubfoot. Tibialis anterior tendon can also be used as a distal landmark for extra medullary alignment in total knee arthroplasty. Using this tendon as distal landmark eliminates any interobserver variability by providing an easily palpable fixed anatomical structure (Rajadhyaksha *et al.*, 2009). Transfer of tibialis anterior into the talus has been utilized for correction of vertical talus, as well as for paralytic valgus foot deformities (Kissel and Blackledge, 1995).

As the tendon of tibialis anterior is important for surgeons and orthopaedicians there is a need for awareness of variations in this area. The inferior extensor retinaculum is a Y-shaped band lying anterior to the tibiotalar joint. The stem of the Y is at the lateral end, where it is attached to the upper surface of the calcaneus. At the medial end, the Y is completed by two diverging bands. The more proximal band has two layers. The deep layer passes deep to the tendons of extensor hallucis longus and tibialis anterior, but superficial to the anterior tibial vessels and deep peroneal nerve, to reach the tibial malleolus. The superficial layer crosses superficial to the tendon of extensor hallucis longus and then adheres firmly to the deep one; in some cases it continues superficial to the tendon of tibialis anterior before blending with the deep layer. The more distal band extends downwards and medially and is attached to the plantar aponeurosis. It is superficial to the tendons of extensor hallucis longus and tibialis anterior, the arteria dorsalis pedis and the terminal branches of the deep peroneal nerve (Standring *et al.*, 2008). Standard Textbooks of anatomy have described that the tendon of tibialis anterior passes deep to the inferior extensor retinaculum (Moore and Dalley, 2006; Standring *et al.*, 2008; Sinclair, 1991; Rosse and Roose, 1997). But in the present study, the tendon was seen passing superficial to both proximal and distal bands of the inferior extensor retinaculum.

Case Report

The usual insertion tibialis anterior is on to the medial and inferior surface of medial cuneiform and adjoining part of base of the first metatarsal. Variations in attachments of tibialis anterior have been recorded by previous authors as attachment to talus, first metatarsal head or base of the proximal phalanx of hallux (Standring *et al.*, 2008). But in the present study, the tendon gave off an aponeurotic slip which passed above the tendon of extensor hallucis longus and got inserted on to the deep fascia covering the extensor hallucis brevis on the dorsum of foot. The other thick part of the tendon inserted on to the medial and inferior surface of medial cuneiform and base of first metatarsal. Only one reference of this rare observation was found in the Textbook of Quains (Schafer and Thane, 1892) where it is mentioned that tibiofascialis anticus is a small muscle arising from the lower part of tibia and inserts into the annular ligament (retinaculum) and deep fascia. It may also exist as a tendinous slip from the tibialis anterior. The present case reports a presentation of tibiofascialis anticus in which a slip from tibialis anterior was inserted on to the deep fascia over the dorsum of foot.

REFERENCES

- Ebraheim NA, Madsen TD and Humpherys B (2003).** The tibialis anterior used as local muscle flap over the tibia after soft tissue loss. *Journal of Trauma* **55**(5) 959-961.
- Ikiz AAZ and Üçerler H (2005).** A previously unreported variation related to the insertion of the tibialis anterior muscle and the superficial fibular (peroneal) nerve. *Anatomical Science International* **80**(3) 172-175.
- Kissel CG and Blackledge DK (1995).** Transfer of tibialis anterior into talus for control of the severe planus pediatric foot: a preliminary report. *Journal of Foot and Ankle Surgery* **34**(2) 195-199.
- Moore KL and Dalley AF (2006).** Lower limb. In: *Clinical Oriented Anatomy*, Lippincott, Williams and Wilkins, **5** 638.
- Rajadhyaksha AD, Mehta H and Zelicof SB (2009).** Use of tibialis anterior tendon as distal landmark for extramedullary tibial alignment in total knee arthroplasty: an anatomical study. *American Journal of Orthopaedics* **38**(3) E68-70.
- Rosse C and Rosse PG (1997).** The free lower limb: thigh, leg and foot. In: *Hollinshead's Textbook of Anatomy*, Lippincott Raven, New York, **5** 337-490.
- Schafer EA and Thane GD (1892).** Muscle and fascia of the lower limb. In: *Quain's Elements of Anatomy*, Longmans, Green and Company, London, **10**(2) 259.
- Sinclair DC (1991).** Muscle and fascia. In: *Cunningham's Textbook of Anatomy*, Oxford University Press, Toronto, **12** 388.
- Standring S, Healy JC, Johnson D, Collins P, Borley NR, Crossman AR et al (2008).** Leg. In: *Gray's Anatomy- The Anatomical Basis of Clinical Practice*, Churchill Livingstone, UK, **40** 1417, 1429.
- Thompson GH, Hoyen HA and Barthel T (2009).** Tibialis anterior tendon transfer after clubfoot surgery. *Clinical Orthopaedics and Related Research* **467**(5) 1306-1313.