

Case Report

A CASE OF PATELLAR TENDON AVULSION IN AN OCHRONOTIC PATIENT AND A REVIEW OF THE LITERATURE

Nakul Shah,*Dylan Goveas and Madhav Khadilkar

Department of Orthopaedics

Shrimati Kashibai Navale Medical College and General Hospital, Narhe, Pune, India

ABSTRACT

Alkaptonuria is an autosomal recessive disorder of rare occurrence having an estimated prevalence of below 1:250000 (Mannoni, 2004). Ochronosis which is the musculoskeletal manifestation of the disease causes degeneration of the spine, weight bearing joints, tendons and ligaments. A study has reported three patients with four spontaneous ruptures of either the patellar tendon or tendoachillis as the first symptom of alkaptonuria (Kumar, 2003). We present a 60 year old male with avulsion of the patellar tendon due to ochronosis.

Key Words: Alkaptonuria, Ochronosis and Homogentestic Acid

INTRODUCTION

The patellar tendon may avulse spontaneously or by trivial trauma. Systemic diseases like systemic lupus erythematosus, rheumatoid arthritis, renal failure, hyperparathyroidism and diabetes mellitus have been associated with spontaneous tendon ruptures (Martin, 1958; Razzano, 1973; Hughes, 1979; and Preston, 1972). We present a case of spontaneous avulsion of the patellar tendon due to ochronosis. Scribonius in 1584 first described ochronosis in a boy whose urine was as “black as ink”. Boedeker in 1891 first coined the term Alkaptonuria, as quoted by Fischer *et al.*, (2004). Alkaptonuria or homogentestic acid oxidase deficiency is a rare metabolic disorder. Excessive homogentestic acid is excreted in the urine, which often turns dark, and HGA accumulates in connective tissues, including the dermis. Alkaptonuria has been the first disease to be interpreted as a mendelian recessive trait. In this disease homogentestic acid, an intermediate in the metabolism of phenylalanine and tyrosine, cannot be further metabolized. The cause is a mutation in the homogentisate 1, 2 -dioxygenase acid oxidase gene on chromosome bands 3q21 -q23.

CASES

A 60 year old male presented to our hospital with pain in the right knee following a history of trivial trauma. Subsequent to the trauma he was unable to walk unaided or climb stairs. He had a history of long standing back and knee pain. Clinically there was tenderness of the patellar tendon and inability to perform an active straight leg raise test. Avulsion of the patellar tendon was suspected. The patient had a pigmented sclera, thickened and pigmented, helix, antihelix and tragus, pigmented and thickened palmar skin (Figure 1a, b).

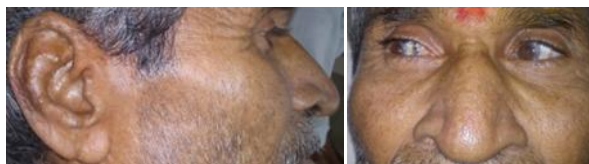

Figure 1a: Photograph of the patient showing pigmented and thickened helix, antihelix and tragus of the ear and pigmented sclera

X-ray showed a high riding patella, degenerative arthritis with osteophytes (Figure2). MRI of the knee showed avulsion of the patellar tendon from the tibial tubercle attachment with cranial migration of the patella (Figure 3). At operation the knee was exposed with a midline incision which revealed an avulsion of the patellar tendon from the tibial tuberosity. The edge of the patellar tendon was frayed and pigmented. The articular cartilage was blackened along with 1*1.5cm irregular loss of cartilage over the

Case Report

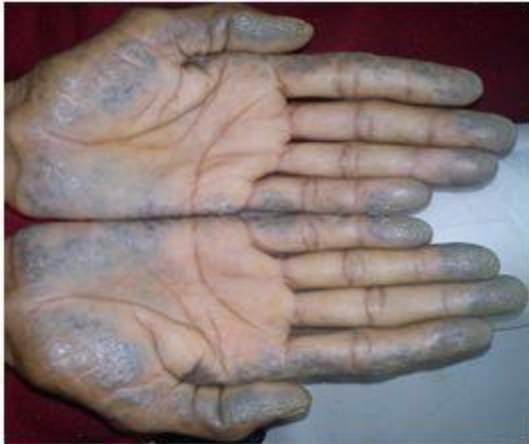

Figure 1b : Photograph showing thickened and pigmented palms

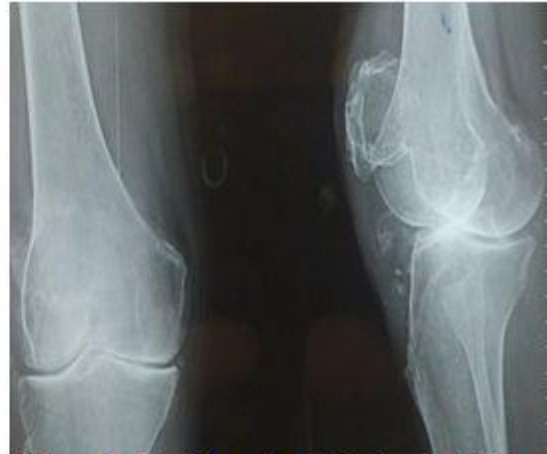

Figure 2 : Radiograph of the involved knee showing high riding patella and degenerative arthrosis

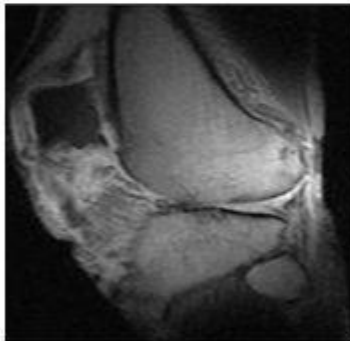

Figure 3 : MRI of the involved knee showing avulsion of the patellar tendon from the tibial tuberosity

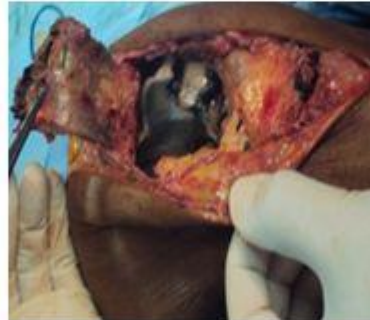


Figure 4 : Intraoperative photograph showing frayed and pigmented patellar tendon with hypertrophic and pigmented synovium, pigment deposition over the articular cartilage and loss of articular cartilage

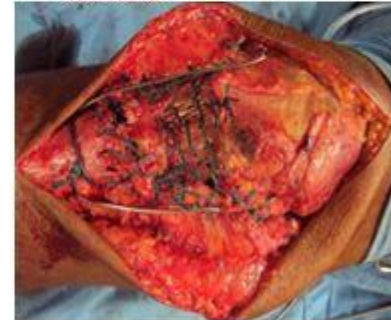

Figure 5 : Tenodesis of the patellar tendon and protection of the repair with an 18 gauge defunct stainless steel wire

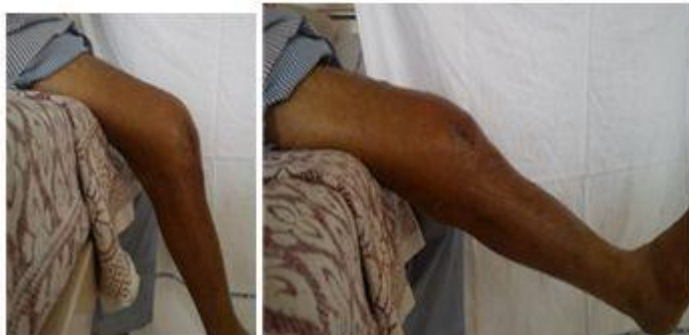

Figure 6 : Two months post surgery and after removal of defunct wire, patient is able to actively extend the knee joint

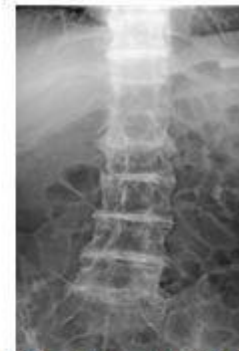

Figure 7 : Radiograph of the spine showing calcified intervertebral discs

Case Report

medial condyle of the femur exposing the subchondral bone. The menisci was pigmented and frayed. The synovium was hypertrophied and heavily pigmented. A histopathological examination of a portion of the pigmented tendon, frayed cartilage and synovium was sent which subsequently revealed hyperplastic synovial tissue with villous proliferation seen as brownish black to yellow brown fragments of variable size and shape in the subsynovial lining (Figure 4). A tenodesis of the patellar tendon to the tibial tuberosity with 5-0 Ethibond sutures with the Krakow stitch technique was done which was protected with an 18 gauge stainless steel wire (Figure 5). Two months after the surgery the defunct wire was removed. The patient could actively extend the knee suggesting good tendon to bone healing (Figure 6). X-ray of the spine showed calcification of the intervertebral discs (Figure 7). The patient's first degree relative had a spontaneous bilateral tendoachilles avulsion.

DISCUSSION

Alkaptonuria, an autosomal recessive disorder, is caused by a deficiency of homogentisic acid oxidase leading to an accumulation of HGA which accumulates in the connective tissues. The accumulated HGA is rapidly cleared by the kidneys and excreted in the urine (Garrod, 1902). The enzyme HGO is normally present in the soluble fraction of the liver and kidney cells and is highly specific for HGA. HGO activity is totally absent from liver and kidney tissue from alkaptonuric patients. In patients with alkaptonuria, HGA undergoes renal excretion or is transformed into ochronotic pigment within connective tissue. Once excreted, HGA which is itself colourless gradually gets oxidized to dark products when the urine is left to stand and is exposed to air but this is hastened by alkalization (O'Brien, 1963). Ochronosis is caused by accumulation of HGA which causes darkening of the cartilage, joint destruction and cardiac valve deterioration. The disease may go unrecognized until middle life when degenerative joint disease develops. Degenerative joint disease usually develops after the third decade. A large series has reported low backache in 94% of the patients (Phornphutkul, 2002). Scleral pigmentation and darkening of the ear cartilage usually develop after the age of 30 years. The spine and major weight bearing joints like hips and knees are frequently involved in ochronotic arthropathy (Aydogdu, 2000). Radiographs of the spine show characteristic calcification of the intervertebral discs, loss of lordosis and clinically a decrease in the range of movement. Joint destruction of the hips and knees can be severe enough to warrant a total joint replacement (Corra, 1995). A study has reported that 50% of patients require at least one joint replacement. Tendons due to their high collagen content are sites of ochronotic pigment deposition (Jozsa, 1997) The likelihood of spontaneous tendon rupture is increased due to the accumulation of HGA which inhibits collagen cross linking leading to reduction of the structural integrity of collagen (Emel, 2000).

While examining cases of spontaneous tendon ruptures, diseases such as rheumatoid arthritis, SLE, diabetes mellitus, hyperparathyroidism and ochronosis should be borne in mind. These diseases can be ruled out by their specific clinical, laboratory and radiological features. Our patient had pigmented sclera, pigmented and thickened ear cartilage, pigmented and thickened palmar skin with a characteristic radiological picture of the ochronotic spine and degenerative changes of the involved knee joint. There is also a history of the patient's first degree relative having spontaneous avulsion of the tendoachilles. Alkaptonuria does not have a specific treatment. Ascorbic acid has been tried since this being an antioxidant reduces HGA oxidation. Nitisonone reduces urinary excretion of HGA and, in conjunction with a low protein diet, might prevent the long term complications of alkaptonuria (Suzuki, 1999).

ACKNOWLEDGEMENT

I sincerely thank the Department of Orthopaedics, Smt. Kashibai Navale Medical College and General Hospital, Pune for supporting and encouraging the publication of this article.

REFERENCES

Aydogdu S et al., (2000). Cementless total knee arthroplasty in ochronotic arthropathy: A case report with four-year follow-up. *Journal of Arthroplasty* **15** 539-543.

Case Report

- Bhole R and Johnson JC (1985).** Bilateral simultaneous spontaneous rupture of quadriceps tendons in diabetic patient. *Southern Medical Journal* **78** 486.
- Corra T, Zaccala M and Galante M (1995).** Ochronotic arthropathy: rapid destructive hip osteoarthritis associated with metabolic disease. *Clinical Rheumatology* **14** 474-477.
- Emel E et al., (2000).** Alkaptonuria with lumbar disc herniation: a report of two cases. *Spine* **25** 2141-2144.
- Fisher AA and Davis MW (2004).** Alkaptonuric ochronosis with aortic valve and joint replacements and femoral fracture. *Clinical Medicine and Research* **2** 209-215.
- Garrod AE (1902).** The incidence of alkaptonuria: a study in chemical individuality. *Yale Journal of Biology and Medicine* **75**(4) 221-231.
- Hughes GN and Harder JA (1979).** Bilateral patellar tendon rupture associated with chronic glomerulonephritis. *Canadian Journal of Surgery* **22** 389.
- Jozsa L and Kannus P (1997).** *Human tendons – Anatomy, Physiology and Pathology* . Champaign, Illinois USA: Human Kinetics Publishers.
- Mannoni A, Selvi E and Lorenzini S et al., (2004).** Alkaptonuria, ochronosis and ochronotic arthropathy. *Seminars in Arthritis and Rheumatism* **33** 239-248.
- Manoj Kumar RV and Rajasekaran S (2003).** Spontaneous tendon ruptures in Alkaptonuria. *The Journal of Bone and Joint Surgery* **85B** 883-886.
- Martin JR, Wilson CL and Matthews WH (1958).** Bilateral rupture of the ligmenta patella in a case of disseminated lupus erythematosus. *Arthritis and Rheumatism* **1** 548-552.
- O'Brien WM, La Du BN and Bunim JJ (1963).** Biochemical, pathologic and clinical aspects of alcaptonuria, ochronosis and ochronotic arthropathy: review of world literature (1584-1962). *American Journal of Medicine* **34** 813-838.
- Phornphutkul C et al., (2002).** Natural history of alkaptonuria. *New England Journal of Medicine* **347** 2111-2121.
- Preston ET (1972).** Avulsion of both quadriceps tendons in hyperparathyroidism. *JAMA* **221** 406-407.
- Razzano CD, Wilde and Phalen GS (1973).** Bilateral rupture of the infrapatellar tendon in rheumatoid arthritis. *Clinical Orthopaedics* **91** 158-161.
- Suzuki Y et al., (1999).** A novel therapeutic trial of homogentisic aciduria in a murine model of alkaptonuria. *Journal of Human Genetics* **44** 74-79.