

Case Report

TUBERCULOSIS OF MASTOID BONE–CASE REPORT

Y.U. Kelgaonkar, Shaila Bangad, Sham S. Somani, Surabhi Chopra and Sachin B Ingle

Department of ENT and Pathology, MIMSR Medical College, Latur, Maharashtra

**Author for Correspondence*

ABSTRACT

Primary tuberculosis of the ear has rarely been reported. Tuberculosis of skull bones is very rare with just few cases reported in literatures till date. Tuberculosis of the middle ear is characterized by painless otorrhoea, multiple tympanic perforations, abundant granulation tissue, bone necrosis and severe hearing loss. Tuberculous otitis media should always be considered in differential diagnosis of chronic middle ear discharge that does not respond to usual treatment. Otogenic complication as facial palsy and sensorineural hearing loss were more frequent in tuberculous otitis patients, than in cholesteatoma. Also, fistulas of the labyrinth and facial canal bone destruction were also more frequent in tuberculous otitis than in cholesteatoma. A larger extent of temporal bone destruction was noticed on CT scans of the temporal bone in half of the patients with tuberculous otitis. Histopathological features of TOM are not a typically formed granuloma. PPD testing is not a reliable diagnostic procedure. We present a case of a 55 year old female patient presenting with tuberculous otitis media due to the rarity of its occurrence.

CASES

A 55 year old female was hospitalized with complaints of discharge from right ear for 6 months, swelling in front and behind the right ear for 1 month, and pus discharging sinus behind the ear for 15 days. General examination revealed average nutrition and build and enlarged, matted and nontender cervical lymph nodes on right side of neck (8 cm X 5 cm). Local examination showed one fluctuant, nontender swelling (2.5 cm) in front of the right ear and the post-auricular area showed 3 swellings (about 2 cms each) just behind the retro-auricular sulcus. The upper and lower swellings were tender and fluctuant. The middle swelling had a pus discharging sinus, which was fixed to the underlying bone. External ear canal revealed exuberant pale granulation tissue completely blocking the view of tympanic membrane. Investigations showed : Hb 12 g%, TLC 8,9007 cu mm; DLC P-60, L-34, E-4, M-2; ESR 16 mm for first hour; random blood sugar 80 mg% and urine- normal. Mantoux test was positive. CT scan of Rt. mastoid showed evidence of bony destruction (Figure 1). X-ray chest showed an almond sized radio-opaque

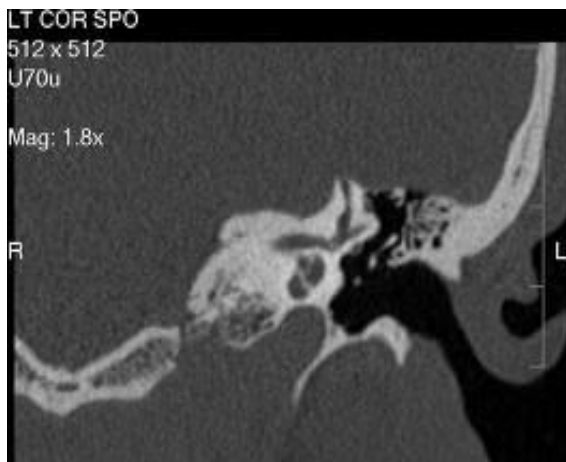

Figure 1 : CT scan image of mastoid bone shadow in right hilum with increased broncho-vascular markings. Pus aspirated from pre-auricular

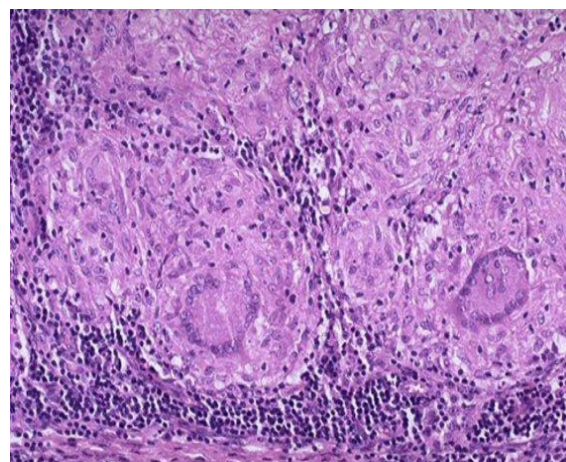


Figure 2 : Histopathology image

Case Report

swelling was found to be negative for AFB twice by smear examination. Audiometry revealed moderate to severe perceptive hearing loss on the right side.

Right mastoid was explored under general anaesthesia through a post-aural incision. Suppurating lymph nodes were found under the three post-aural swellings. The cortex of the mastoid bone was found eroded over the mastoid antrum and tip, through which pale granulations were protruding. The posterior bony canal wall, lateral semi-circular canal and sinus plates were found eroded; however, the dural plate was intact. After removing the granulation tissue, the tympanic membrane was found to be having a 2 mm size central perforation. Modified radical mastoidectomy was done and the post-aural wound was sutured. One of the matted cervical lymph nodes was removed for histological examination (Figure 2). The biopsy report showed evidence of tuberculosis and the patient was put on short course antituberculosis treatment, one week after surgery. Removal of stitches on the seventh day revealed a gaping wound. The wound and mastoid cavity were dressed daily and healed in one month. After three months, the mastoid cavity was well epithelized and tympanic perforation had healed up. Audiometry done at the end of 9 months did not reveal any improvement in hearing.

DISCUSSION

The true prevalence of tuberculosis of middle ear and mastoid is not known because of highly selected material in various reports but is estimated to be around 1% of patients with ear complaints. At our hospital during the last 10 years only 2 (0.6%) out of 312 mastoid surgery cases showed definite evidence of tuberculosis. Tuberculous otitis media in adults occurs most commonly in association with advanced pulmonary tuberculosis, but in children it may occur in isolation (Ash 1968). The mastoid involvement is thought to be either through the eustachian tube or haematogenous in origin. Lederer recognized 3 pathological types of tuberculous mastoid : (i) miliary form, starting as tubercles in submucosa of middle ear and later involving the periosteum and bone, (ii) granulating type, as circumscribed granuloma or proliferate lesion involving bone, and (iii) caseous form, showing tubercles, caseation and sometimes entire bone necrosis and sequestration(Lederer 1973).

It would appear from the literature that clinical presentation of tuberculous otitis media has changed over the last three or four decades (Shenoi 1987). Multiple perforations of the drum-head which were characteristic features are no longer seen The typical feature of the disease now is a profuse, painless discharge from the ear which fails to respond to both topical and systemic antibiotic therapy. There is often a disproportionate hearing loss compared with clinical findings and the majority have pale exuberant granulations. Complications are significantly higher (sensorial hearing loss, labyrinthitis, facial paralysis) compared with non-cholesteatomatous or simple type of chronic suppurative otitis media (Wallner 1993).

Diagnosis is facilitated if there is a high index of suspicion and, in particular, presence of tuberculosis elsewhere (Lucente 1998). Since culture is usually time consuming, diagnosis is often established by histology of the granulation tissue, which may need to be repeated. Along with the modern anti-tuberculosis chemotherapy, surgery may also be required to remove sequestra and allow adequate drainage (Glover 2001).

REFERENCES

- Ash, IE *Otolaryngology*, edited by Maloney, WH Harper & Row, London (1968). Vol 1 chapter 4 33.
Lederer, FL *Otolaryngology*, edited by Paparella & Shumrick WB Saunders Company, Philadelphia (1973). Vol 2.
Shenoi, PM *Scott-Browns Otolaryngology*, edited by JB Booth Butterworths & Company Limited London (1987). 5th Edn Vol HI 232-234.
Wallner (1993). LJ Tuberculous otitis media. *The Laryngoscope* 63(2) 1058-1067.
Lucente, FE, Tobias, GW, Pansier, SC and Som, PM (1998). Tuberculous otitis media. *The Laryngoscope* 88(2) 1107-1110.

Case Report

Plester, D, Pusalkar, A and Steinbach, E (1990). Middle ear tuberculosis. *Journal of Laryngology and Otology* **94**(4) 1415-1521.

Glover, SC, Tranter, RMD and Innas, JA (2001). Tuberculous otitis media a reminder. *Journal of Laryngology and Otology* **95**(3) 12-21.