

Case Report

A RARE PRESENTATION OF KLIPPEL TRENAUNAY SYNDROME: A CASE REPORT

Singh H, Tanwar V, Kalra A, Arora S, Govil N and Ruchi S Dhankar

Department of Medicine, PGIMS Rohtak (India)

**Author for Correspondence*

ABSTRACT

Klippel Trénaunay syndrome is a rare congenital complex disorder characterized by the triad of vascular malformations, venous varicosities, and bone and soft-tissue hypertrophy. Venous varicosities are generally superficial affecting lower limbs but may rarely found in visceral organs including spleen, liver, colon and bladder. Patients with KTS are at increased risk of potential complications, including cellulitis, lymph seepage, gangrene, skin breakdown, thrombophlebitis, and internal and superficial haemorrhages. We here present a case of Klippel-Trénaunay syndrome associated with portal hypertension.

Keywords: *Klippel-Trénaunay Syndrome, Soft Tissue Hypertrophy, Venous Varicosities, Port-Wine Stain*

INTRODUCTION

Klippel trenaunay syndrome is a rare congenital medical condition in which blood vessels and/or lymph vessels fail to form properly.

It is also known as Klippel Trenaunay Weber syndrome, angio-osteohypertrophy syndrome and hemangiectatic hypertrophy (James *et al.*, 2005). The three main features are nevus flammeus (port-wine stain), venous and lymphatic malformations, and soft tissue hypertrophy of the affected limb (James *et al.*, 2005).

Herein we report a case of KTS with an uncommon presentation of portal hypertension.

CASES

Case Presentation

A 32 year female not a known case of any chronic illness presented with complains of pain abdomen (in right hypochondrium) for 2 years.

There was no history of nausea/ vomiting/ hematemesis/ melaena and yellowish discoloration of sclera.

On clinical examination, there were multiple hemangiomas (port wine stains) all over body but were present mostly over face, neck and upper trunk (Figure 1).

There was obvious soft issue and bony hypertrophy of left half of face, left upper limb and right lower limb (Figure 1, 2).

USG abdomen showed normal liver with a dilated intrahepatic abnormal venous channel in right lobe along with moderate splenomegaly.

Triple phase CECT was performed that showed normal sized liver with multiple dilated venous malformations involving IVC and hepatic veins (Figure 3).

An abnormal venous channel was seen draining into IVC running along outer margin of right lobe of liver and communicating with hepatic veins.

Portal vein measured 18 mm at formation and moderate splenomegaly with multiple collaterals at splenic hilum. Upper g.i, endoscopy done revealed low grade esophageal varices.

Color Doppler for major limb vessels, renal vessels and neck vessels was reported normal.

So, keeping in mind, port wine stains, visceral venous malformations and soft tissue and bony hypertrophy, a diagnosis of Klippel treaunay syndrome with early complication in form of Portal Hypertension was entertained.

Patient was managed conservatively with beta blocker for PHTN, since invasive intervention was not feasible.

Patient was advised to come on regular follow up for progression (if any) of the presentation.

Case Report

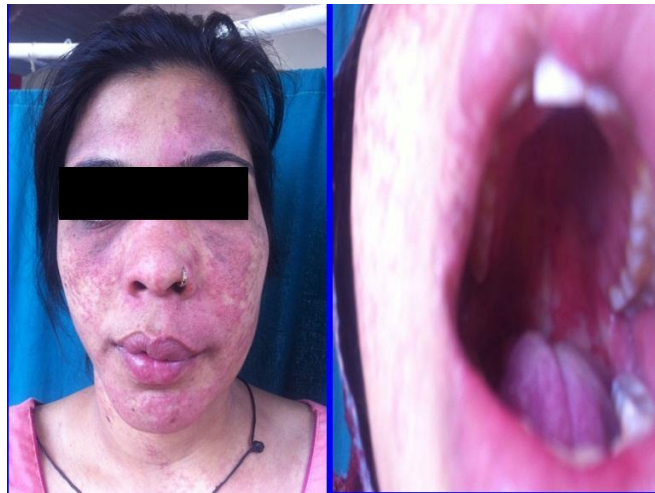

Figure 1: Port wine stains over face and oral cavity; left half of face was larger than right half of face

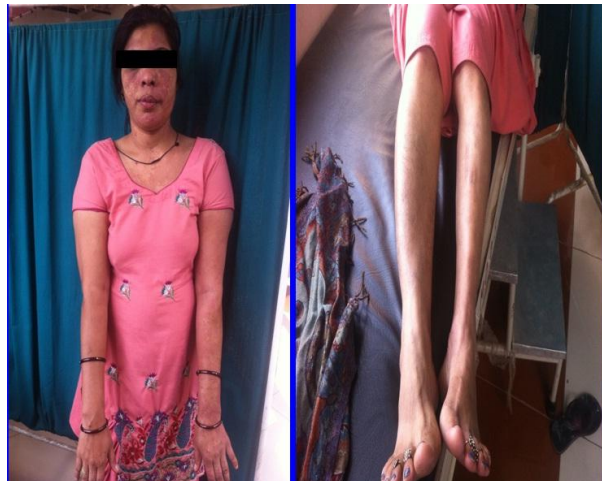

Figure 2: left upper limb was more bulky; right lower limb was more bulky and larger than the left lower limb.

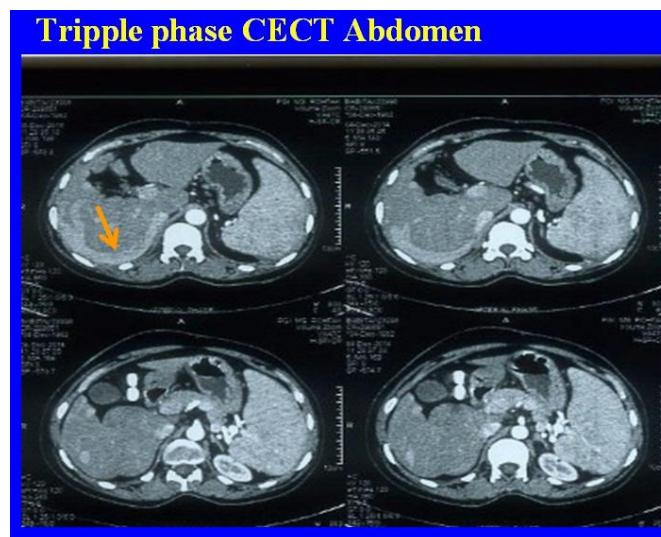


Figure 3: CECT abdomen showing an abnormal dilated venous channel running along with outer margin of right lobe of liver and draining into Inferior vena cava (see arrow)

Case Report

DISCUSSION

KlippelTrenaunay syndrome (KTS) is a complex developmental disorder described first by Klippel & Trenaunay in 1900 (James *et al.*, 2005). Most cases of KTS are sporadic; the syndrome affects males and females equally, has no racial predilection, has overall incidence of 2-5/100,000 and manifests at birth or during childhood (Jacob *et al.*, 1998). Incidence and genetic predisposition of this rare disease has not been established. The etiology of KTS is unknown, however, several theories exist. Bliznak and Staple suggested intrauterine damage to the sympathetic ganglia or intermediolateral tract leading to dilated microscopic arteriovenous anastomoses as the cause (Bliznak and Staple, 1974). Baskerville *et al.*, suggested that a mesodermal defect during fetal development causes maintenance of microscopic arteriovenous communications (Baskerville *et al.*, 1985). McGrory and Amadio believe that an underlying mixed mesodermal and ectodermal dysplasia is likely responsible for the development of KTS (McGrory and Amadio, 1993).

The classic clinical triad includes capillary malformations (port wine stain), a usually longer and larger extremity because of soft tissue and bone hypertrophy, and atypical venous malformations. The diagnosis of KTS can be made when any two of the three features are present (Jacob *et al.*, 1998). Capillary malformations are the most common cutaneous manifestation of KTS (Jacob *et al.*, 1998). Typically, capillary malformations involve the enlarged limb, although skin changes may be seen on any part of the body. The lower limb is the site of malformations in approximately 95% of patients. When found on the trunk, the malformations rarely cross the midline (AL-Salman, 1997). If large enough, the cutaneous lesions may sequester platelets, possibly leading to Kasabach-Merritt syndrome, a type of consumptive coagulopathy (Ghahremani *et al.*, 1976). Venous malformations are mostly superficial, but may involve muscle, bone or rarely visceral organs, including the spleen, liver, pleura, bladder or colon. Vascular malformations involving the gastrointestinal and genitourinary tracts have been reported and can be a significant source of morbidity and even mortality. The most frequently reported sites of gastrointestinal involvement in these patients are the distal colon and rectum with bleeding being the most common symptom. Hypertrophy is the most variable of the three classic features of KTS (Jacob *et al.*, 1998). Enlargement of the extremity consists of bone elongation, circumferential soft-tissue hypertrophy, or both (Jacob *et al.*, 1998; AL-Salman, 1997).

In a series of 252 patients at the Mayo Clinic, 63% of patients had all 3 features and 37% had 2 of the 3 features. Port-wine stain was seen in 98% of patients, varicosities or venous malformations in 72%, and limb hypertrophy in 67%. Atypical veins, including lateral veins and persistent sciatic vein, were present in 72% of patients. In another study of 144 patients, 95% had a cutaneous vascular malformation, 93% had soft tissue and bone hypertrophy, 76% had varicosities, and 71% had involvement limited to one extremity (AL-Salman, 1997).

Complications are most often related to the underlying vascular pathological condition. Patients with KTS are at increased risk of potential complications, including cellulitis, lymph seepage, gangrene, skin breakdown, thrombophlebitis, and internal and superficial haemorrhages (Jacob *et al.*, 1998). The common differential diagnoses of KTS are Proteus Syndrome, Sturge Weber Syndrome and Maffucci syndrome. Parkes Weber syndrome (i.e. arteriovenous malformation in addition to other abnormalities of KTS).

Imaging plays an important role in the diagnosis and ongoing evaluation of KTS. CT of the abdomen and pelvis provides a simple, non-invasive means of assessing visceral vascular malformations. Magnetic resonance (MR) imaging is performed to assess the soft-tissue extent of vascular malformations in patients with KTS. There is no curative therapy. Management requires a multidisciplinary and individualised approach, aiming to ameliorate the patient's symptoms and correct the consequences of limb-length discrepancy (Gloviczki and Driscoll, 2007).

Conclusion

We report this case because of its rarity as venous malformations in visceral organs like liver is very uncommon in patients of KTS. Regular follow up is necessary in these patients to look after the life threatening complications.

Case Report

Conflict of Interest: The authors declare that there is no conflict of interest regarding the publication of this paper.

REFERENCES

- AL-Salman MM (1997).** Klippel-Trénaunay syndrome: clinical features, complications, and management. *Surgery Today* **27** 735–740.
- Baskerville PA, Ackroyd JS and Browse NL (1985).** The etiology of the Klippel-Trenaunay syndrome. *Annals of Surgery* **202**(5) 624-7.
- Bliznak J and Staple TW (1974).** Radiology of angiodysplasias of the limb. *Radiology* **110**(1) 35-44.
- Ghahremani GG, Kangarloo H, Volberg F, Meyers MA (1976).** Diffuse cavernous hemangioma of the colon in the Klippel-Tre´naunay syndrome. *Radiology* **118** 673–678.
- Gloviczki P, Driscoll DJ (2007).** Klippel-Trenaunay syndrome: current management. *Phlebology* **22**(6) 291-8.
- Jacob AG, Driscoll DJ, Shaughnessy WJ, Stanson AW, Clay RP, Gloviczki P (1998).** Klippel-Tre´naunay syndrome: spectrum and management. *Mayo Clinic Proceedings* **73** 28–36.
- James William, Berger Timothy and Elston Dirk (2005).** *Andrews' Diseases of the Skin: Clinical Dermatology*, 10th edition, (Saunders) 58.
- McGrory BJ and Amadio PC (1993).** Klippel-Trenaunay syndrome: orthopaedic considerations. *Orthopedic Reviews* **2**(1) 41-50.