

## **VARIATION IN THE BRANCHING PATTERN OF FIRST PART OF AXILLARY ARTERY**

**\*Jaishree H<sup>1</sup> and Ashwini H<sup>2</sup>**

<sup>1</sup>*Department of Anatomy, ESI Medical College, Gulbarga, Karnataka*

<sup>2</sup>*Department of Anatomy, Gulbarga Institute of Medical Sciences, Gulbarga, Karnataka*

*\*Author for Correspondence*

### **ABSTRACT**

During routine dissection of undergraduate students, unilateral variation in the branching pattern of first part of right axillary artery in a male cadaver of approximately 60 year old was seen. From the first part two branches were arising i.e. superior thoracic artery and suprascapular artery, from the second part two branches thoracoacromial artery and lateral thoracic artery and from the third part subscapular artery, anterior circumflex humeral and posterior circumflex artery were seen. There was no variation in first part of left axillary artery. Knowledge of such variation is useful in performing invasive diagnostic and interventional procedures in cardiovascular diseases.

**Keywords:** *Axillary Artery, Two Branches, Suprascapular Artery*

### **INTRODUCTION**

The axillary artery is a continuation of the subclavian artery from outer border of the first rib to lower border of teres major muscle that continues further distally as brachial artery. It is divided into three parts by the pectoralis minor muscle.

The first part is proximal, second part is posterior and third part is distal to pectoralis minor. It is conventionally described as giving of six branches. The first part of axillary artery has one branch, the superior thoracic artery which runs anteromedially above the medial border of pectoralis minor and supplies thoracic wall. The second part of axillary artery has two branches, thoracoacromial artery and lateral thoracic artery.

The thoracoacromial artery is a short branch which runs along the medial border of pectoralis minor and divides into four branches- pectoral, deltoid, acromial and clavicular. The lateral thoracic artery runs along the lateral border of pectoralis minor and supplies the thoracic wall. The third part of axillary artery has three branches, anterior circumflex humeral, posterior circumflex humeral and subscapular artery.

The subscapular artery is the largest one which runs along the lateral border of scapula and approximately 4cm from its origin it divides into circumflex scapular and thoracodorsal arteries. The anterior and posterior circumflex scapular arteries surround the surgical neck of humerus (Standring, 2008).

### **CASES**

During routine dissection of undergraduate students in department of anatomy BRIMS, Bidar, we found a variation in the branching pattern of first part of right axillary artery in a male cadaver of approximately 60 year old.

The axillary artery on right side was giving 2 branches i.e. superior thoracic artery and suprascapular artery. The superior thoracic artery was arising from medial side of first part of axillary artery and supplied superior thoracic wall.

The suprascapular artery was arising from lateral side of first part of axillary artery, the suprascapular artery passed upwards, backwards and below lateral one third of the clavicle. The suprascapular artery along with suprascapular nerve passed beneath the transverse scapular ligament supplied supraspinatus and infraspinatus. The suprascapular vein passed above the ligament. The second and third part of axillary artery showed normal branching pattern. There was no variation in branching pattern of first part of left axillary artery.

## Case Report

### DISCUSSION

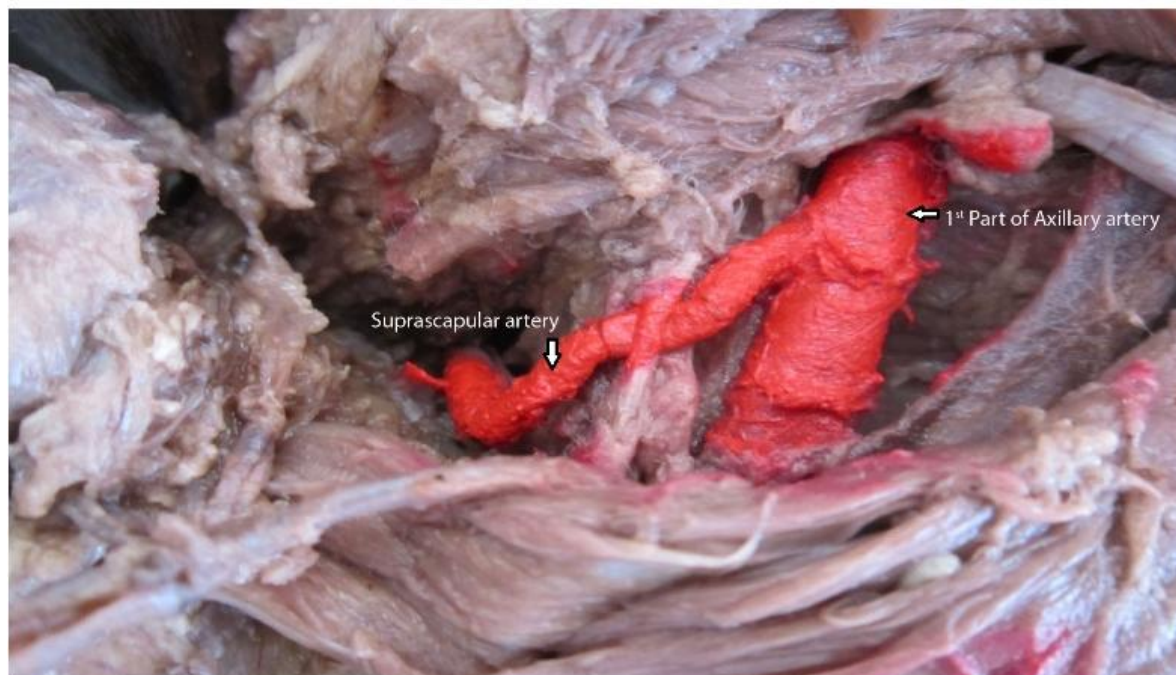
In the present case the first part of right axillary artery is giving 2 branches i. e. superior thoracic artery and suprascapular artery. None of the study showed variation in branching pattern of first part of axillary artery.

Ranjana *et al.*, reported the variation in second part of the axillary artery. It gave three branches – thoracoacromial artery, a collateral branch and subscapular artery (Verma *et al.*, 2014).

Sarkar *et al.*, (2014) reported variation in branching pattern of third part of axillary artery. The branches are anterior circumflex humeral artery and a common trunk gave four branches namely muscular branch, lateral thoracic artery, subscapular artery and posterior circumflex humeral artery (Sarkar *et al.*, 2014). Karambelkar *et al.*, (2011) in their study reported that there was no variation in branching pattern of first part of axillary artery. In 6.66 % of cases subscapular artery is originating from the second part. In 20% of cases there was a common stem for anterior and posterior circumflex humeral arteries and in 8.33% cases subscapular and posterior circumflex humeral arteries have common stem (Karambelkar *et al.*, 2011).

### Conclusion

Knowledge of variation in branching pattern of first part of axillary artery is of clinical importance, as axilla is the frequent site of growth, trauma and abscess requiring surgical interventions and also while performing axillary lymph node dissection as a part of cancer operations particularly involving breast (Anson *et al.*, 1991). Accurate knowledge of the normal and variant arterial pattern of the human upper extremities is important both for reparative surgery and for angiography (Yoshinaga *et al.*,). Knowledge of the normal and variant arterial anatomy of the axillary artery is important while carrying out coronary bypass and other reconstructive surgery (Cavdar *et al.*, 2000).



**Figure 1: Showing suprascapular artery arising from first part of axillary artery**

### REFERENCES

- Anson BJ, Wright RR and Wolfer JA (1991). Blood supply of the mammary gland, *Surgery Gynecology and Obstetrics* **69** 468-473.  
Cavdar S, Zeybek A and Bayramicli M (2000). Rare variation of the axillary artery, *Clinical Anatomy* **13** 66-68.

**Case Report**

**Karambelkar RR and Shewale AD et al., (2011).** Variations in Branching Pattern of Axillary Artery and its Clinical Significance, *Anatomica Karnataka* **5**(2) 47-51.

**Sarkar S and Kundu B et al., (2014).** Variation of branching pattern of axillary artery, *International Journal of Anatomical Variations* **7** 27–29.

**Standring S (2008).** *Gray's Anatomy*, 40th edition, The anatomical basis of clinical practice, New York Churchill Livingstone 815.

**Verma R and Mishra S et al., (2014).** Unilateral variation in the branching pattern of axillary artery: a cadaveric study, *International Journal of Anatomy and Research* **2**(1) 292-94.

**Yoshinaga K and Kodama K et al., (No Date).** A rare variation in the branching pattern of the axillary artery, *Indian Journal of Plastic Surgery* **39** 222-223.