

**Research Article**

## **OUTCOME FOLLOWING SACROSPINOUS LIGAMENT FIXATION FOR ADVANCED UTEROVAGINAL PROLAPSE**

**\*Chandrashekar K, Ramaraju H.E. and Nataraj K.C.**

*Department of Obstetrics and Gynecology, JJM Medical college, Davangere, Karnataka*

*\*Author for Correspondence*

### **ABSTRACT**

Objective behind the study was to assess the results of Sacrospinous ligament fixation for vault suspension during vaginal hysterectomy. 44 women with genital prolapse were subjected to sacrospinous colpopexy during vaginal hysterectomy and repair from October 2009 to July 2011 with 2 year of follow up. The intra-operative complication encountered was hemorrhage in one case (3.3%). The postoperative complications were fever in 3 (9%) cases, urinary tract infection in 3 (9%), Buttock pain in 3 (9%) and wound infection in 1 (3%) case. Complications were foreign body granulation tissue at vault noted at 3 month followup and recurrence of prolapse i.e., 1<sup>o</sup> cystocele in 1 (3%) case and 1<sup>o</sup> rectocele in 1 (3%) case noted at 2 year of followup. Sacrospinous colpopexy is a safe, efficacious and simple procedure which is indicated in severe degree of prolapse with significant loss of vaginal supports.

**Keyword:** *Sacrospinous Colpopexy, Vault Prolapse, Genital Prolapse*

### **INTRODUCTION**

From the turn of the century, a variety of surgical techniques has been described in an attempt to correct satisfactorily an eversion of the vagina after hysterectomy. Until recently, no one technique that preserves sexual functions has been universally successful in the treatment of vaginal vault prolapse. Therefore many different approaches have been published.

In the last several years, suspension of the prolapsed vaginal vault to the sacrospinous ligament has gained popularity in this country having previously been described in the European literature.

Sacrospinous ligament fixation is most widely published procedures and has a good result with success rate exceeding 90% (Malti *et al.*, 2006). This procedure was originally developed for therapeutic purpose only, as a method of treating patient with post hysterectomy vaginal vault prolapse. More recently Nichols included its prophylactic use at vaginal hysterectomy in patients with advanced uterovaginal prolapse (grade III Uterovaginal prolapse and procidentia) cases (Randall and Nichols, 1971).

In our study, we have done prophylactic fixation of vaginal vault to sacrospinous ligament at the time of vaginal hysterectomy in case of advanced uterovaginal prolapse with meticulous follow-up of these case for about 24 months.

### **MATERIALS AND METHODS**

Cases for the present study were taken from Chigateri General Hospital, Women and Children Hospital and Bapuji Hospital from the period of October 2009 to July 2011. Total number of cases during the period were 30. These patients were admitted to gynaec wards of the above hospital & were scheduled for vaginal hysterectomy with sacrospinous ligament fixation. The following information were collected i.e., patients age, detailed clinical history which included patient's complaints, duration and obstetric history any significant past, family and personal history.

#### **Inclusion Criteria:**

- Grade III uterovaginal prolapse
- Procidentia

#### **Exclusion Criteria:**

- Grade I and II uterovaginal prolapse
- Vault prolapse.

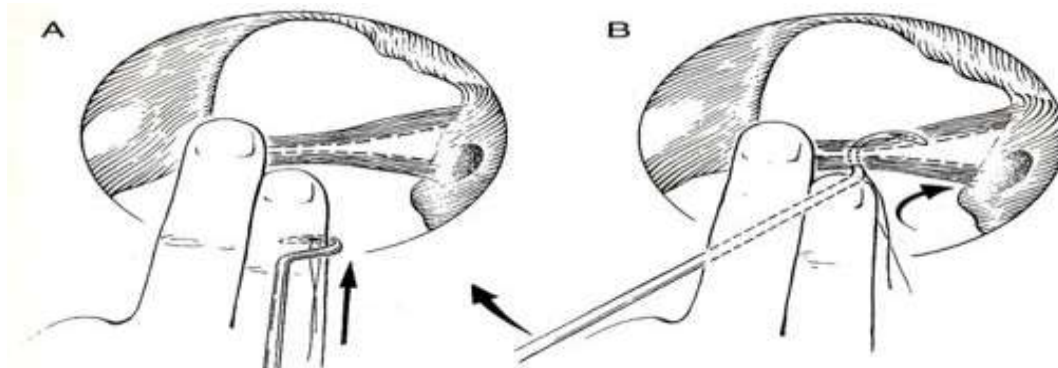
## **Research Article**

### **Procedure:**

With the patient in dorsal lithotomy position and the procedure begins vaginal hysterectomy with correction of all other vaginal defects, a V-shaped incision is made in the perineum by incision of the perineal skin and posterior vagina. By blunt dissection approached to rectal pillar which is medial to levator ani muscle.

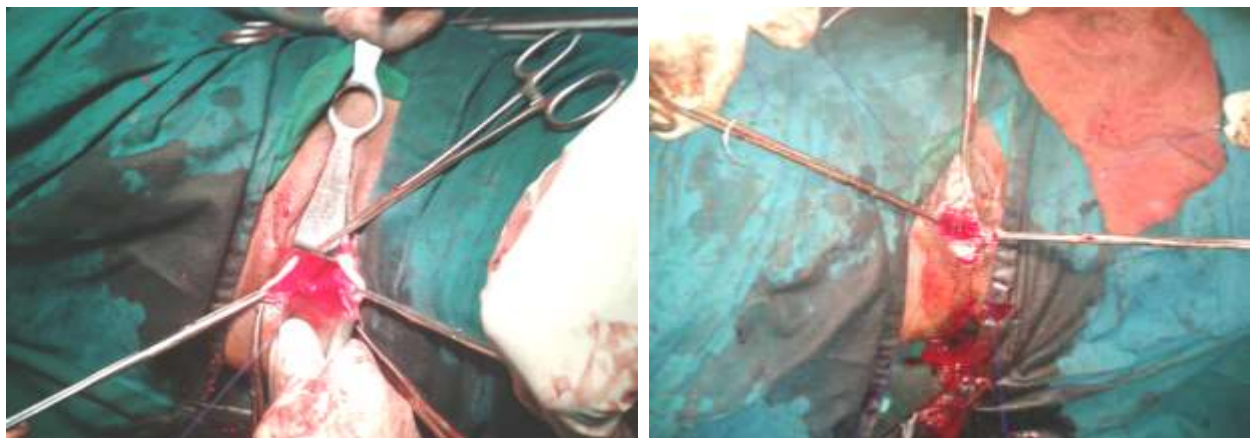
When the rectum has been carefully displaced by an appropriate retractor to the patient's left, the right ischial spine is carefully palpated.

At a point 2 to 3 cm medial to the ischial spine, the sacrospinous ligamentcoccygeus muscle complex is grasped by the tip of a long allie and confirmed with movement of the body when traction is given by the allie. With Deschampus ligature carrier contains proline suture no1 is passed through ligament.



**Figure: Deschampus ligature carrier is passed through ligament**

At the same time, the handle of the ligature carrier is moved through a larger clockwise arc beneath the palm of the left and to permit vertical penetration of the ligament. If a gentle tug to the suture, which has been grasped by a hook, actually moves the patient a small degree on the table this indicates proper placement of the suture through the substance of the sacrospinous ligament.



**Proline suture material passed through sacrospinous ligament**  
**Proline suture material passed through the vaginal vault**

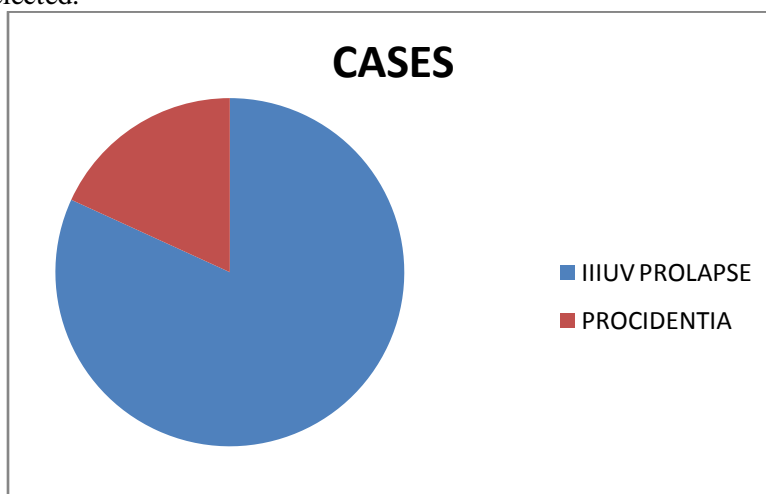
These permanent stitches should be placed submucosally in the vagina so that they are buried in the fibromuscular wall. The long colpexy stitches are then held in hemostats to be tied later in the operation. At the end of the operation, rectal examination confirms the integrity of the rectum and a vaginal pack is left to stop any bleeding from pararectal space. At the end of surgery, adequate vault suspension was ensured and vagina was packed for 24hours. They were followed up after 6<sup>th</sup> weeks, 6<sup>th</sup> month, 1<sup>st</sup> years and 2<sup>nd</sup> year.

## Research Article

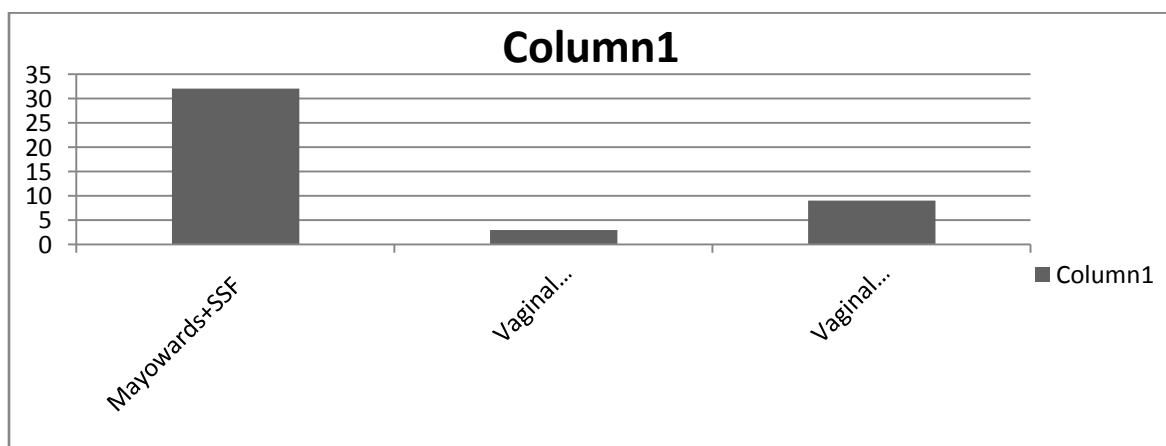
### RESULTS

In our study, revealed that 63% are in grand multipara group of which 40% are in para 4. 13% of patients in premenopausal age group developed uterovaginal prolapse. 50% patients presented after 5 years of menopause which reflected increasing rate of prolapse are seen among patients with higher post menopausal duration.

In this present study, 81% of patients with grade III uterovaginal prolapse and remaining 19% with procidentia were selected.



83.3% of patients underwent Mayowards procedure along with sacrospinous fixation one patient had vaginal hysterectomy with anterior colporrhaphy was surgical procedure in this present study.



Mean time taken for vaginal hysterectomy with site specific repair is 2 hours whereas sacrospinous ligament fixation was done in mean time of 20 min, whole procedure was carried out within range of 1.6 hour to 3 hours.

Mean blood loss per surgical procedure ranged from 280-750 ml with mean blood loss being 345ml. Out of 44 study population, 12 patients received 1 pint of blood (to compare loss of nearly 400ml of blood), where as one patient was transfused with 2 pint of blood to compensate nearly 650ml of blood loss.

For all patient who underwent vaginal hysterectomy with Sacrospinous ligament fixation preoperatively pelvic organ prolapse quantification (POP Q) done immediately after operation, again assessed by POP-Q. There is considerable change in the outcome. Almost vaginal length of 6 cm is retained after surgery.

## Research Article

### Comparision of POP-Q before and after the procedure

Pop Q points	Pre op Pop Q in cm	Post op Pop Q in cm
Aa	+ 1.5	- 2.5
Ba	+ 4.5	- 4
Ap	+1	- 2
Bp	+ 3	- 3.8
D	-1	- 6

Out of 44 study group 5 patient suffered febrile illness in which 3 patients were diagnosed to have urinary tract infection. 3 patients presented with complaint of buttock pain who underwent surgical procedure prolonged for more than 3 hours were treated injection cobalamine for 5 days. Post operative wound infection was found in one patient who was treated with higher antibiotics for five days.

With a total of 2years followup reflected that, out of 44 patients 41 did not have any complaints which accounts to 90%, one patient had first degree cytocele, one patient had first degree rectocele and one patient had granuloma.

## DISCUSSION

The relatively large number of women presenting to our hospital with advanced utero vaginal prolapse over a period of 24 months suggests it is a significant and perhaps under rated problem. When treating this condition the vaginal surgeon needs to appreciate the importance of recreating effective support for the vault often vaginal hysterectomy.

In our study, out of 44, 37 patients are grade III uterovaginal prolapse and 7 are procidentia.

### Table shows the number of patients and mean followup.

Author No. of patient	Mean	followup
Bensen <i>et al.</i> , (1996)	42	30 months
Sze <i>et al.</i> , (1997)	75	24 months
Maher <i>et al.</i> , (2004)	48	22 months
Calombo <i>et al.</i> , (2009)	62	83 months
Dalala Malti (2006)	35	6 months (6-18)

When comparing complications with Cruikshank and Dalal Malti, in our study fever was most common and didn't come across for wound infection or stress urinary incontinence when compare to Cruikshank. But 3 patients had sciatica due to prolonged surgery, all 3 are recovered.

Complications	Malti <i>et al.</i> , (2006) (n=35)	Cruikshank (1991) (n=48)	Present study (n= 44)
Fever	05	04	5
Buttock pain	-	-	3
UTI	04	03	3
Wound infection	01	-	-
Retention of urine	01	-	-
SUI	-	02	-
Granuloma	-	-	1

## Conclusion

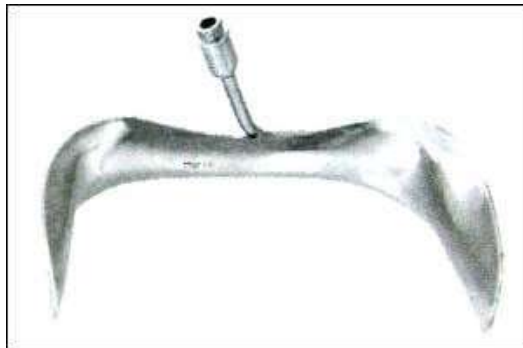The results of numerous studies, as well as the results of our study, showed that transvaginal sacrospinous colpopexy could be performed along with vaginal hysterectomy and the anterior and posterior vaginal wall repair in the patients with uterovaginal prolapse because of its high success in the prevention of

## Research Article

postoperative vaginal vault prolapse and the low intra-and postoperative complication rates. This operative technique is successful in prevention of repeated vaginal vault prolapse. The vaginal route confirms an advantage by posing less anaesthetic risk and allowing simultaneous repair of other defects. If performed meticulously complications are minimal. Operative time, blood loss and hospital stay are minimally increased.

### **Instruments used in sacrospinous ligament fixation are**


- |                                       |                               |
|---------------------------------------|-------------------------------|
| 1. Deschampus ligature carrier        | 2. Nerve hook                 |
| 3. Breisky-Navratil vaginal retractor | 4. Illuminated light speculum |



**Illuminated speculum**



**Breisky-Navratil vaginal retractor**



**Deschamps ligature carrier**

## REFERENCES

- Argirovic R and Likic-Ladevic I (2005).** Application of transvaginal Sacrospinous colpopexy in the treatment of pelvic organs prolapse. *Vojnosanitetski Pregled Military-medical and Pharmaceutical Review* **62**(9) 637-643.
- Dalal Malti, Verma Ragini N, Shah tejal S, Garg Heena C (2006).** Sacrospinous colpopexy for vault suspension during vaginal hys terectomy with repair for genital prolapse. *The Journal of Obstetrics and Gynecology of India* **56**(3) 247-249.
- Jones Christopher M, Kenneth D and Harrigill Keith (2001).** Unilateral and bilateral sacrospinous ligament fixation for pelvic prolapse; A non-concurrent cohort comparison. *Journal of Pelvic Surgery* **7**(1) 27-33.
- Sauer HA and Klutke CG (1995).** Transvaginal sacrospinous ligament fixation for treatment of vaginal prolapse. *Journal of Urology* **154**(3) 1008-1012.
- Kari Nieminen and Pentti K Heinonen (2000).** Transvaginal Sacrospinous Ligament Fixation with or Without Concurrent Vaginal Hysterectomy: A Comparison of Operative Morbidity. *Journal of Gynecologic Surgery* **16**(3) 101.
- Kari Nieminen and Pentti K Heinonen (2001).** Sacrospinous ligament fixation for massive genital prolapse in women over 80 years. *British Journal of Obstetrics and Gynaecology* **108**(8) 817-821.
- Mario Colombo and Rodolfo Milani (1998).** Sacrospinous ligament fixation and modified McCall culdoplasty vaginal hysterectomy for advanced uterovaginal prolapse. *American Journal of Obstetrics & Gynecology* **179** 13-20.
- Morley George W (1988).** Sacrospinous ligament fixation of \r eversion of vagina. *American Journal of Obstetrics & Gynecology* **158**(4) 872-881.

**Research Article**

**Randall CL and Nichols DH (1971).** Surgical treatment of vaginal inversion. *Obstetrics & Gynecology* **38**(3) 327-332.

**Segal JL, Vassallo BJ and Kleeman SD et al., (2004).** Paravaginal defects: prevalence and accuracy of preoperative detection. *International Urogynecology Journal* **15** 378–383.