

Case Report

AN UNIQUE COCOON IN THE ABDOMEN

Narmadha, *Jamila hameed, Geetha and Madhumidha

Department of Obstetrics and Gynaecology, Vinayaka Mission's Medical College and Hospitals-Karaikal

**Author for Correspondence*

ABSTRACT

Abdominal cocoon is a rare finding. The exact etiology is not known. Usually present as an acute or sub acute intestinal obstruction. Mostly affecting females of reproductive age in tropical and subtropical countries. Most of the times, it is diagnosed post-operatively since preoperative diagnosis is a challenging task. We came across a lady aged 48-years-old who had a submucous fibroid and got admitted for total abdominal hysterectomy with bilateral salpingoophorectomy for profuse bleeding per-vaginum for the past 1-year. She had no bowel complaints. Abdominal cocoon was diagnosed on opening the abdomen and the thin membrane covering the intestines got accidentally ruptured and serous like fluid came out and removal of the membranes with release of adhesions meticulously helped the patient. The histopathology showed signs of inflammation of the peritoneum and submucous fibroid uterus.

Keywords: *Abdominal Cocoon, Sclerosing Encapsulated Peritonitis, Submucous Fibroid, Total Abdominal Hysterectomy*

INTRODUCTION

Abdominal cocoon otherwise called sclerosing encapsulated peritonitis is of non-specific etiology can occur incidentally without any alarming signs and symptoms. Herein we find the small intestine wrapped up to any extent by fibro-collagenous peritoneum layer. The thickness maybe of varying size. Wherein most of the time it is a healthy bowel unless it is been strangulated: In that case the patient will be presenting with small bowel ileus. Here we are presenting an interesting case of abdominal cocoon which was incidentally found out in a patient who had a degenerating submucous fibroid planned for total abdominal hysterectomy with bilateral salpingoophorectomy. On opening the abdominal peritoneum, we found there was a fibrino-collagenous membrane covering the small bowel as a mass. This abdominal cocoon came as a surprise and this led us to go through the literature to find out the mystery. Abdominal cocoon can be found incidentally in an abdominal surgery wherein there was no previous intestinal complaints, such as pain in the abdomen with or without a mass as the exact etiology is not known. In the presence of flimsy adhesions only adhesiolysis is enough, but when there is a gangrene of the bowel, where surgical procedures are mandatory, the help of the surgeon should be sought. Surprise is always there waiting for us, as the abdomen is a temple of wonder.

CASES

A 48 year old lady P2L2 got admitted with the history of menorrhagia, metorrhagia and dysmenorrhoea for the past 1 year. Pain abdomen on and off. On examination Patient was pale and had two units of blood transfusion. Uterus was palpable of 14 weeks size. All investigations were normal. Ultrasound scan showed uterus of size 15.51×9.08×8.08 cm with submucous fibroid of size 7.0×6.9cm (figure 1 & figure 2). Patient was taken up for laparotomy on opening the abdomen, there was a thinned wall encapsulated mass which ruptured accidentally and 100 ml serous fluid came out. This was diagnosed on the table as abdominal cocoon (figure 3). Mild adhesiolysis done to separate the intestines. Then, the fibroid uterus which was enlarged to 14 weeks size with the submucous myoma came into view. Total abdominal hysterectomy with bilateral salpingoophorectomy was done as planned. The peritoneal fibrous tissue which was excised was sent for histopathological examination, showed inflammation. The submucous myoma which was sent was also confirmed by histopathologist (figure 4). The ovaries were normal.

Case Report

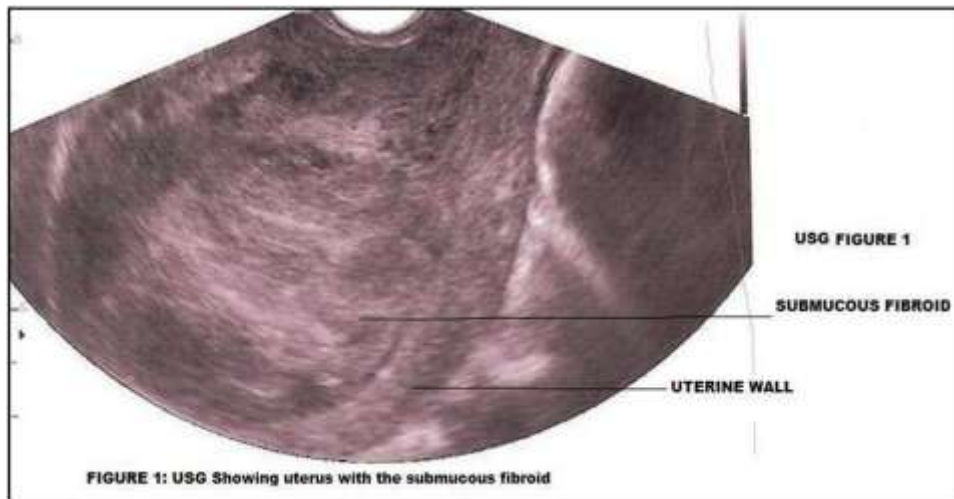


Figure 1: USG Showing uterus with the submucous fibroid

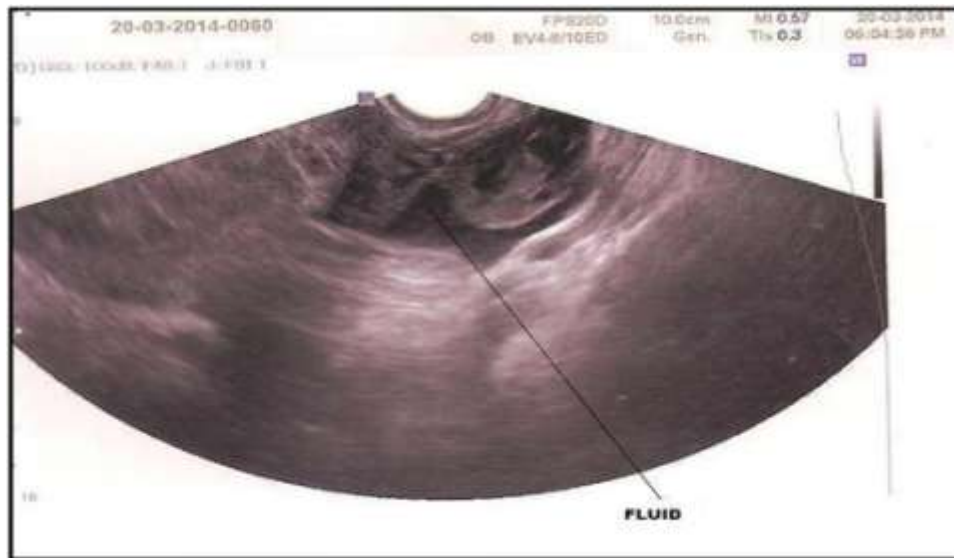


Figure 2: ULTRA SOUND SHOWING THE FLUID

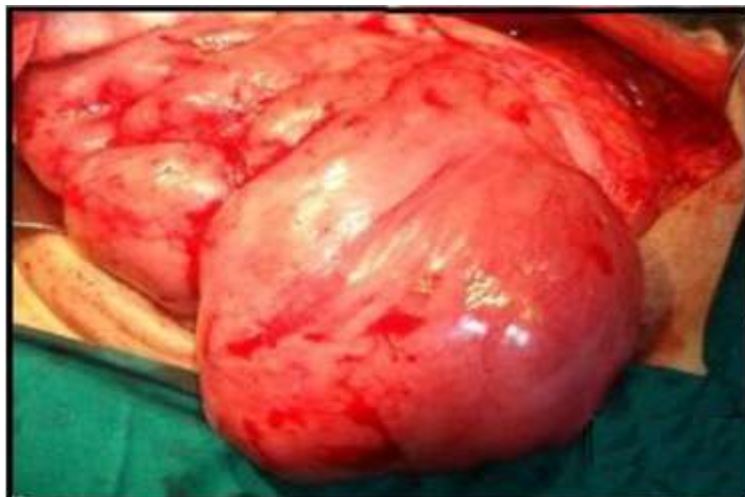

Figure 3: Showing Abdominal Cocoon

Case Report

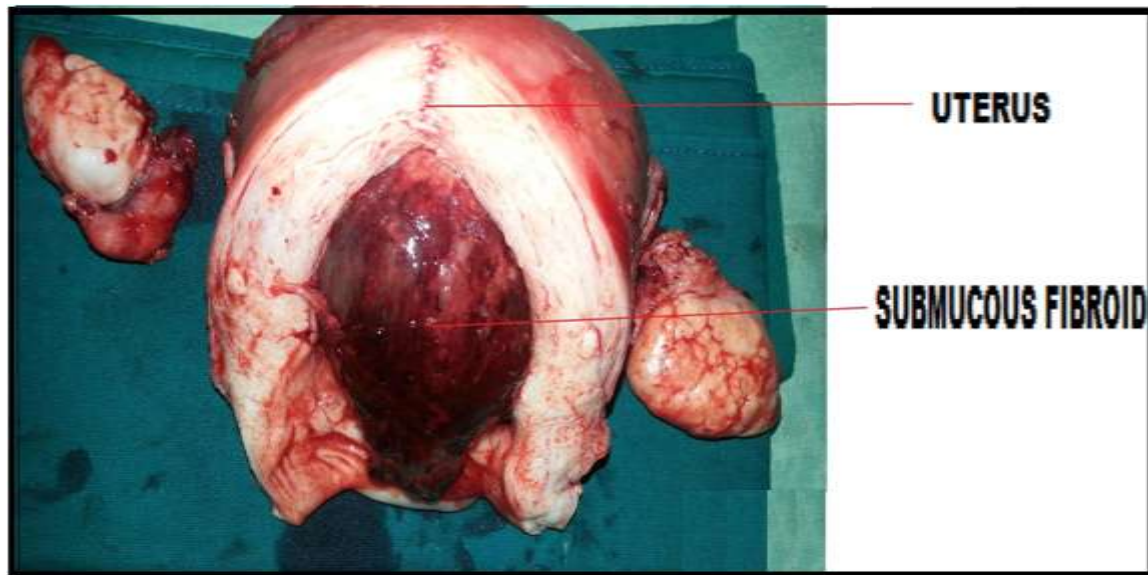


Figure 4: Showing uterus with submucous myoma

DISCUSSION

An interesting and incidental finding on opening the abdomen startled us with the appearance of a thin walled peritoneal encapsulated mass which is described as an abdominal cocoon (AC). The abdominal cocoon is a condition wherein a fibrinous membrane envelops the small intestine to various extents with or without giving rise to symptoms of small bowel ileus (Sayfan, 1979). This unusual case was first noticed by Foo in 1978. It was a retrograde infection in female. The review of literature shows only 35 such cases (Makam, 2008). Most of the cases wherein AC was diagnosed following small bowel obstruction (Ali, 2006). In our case we opened the abdomen for menorrhagia diagnosed as fibroid uterus, had no bowel symptoms, and like the other cases wherein AC is diagnosed the patient had pain abdomen, nausea, vomiting, altered bowel habits. The preoperative diagnosis is impossible and extremely difficult unless it is anticipated (Hamaloglu, 2002); patient comes with symptoms and investigated like barium meal, computed tomography. A characteristic appearance like a “cauliflower” sign, whole intestine wrapped up occurs concentrated in an area (Navani, 1995). The diagnosis of AC is a challenge (Abad Calvo, 2013). Several cases have been reported in males (Kirshtein, 2011). Mostly the patients are females (Reynders, 2009). The etiology is variable. Exact etiology is not known. AC is noted in patients with tuberculosis, sarcoidosis, systemic lupus erythematosus, chronic ambulatory peritoneal dialysis, patient on beta adrenergic drugs like proctolol, propranolol, chemotherapeutic drugs like cisplatin, ovarian thecoma (Clement, 1994), endometrial stromal nodules (Clement, 2011), retrograde infection in females, abdominal trauma. Usually AC occurs in tropical and subtropical countries. AC is also called sclerosing encapsulating peritonitis. In our case the patient had no abdominal distension or ascites. It was a case of degenerating fibroid for which total abdominal hysterectomy with bilateral salpingoophorectomy was planned. Similar case of AC has been reported in a case of degenerating fibroid (Critchley, 2012). If AC has been anticipated, x-ray and Computed tomography (CT) would have helped in the diagnosis (Tain lee Chin journal radiology 2010).

Conclusion

When abdominal cocoon occurs, the patient will present with abdominal pain and obstructive bowel symptoms wherein investigations to rule out bowel symptoms are essential. Here the patient comes with the history of menorrhagia and pain, the symptoms made us think the diagnosis as submucous fibroid. It is unusual to anticipate the presence of abdominal cocoon in such cases. Here the pain was attributed to submucous fibroid, the diagnosis of abdominal cocoon with such patients in future should be anticipated. Luckily the patient had no bowel symptoms hence the abdominal cocoon could be tackled with simple

Case Report

procedure of adhesiolysis. In complicated cases the presence of skilled general surgeon is mandatory to help in bowel resection. A team work is always the need of the hour in dilemma.

REFERENCES

- Abad Calvo P de Diego Suárez M, Isnard Blanchar RM, Ojanguren Sabán I and Castellví Gil A (2013).** Abdominal cocoon syndrome: A diagnostic and therapeutic challenge. Case report. *Cirugía Española*.
- Ali O Devay Gomceli I, Korukluoglu B and Kusdemir A (2006).** An unusual and difficult diagnosis of intestinal obstruction: the abdominal cocoon. Case report and review of literature. *World Journal of Emergency Surgery* 1 8.
- Clement PB, Young RH, Hanna W and Scully RE (1994).** Sclerosing peritonitis associated with luteinized thecomas of the ovary. A clinicopathological analysis of six cases. *American Journal of Surgical Pathology* 18(1) 1-13.
- Critchley M, John B and Iqbal P (2012).** Degenerative Fibroid and Sclerosing Peritonitis. *Case Reports in Obstetrics and Gynecology* 218126.
- Foo KT, Ng KC, Rauff A, Foong WC and Sinniah R (1978).** Unusual small intestinal obstruction in adolescent girls: the abdominal cocoon. *British Journal of Surgery* 65(6) 427-30.
- Hamaloglu E, Altun H, Ozdemir A and Ozenc A (2002).** The abdominal cocoon: a case report. *Digestive Surgery* 19(5) 422-4.
- Kirshtein B, Mizrahi S, Sinelnikov I and Lantsberg L (2011)** Abdominal cocoon as a rare cause of small bowel obstruction in an elderly man: report of a case and review of the literature. *Indian Journal of Surgery* 73(1) 73-5
- Makam R, Chamany T, Potluri VK, Varadaraju PJ and Murthy R (2008).** [In Process Citation]. *Journal of Minimal Access Surgery* 4(1) 15-7.
- Navani S, Hah P, Pandya S and Doctor N (1995).** Abdominal cocoon--the cauliflower sign on barium small bowel series. *Indian Journal of Gastroenterology* 14(1) 19
- Reynders D, Van der Stighelen Y (2009).** The abdominal cocoon. A case report. *Acta Chirurgica Belgica* 109(6) 772-4.
- Sayfan J, Adam YG and Reif R (1979).** Peritoneal encapsulation in childhood. Case report, embryologic analysis, and review of literature. *American Journal of Surgery* 138(5) 725-7.
- Tain Lee, Ming-Der Lee, Ming-Hsiean Hsu, Shun-an Lee and Usman MaLik (2010).** Computed Tomographic Findings of an Abdominal Cocoon with Intestinal obstruction: a case report. *Chinese Journal of Radiology* 35 61-65
- Xiao-yan Zhang, Yu-huan Qiao, Xiao-ling Fan, Zhong-fu Yuan, Fang-fang Geng and Rui-xia Guo (2011).** Endometrial stromal nodule complicated by abdominal cocoon: Case report and literature review. *Scientific Research and Essays - Academic Journals* 6(22) 4738-4743.