

## **MICROSPORIDIAL INFECTION IN SOME DOMESTIC AND LABORATORY ANIMALS IN IRAQ**

**Hafidh I. Al-Sadi<sup>1</sup> and \*Saevan Saad Al-Mahmood<sup>2</sup>**

<sup>1</sup> *Department of Oral and Maxillofacial Surgery, College of Dentistry*

<sup>2</sup> *Department of Pathology and Poultry Diseases, College of Veterinary Medicine  
University of Mosul, Mosul, Iraq*

*\* Author for Correspondence*

### **ABSTRACT**

Microsporidian are obligate intracellular opportunistic fungal pathogens that infect a wide range of hosts including insects, fish, birds, and mammals. Microsporidian infection in mammals occurs world – wide but prevalence data vary widely according to reliability of detection methods. Objective of the present study was to report for the first time in Iraq the prevalence of spontaneous microsporidian infection in cattle (n=115), sheep (n=102), horses (n=97), donkeys (n=117), cats (n=53), dogs (n=80), rabbits (n=152), mice (n= 119), rats (n=95), pigeons (*Columba livia*)(n=83), chickens (n=71), zebra finches (*Taeniopygia guttata*) (n=41), and the common carp (*Cyprinus carpio* L.) (n=121). All of the animals were from Nineveh province, Iraq and the survey was done during the period June 1, 2012 to June 1, 2013. Pathological lesions of spontaneous microsporidiosis in rabbits, mice, and rats were also reported. Fecal examination was done using Giemsa, quick – hot Gram – chromotrope, Weber – green modified trichrome, and Ryan – blue modified trichrome stains. For histopathological examination tissue sections were stained with hematoxylin and eosin, Giemsa, Gram, periodic acid – Schiff (PAS), modified Gram (Brown – Brenn), and the modified trichrome stains. Prevalence of microsporidian infection was 10.4% in cattle, 6.9% in sheep, 14.4% in horses, 7.7% in donkeys, 9.4% in cats, 13.8% in dogs, 27.0% in rabbits, 10.1% in mice, 15.8% in rats, 6.0% in pigeons, 9.9% in chickens, 9.8% in zebra finches, and 12.4% in fish. Infected rabbits showed non – suppurative focal or multifocal meningoencephalitis, focal interstitial nephritis, non – suppurative portal infiltration and heavy infiltration of mononuclear cells in the liver, non – suppurative pneumonia, and blunting of the intestinal villi. Inflammations in other organs were rare but lymphoid hyperplasia of the white pulp of the spleen was observed in most rabbits. Parasites were seen in renal tubular epithelium, endothelium of blood capillaries within renal interstitium, and enterocytes of the intestinal villi. Similar histopathological lesions but of lower intensity were seen in mice naturally infected with microsporidia. In rats, the lesions were similar to those seen in rabbits but brain lesions were not found. In conclusion, microsporidian infection is fairly common in domestic and laboratory animals as well as in fish and birds in Nineveh province, Iraq. These animals may serve as important source of spore contamination for opportunistic infections in humans. Further studies are needed to elucidate the occurrence of microsporidian infection in humans and to ascertain the entity of the various microsporidian species.

**Key Words:** *Microsporidian, Infection, Domestic, Laboratory, Animals, Iraq.*

### **INTRODUCTION**

Microsporidian are eukaryotic, obligate intracellular, spore – forming pathogens that infect almost all animal phyla (invertebrate and vertebrate hosts), including other protists (Mladineo and Lovy, 2011). Historically, these microorganisms have been considered “primitive” protozoa, however, the molecular phylogenetic analysis has led to the recognition that these organisms are not primitive but degenerate protists and that they are most closely related to fungi and not to protozoa (Lee *et al.*, 2008). At present, the fungal nature of the microsporidia is well accepted but their exact position in the fungal tree remains debated (McLaughlin *et al.*, 2009; Keeling, 2009; Capella – Gutierrez *et al.*, 2012). Approximately 1400 species belonging to 170 genera are included in the phylum Microsporidian (Wagnerova *et al.*, 2013) and only 14 species have been reported as opportunistic pathogens in mammals (Didier and Weiss, 2006). Thirteen microsporidian species have been reported to infect humans causing diarrhea in immunocompromised individuals, mainly AIDS patients; in some cases, infection can also occur in otherwise healthy hosts (Lee *et al.*, 2010). Four microsporidian species are

## Research Article

known to infect domestic animals namely *Enterocytozoon bieneusi*, *Encephalitozoon cuniculi*, *Encephalitozoon intestinalis*, and *Encephalitozoon hellem* (Wagnerova *et al.*, 2013). Microsporidian are quite common in seawater, fresh water and estuaries and constitute a constant threat for aquaculture (Rodriguez – Tovar *et al.*, 2011). More than 158 microsporidian species in 7 genera have been documented to infect fish (Casal *et al.*, 2008). Infections by this microorganism cause reduced growth rate of fish and decreased productivity in fish farms (Constantine, 1999). Some microsporidian species, such as *Encephalitozoon* spp. and *E. bieneusi*, are proven to be zoonotic (Mathis *et al.*, 2005). Microsporidian have long been known to be causative agents of economically important diseases in insects (silk worms and honey bees) (Becnel and Andreadis, 1999). Additionally, microsporidia have been added to the National Institutes of Health list of priority pathogens, as well as the Environmental Protection Agency list of waterborne microbial contaminants of concern (Hoffman *et al.*, 2008). Mink industry also has been compromised by microsporidiosis, and subclinical microsporidia infections in laboratory animals have interfered with biomedical research (Didier *et al.*, 2004).

Microsporidian spores are the mature and infectious stage of the life cycle and they are resistant and survive for long periods of time in the environment (Fayer, 2004; Didier and Weiss, 2008). Spores of microsporidian species that infect mammals are small and oval in shape, measuring approximately 1.0 – 3.0  $\mu\text{m}$  by 1.5 – 4.0  $\mu\text{m}$ . Spores are surrounded by two layers, a glycoprotein outer layer and a chitinous inner layer (Southern *et al.*, 2007; Didier and Weiss, 2008). Several proteins have been recognized within the spore wall and the endospores including SWP1, SWP2, SWP3 (EnP2) and EnP1 (Peuvel – Fanget *et al.*, 2006; Xu *et al.*, 2006). Some of these proteins may be involved in spore wall adhesion to host cells or mucin and thus may play a role in the process of adhesion (Southern *et al.*, 2007). Within the cytoplasm of the spore are a nucleus in a monokaryon or diplokaryon arrangement, an anterior anchoring disk, a membranous lamellar polaroplast that appears to include an atypical Golgi apparatus, polar vesicles that are likely to be reduced mitochondria called mitosomes, endoplasmic reticulum, ribosomes, and a poster vacuole (Beznoussenko *et al.*, 2007). Additionally, the cytoplasm contains a unique structure, the polar tube, which infects the host cell during germination (Didier and Weiss, 2008). The polar tube arises from the anchoring disk and coils several times within the posterior region of the spore. A builds up of osmotic pressure result in swelling of the posterior vacuole and causes the polar tube to evert, followed by transfer of the contents of the spore through the 50 – 500  $\mu\text{m}$  – long polar tube into the host cell (Keeling and Slamovits, 2004).

In humans, *Enterocytozoon bieneusi*, *Encephalitozoon intestinalis*, *Encephalitozoon hellem*, and *Encephalitozoon cuniculi* have been reported as opportunistic pathogens in human immunodeficiency virus (HIV) - infected patients and other immunocompromised patients such as transplant recipients (Notermans *et al.*, 2005). Microsporidian infections have also been described in immunocompetent individuals such as travelers (Muller *et al.*, 2001). *E. bieneusi* and *E. intestinalis* cause severe persistent diarrhea in HIV - infected patients and they are the most commonly isolated species from stool specimens (Franzen and Muller, 2001). Additionally, *Encephalitozoon* species have been found to cause rhinosinusitis, keratoconjunctivitis, nephritis, hepatitis and disseminated infections (Notermans *et al.*, 2005). The *Encephalitozoon* species have been isolated from urine and respiratory excretions, and *E. hellem* and *E. cuniculi* have been occasionally detected in stool specimens (Muller *et al.*, 2001). *Encephalitozoon cuniculi* has been studied more extensively than the other species and has been reported in the common laboratory rodents as well as human and non – human primates. *E. intestinalis* was isolated for the first time from mammals other than humans from feces of donkeys, dogs, pigs, cow, and goat (Bornay – Linares *et al.*, 1998). *Enterocytozoon bieneusi* has been detected in pigs, cows, goats, chickens, cats, turkeys and in simian immunodeficiency virus – inoculated monkeys (Lores *et al.*, 2002).

Microsporidian infections in mammals have been suggested to occur via ingestion or inhalation of spores. Vertical or transplacental transmission of microspriodiosis has been described in carnivores, including foxes and domestic dogs, and occasionally in non – human primates, horses, rabbits, and rodents (Didier *et al.*, 2004). Transmission of microsporidiosis was possible experimentally in laboratory animals using the intraperitoneal, intravenous, intrarectal, intratracheal and intracerebral inoculations. The primary site of infection depends on the route of inoculation and typically occurs in epithelial cells lining the gastrointestinal or respiratory tracts. Following germination of the spores and

## Research Article

infection of the host cells, the organisms multiply by merogony, and by sporogony differentiate into spores.

Most of the available knowledge on the immune response against microsporidia is based on the model infection of mice with *Encephalitozoon cuniculi* (Salat *et al.*, 2008). This species of microsporidia is associated with HIV infection, organ transplants, travelers and the elderly (Didier, 2005; Moretto *et al.*, 2010). It has been suggested that cell – mediated immunity is critical for host resistance against *E. cuniculi* infection (Khan *et al.*, 2001) and that CD8<sup>+</sup>T cells play a predominant role during this type of infection (Khan *et al.*, 1999). *E. cuniculi* challenge was fatal in mice lacking CD8<sup>+</sup>T cells and it has been suggested that CD8<sup>+</sup>T-cell cytotoxic response is essential for protective immunity against this parasite. Braunfuchsova *et al.*, 2002 reported that the significance of CD4<sup>+</sup> and CD8<sup>+</sup>T lymphocytes in protecting mice against *E. cuniculi* infection differs depending on the route of infection. CD8<sup>+</sup>T lymphocytes have been found to be essential for protection after intraperitoneal infection and CD8<sup>+</sup>T – lymphocyte – deficient mice were able to overcome the outcome of the disease following peroral infection. It was proposed that CD8<sup>+</sup>T- lymphocyte – independent protection is mediated by CD4<sup>+</sup>T lymphocytes producing gamma interferon (IFN- $\gamma$ ), and by B lymphocytes producing specific antimicrosporidial antibody (Sak *et al.*, 2006; Salat *et al.*, 2006).

IFN- $\gamma$  is essential for survival of mice following intraperitoneal or peroral infection (Khan and Moretto, 1999; Salat *et al.*, 2005). Additionally, it has been found that IFN- $\gamma$  – activated macrophages are able to kill microsporidia in vitro (Jelinek *et al.*, 2007). Toll – like receptor 4 (TLR4) has been found to be critical in the induction of CD8<sup>+</sup>T- cell immunity against *E. cuniculi* infection (Lawlor *et al.*, 2010).

From review of the literature it became clear that microsporidiosis has not been previously reported in humans and animals in Iraq. The aim of this study was to report the prevalence of spontaneous (naturally – occurring) microsporidiosis in some domestic and laboratory animals and to describe the pathology of the spontaneous disease in rabbits, mice and rats in Iraq.

## MATERIALS AND METHODS

### Animals

Fecal samples were collected randomly from cattle (n=115), sheep (n=102), horses (n=97), donkeys (n=117), cats (n=53), dogs (n=80), rabbits (n=152), mice (n= 119), rats (n=95), pigeons *Columba livia* (n=83), chickens (n=71), zebra finches (*Taeniopygia guttata*) (n=41), and the common carp (*Cyprinus carpio* L.) (n=121). Animals that were included in the study were all from Nineveh Province and the fecal samples were collected during the period extending from June 1, 2012 to June 1, 2013. As far as the rabbits, mice and rats they were from laboratory colonies reared in the Animal House, College of Veterinary Medicine, University of Mosul as well as the Animal Houses of the Colleges of Medicine and Education, University of Mosul.

Fecal samples were collected directly from the rectum into plastic cups and held at 4°C for 18 – 24 hours. In the laboratory, a preservative (5-10% neutral buffered formalin – sodium acetate and 4% sodium permanganate) was added to feces at the rate of 10 ml of the preservative to each gram of the fecal specimens. The mixture was kept in the refrigerator at 4°C till examination which was done within 24 hours (Garcia, 2007).

### Processing of Fecal Samples

The fecal samples were sieved through gauze and cotton to get rid of the large objects or sediments, placed in 15 ml test tubes, and centrifuged at 7500 round/minute (rpm) for 40 minutes. Resuspension of the sediment was done using phosphate buffered saline (PBS) and the test tubes were centrifuged at 7500 rpm for 40 minutes. The filtrate was discarded and the sediment (1 ml) from each tube was resuspended in a test tube and thus became ready for examination.

A drop of the precipitate was placed on a glass microscope slide and was spread by a second slide and the smear was left to dry at room temperature. The slides were then dipped in absolute methyl alcohol for fixation and left to dry at room temperature. Staining of the smears was done with the following stains; Giemsa, quick – hot Gram – chromotrope, Weber – green modified trichrome, Ryan – blue modified trichrome and Calcofluor white stains (Weber *et al.*, 1992; Ryan *et al.*, 1993; Garcia, 2002; Garcia, 2007; Suvarna *et al.*, 2013).

## Research Article

### Detection and Morphometry of Spores

The criteria used to define microsporidia – positive animals was the presence of one or more pinkish or pinkish – violet ovoid structure with a spore wall and a belt – like stripe, over an examination of at least 100 field /100X, confirmed by two examiners. Thin fecal smears were prepared and stained with one of the standard stains, and the length and width of 50 spores per glass microscope slide were measured using an Italian microscope (Optica) and an optical micrometer. The obtained numbers were multiplied by the microscope tube factor which is 1.6 for the oil immersion lens and measurements of the spores were recorded in micrometers (Reabel *et al.*, 2012).

### Histopathological Examination

Laboratory animals (rabbits, mice and rats) that were positive for microsporidian infection (fecal examination) were euthanised using chloroform (Cooney *et al.*, 2013). Following gross pathological examination, tissue specimens were collected from the brain, kidneys, liver, lungs, intestines, pancreas, heart, and spleen. These tissue specimens were fixed in 10% formalin for 48 – 72 hours (Suvarna *et al.*, 2013). Following fixation, the tissue specimens were washed with tap water, dehydrated in ascending grades of alcohol, cleared in xylol and embedded in paraffin wax (60 – 62 °C melting point). Sections of 4 – 5 µm thickness were cut and stained with hematoxylin and eosin, Giemsa, Gram, periodic acid – Schiff (PAS), modified Gram (Brown – Brenn), and the modified trichrome stains (Garcia, 2002; Garcia, 2007; Suvarna *et al.*, 2013).

### Statistical Analysis

Data concerning the length and width of the spores in various experiments were analysed using statistical software (SPSS), version 16.0 and the values were presented as mean, standard error, and range in micrometers (Petrie and Watson, 2013).

## RESULTS AND DISCUSSION

### Results

Prevalence of Microsporidial infection in various domestic and laboratory animals examined in this study is shown in Table (1). From data presented in this Table it is evident that the frequency of occurrence of microsporidiosis in various animal species arranged in order of decreasing frequency was in rabbits (27%), rats (15.8%), horses (14.4%), dogs (13.8%), fish (12.4%), cattle (10.4%), mice (10.1%), chickens (9.9%), zebra finches (9.8%), cats (9.4%), donkeys (7.7%), sheep (6.9%), and pigeons (6%). Table (2) presents the measurements (length and width in micrometers) of microsporidia that have been diagnosed in this study. The size of the spores ranged from 1.5 – 2.4 µm length to 0.6 – 1.6 µm width (Figure 1).

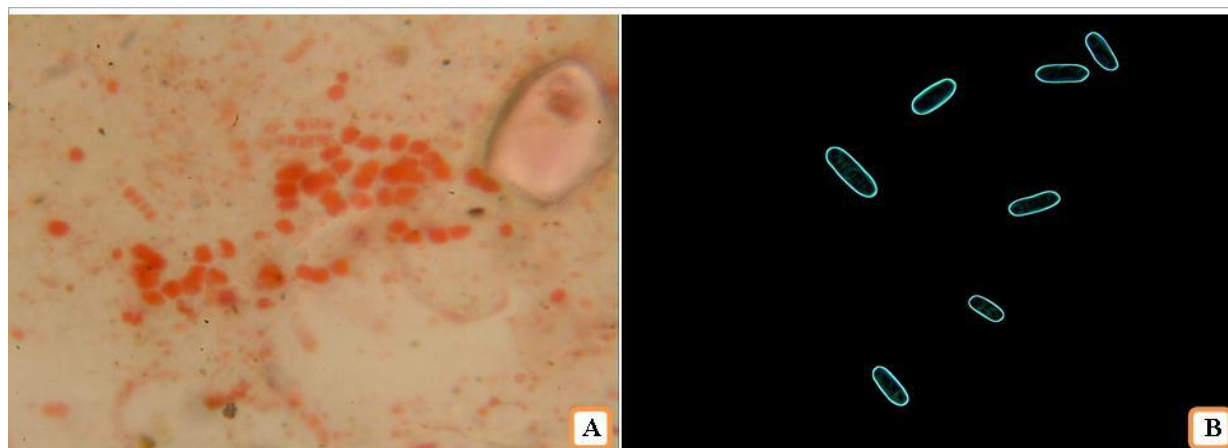
**Table 1: Prevalence of Microsporidial infection in various animal species in Iraq**

Animals	Number of examined cases	Number of positive cases	Percentage
Cattle	115	12	10.4
Sheep	102	7	6.9
Horses	97	14	14.4
Donkeys	117	9	7.7
Cats	53	5	9.4
Dogs	80	11	13.8
Rabbits	152	41	27.0
Mice	119	12	10.1
Rats	95	15	15.8
Pigeons	83	5	6.0
Chickens	71	7	9.9
Zebra Finches	41	4	9.8
Fish	121	15	12.4
<b>Total</b>	<b>1246</b>	<b>157</b>	<b>12.6</b>

**Research Article**

**Table 2: Measurements of microsporidian spores in various animals species**

Animals	Number of positive cases	Length		Width	
		Mean $\pm$ SE	range	Mean $\pm$ SE	range
Cattle	12	2.2 $\pm$ 0.09	1.9-2.4	0.2 $\pm$ 0.08	1.0-1.4
Sheep	7	2.1 $\pm$ 0.03	1.8-2.3	1.1 $\pm$ 0.03	0.9-1.4
Horses	14	2.1 $\pm$ 0.04	1.8-2.4	1.3 $\pm$ 0.04	0.9-1.5
Donkeys	9	2.1 $\pm$ 0.04	1.9-2.3	1.2 $\pm$ 0.05	1.0-1.6
Cats	5	2.3 $\pm$ 0.05	1.9-2.4	1.2 $\pm$ 0.02	0.9-1.5
Dogs	11	2.2 $\pm$ 0.08	1.7-2.5	1.0 $\pm$ 0.09	0.8-1.4
Rabbits	41	2.1 $\pm$ 0.04	1.9-2.3	0.9 $\pm$ 0.07	0.7-1.5
Mice	12	2.0 $\pm$ 0.03	1.7-2.4	1.1 $\pm$ 0.05	0.9-1.4
Rats	15	2.1 $\pm$ 0.10	1.8-2.4	1.2 $\pm$ 0.07	0.9-1.5
Pigeons	5	1.9 $\pm$ 0.07	1.7-2.1	0.9 $\pm$ 0.09	0.6-1.3
Chickens	7	1.7 $\pm$ 0.09	1.5-1.9	0.9 $\pm$ 0.11	0.6-1.1
Zebra Finches	4	1.7 $\pm$ 0.03	1.6-2.0	0.9 $\pm$ 0.05	0.8-1.1
Fish	15	2.0 $\pm$ 0.05	1.9-2.4	1.1 $\pm$ 0.11	1.0-1.3



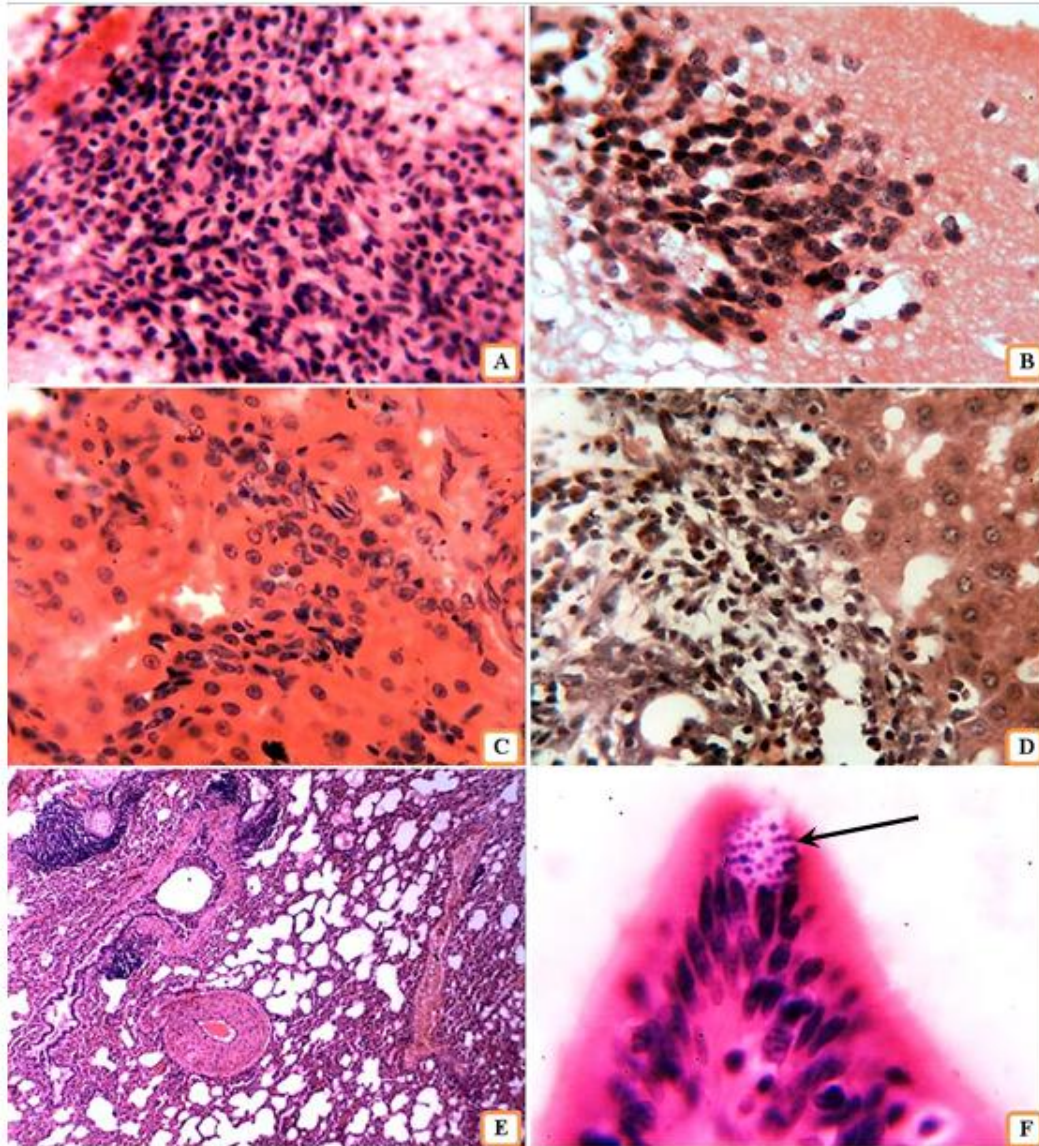
**Figure 1: Microsporidian spores in fecal specimen from rabbit with spontaneous microsporidiosis A- Modified chromotrope Ryan blue stain, X1000. B-Calcafluor white, X1000**

Histopathological lesions that were found in the cerebral tissue of rabbits included perivascular alterations ranging from discreet changes to non – suppurative, focal or multifocal granulomatous (meningo-) encephalitis (Figure 2A and 2B). Granulomas contain lymphocytes, plasma cells and glial cells and are often necrotic in the center. The most commonly affected areas were in the cerebrum (cortex and medulla) and to a lesser extent in the cerebellum. Involvement of the leptomeninges was very common. Lesions in renal tissue included focal granulomatous nephritis, primarily with mononuclear cells. Severe grades of chronic interstitial nephritis were also seen (Figure 2C). The parasites were seen in the tubular epithelium and in the endothelium of blood capillaries within the interstitium. Infiltration of mononuclear cells was found around the capillaries in a fashion similar to that of periarteritis nodosa. In the liver, non – suppurative portal infiltration and heavy infiltration of mononuclear cells around arteries in the portal area were found (Figure 2D). Most of the rabbits displayed non – suppurative inflammatory infiltrations in the lung. Other pulmonary lesions included fibrinoid change and thickening of the small blood vessels and narrowing of these vessels (Figure 2E). Additionally, perivascular cuffings with lymphocytic – plasmacytic cells in the intervalveolar septa



### **Research Article**

were evident. Parasites were found in the interstitium of the lung and within the alveolar macrophages. Intestinal tissues showed the presence of parasites within enterocytes mainly at the tips of the villi, and some in enterocytes at the sides of the villi (Figure 2F). Histopathological lesions in the intestines included blunt villi, thickening of the mucosa, and infiltrations of inflammatory mononuclear cells in submucosa, lamina propria and serosa. In two rabbits, necrosis of the tips of the villi and sloughing of the necrotic material were found. Inflammations in other organs were rare but lymphoid hyperplasia of the white pulp of the spleen was observed in most rabbits.



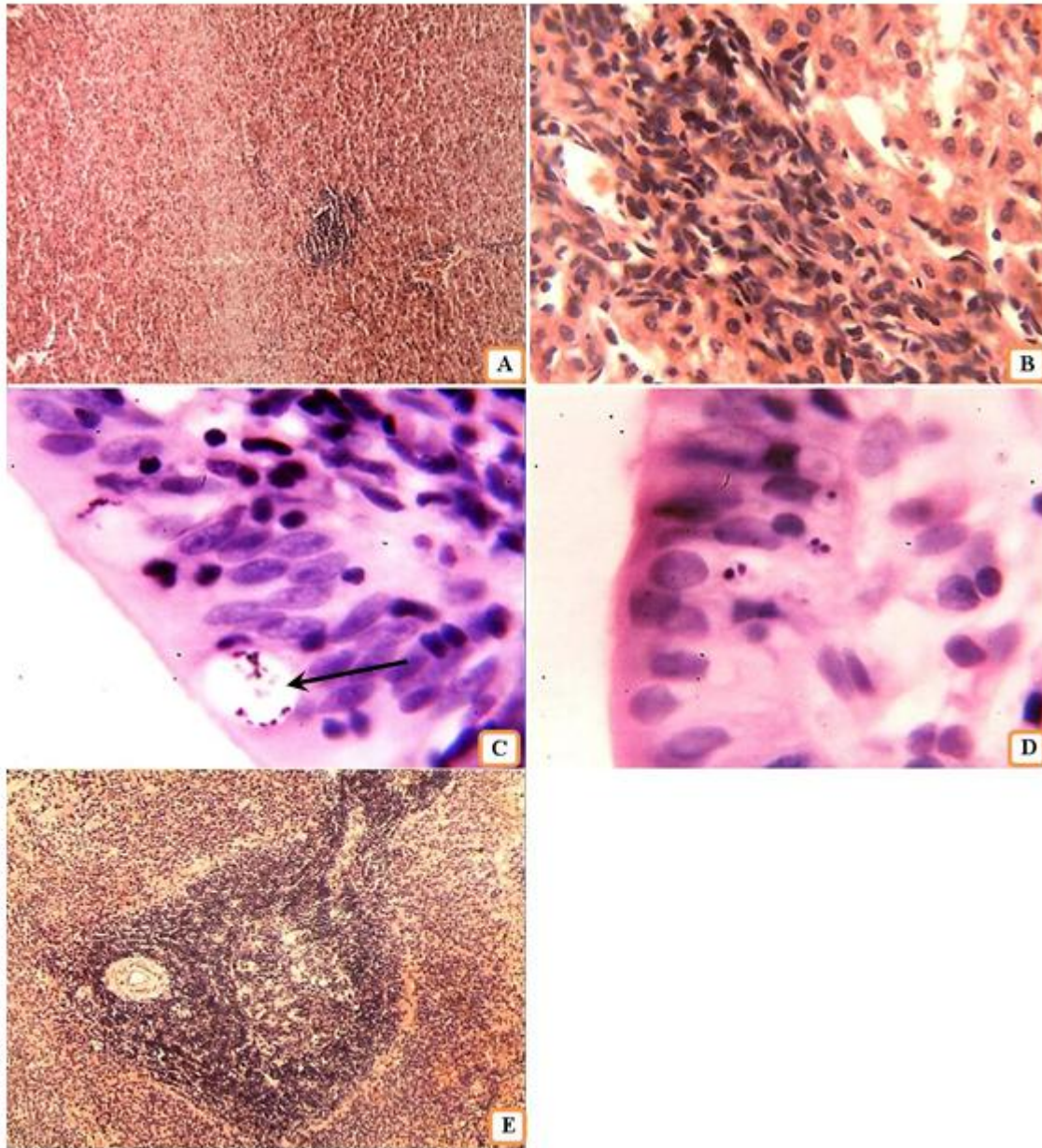
**Figure 2: Tissue sections from rabbit with spontaneous microsporidiosis, hematoxylin and eosin stain. A-Vasculitis with heavy infiltration of mononuclear cells in the cerebrum, X400. B-Granuloma in the cerebral cortex, X400. C- Focal interstitial nephritis in the kidney, X400. D-Granulomatous inflammation in the portal area of liver, X400. E. Emphysema, vasculitis, and thickening of blood vessels in the lung, X40. F- Microsporidial spores in enterocytes (arrow), X1000**

In mice, the histopathological changes were similar to those seen in rabbits but they were less severe. The cerebral tissue showed discrete foci of gliosis, vasculitis in the leptomeninges, and infiltrations of mononuclear cells in the cerebral cortex (Figure 3A). Renal tissues displayed increased cellularity of the glomeruli, focal infiltrations of mononuclear cells in the interstitium (focal interstitial nephritis),



### **Research Article**

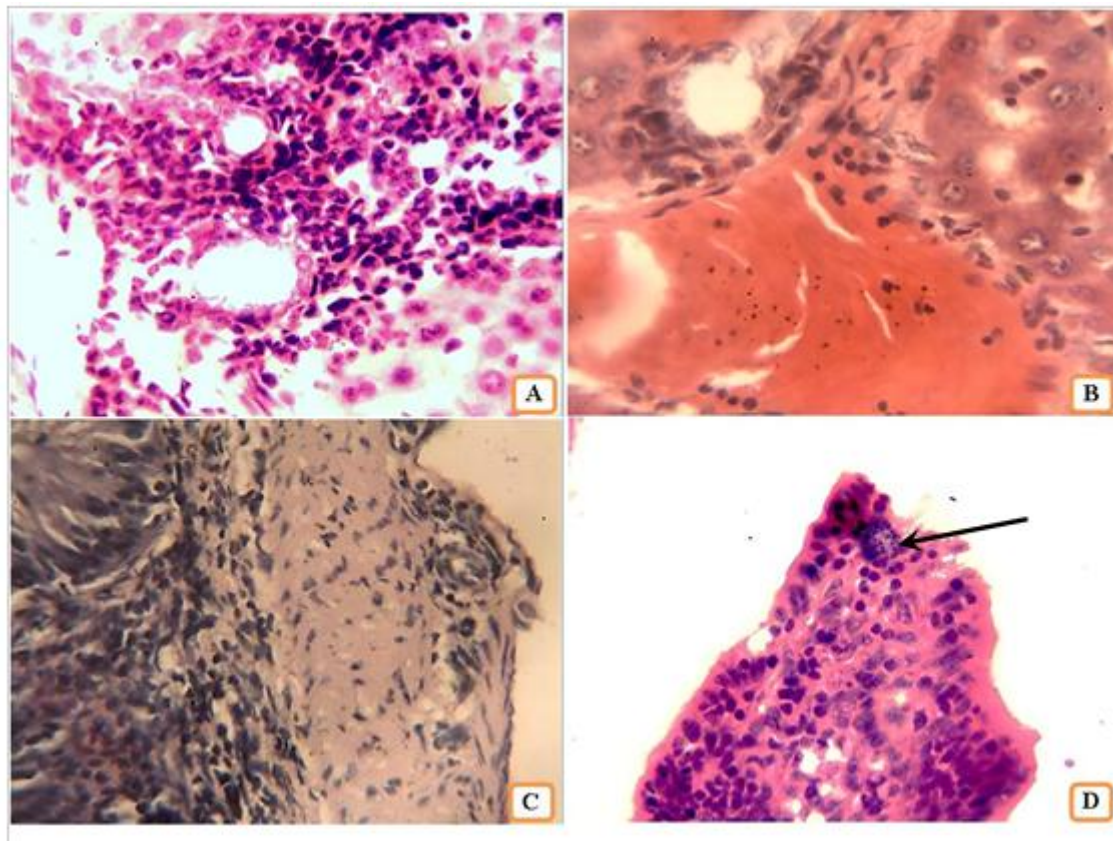
and presence of parasites within tubular epithelial cells and endothelial cells in the interstitium. Sections of the liver showed foci of granulomatous inflammation, and vasculitis and cholangitis within the portal areas (Figure 3B). Pulmonary lesions included thickening of the interalveolar septa due to heavy infiltration of mononuclear cells and thickening of blood vessels due to proliferation of smooth muscle cells within the tunica media. Intestinal tissues displayed the presence of parasites in enterocytes within the villi. Two morphological forms of the parasite were seen, one in parasitophorous vacuoles and the second free in cytoplasm of the enterocytes (Figure 3C and 3D). Necrosis of the tips of some of the intestinal villi and infiltrations of mononuclear cells in the mucosa, submucosa and lamina propria were evident. Hyperplasia of the lymphoid nodules (Peyer's patches) was seen. Lymphoid hyperplasia of the white pulp of the spleen was noted (Figure 3E).



**Figure 3: Tissue sections from mice with spontaneous microsporidiosis, hematoxylin and eosin stain. A- Focal infiltration of mononuclear cells in the brain, X100. B- Granuloma within the portal area of the liver, X400. C- Microsporidial spores in parasitophorous vacuoles within enterocytes (arrow), X1000. D- Microsporidial spores in the enterocytes, X1000. E. Lymphoid hyperplasia of the white pulp of the spleen and diffuse accumulation of lymphocytes in the paracortical zones, X100**

### Research Article

Histopathological lesions were not encountered in the brain of rats. Renal tissues showed increased cellularity of the glomeruli, focal interstitial nephritis, and the presence of parasites in the renal tubular epithelium (Figure 4A). Focal infiltrations of inflammatory mononuclear cells (particularly lymphocytes) were found in hepatic parenchyma as well as vasculitis and cholangitis in portal areas (Figure 4B). Pulmonary tissues demonstrated thickening of interalveolar septa due to infiltrations of mononuclear cells. Sections of the intestines exhibited a constant lesion which was in the form of serositis accompanied by increased numbers of the mesothelial cells (Figure 4C). Lymphatic enteritis was seen in two of the rats. The parasites were found within parasitophorous vacuoles in enterocytes of the intestinal villi (Figure 4D). Lymphoid hyperplasia of the germinal centers within the white pulp of the spleen was seen as well as infiltration of large numbers of lymphocytes in the paracortical areas. The pancreatic tissue showed vasculitis and infiltration of inflammatory mononuclear cells in the pancreatic parenchyma.



**Figure 4:** Tissue sections from rat with spontaneous microsporidiosis, hematoxylin and eosin stain. A- Focal interstitial nephritis in the kidney, X100. B-Focal infiltration of inflammatory mononuclear cells around blood vessel and bile duct within the portal area of the liver, X400. C- Serositis and proliferation of mesothelial cells of the intestine, X400. D- Microsporidial spores in parasitophorous vacuole in enterocytes (arrow), X400

### DISCUSSION

Results of the present study indicated for the first time that Microsporidial infection is common in domestic and laboratory animals in Iraq. As expected, the highest prevalence rate was in rabbits (27%). This prevalence rate is comparable to that reported serologically in many other geographic locations (Kunzel and Joachim, 2010). Seroprevalence rates have been reported to be high in pet rabbit populations with 37% to 68% of the population (Harcourt – Brown and Holloway, 2003; Ebrecht and Müller, 2004). Prevalence of the parasite is lower in wild rabbit populations, probably due to the lower animal density (Chalupsky *et al.*, 1990). *Encephalitozoon cuniculi* is the only Microsporidial organism



### Research Article

known to cause spontaneous disease in rabbits. Additionally, attempts to experimentally infect rabbits with *E. intestinalis*, *E. hellem*, and *Enterocytozoon bieneusi* have been unsuccessful (Wasson and Peper, 2000). Therefore, it could be assumed that the cause of spontaneous microsporidiosis in rabbits reported in this study is caused by *E. cuniculi*. This microsporidian species has been reported for the first time in a colony of laboratory rabbits in 1922 as a cause of vestibular disease (Jeklova *et al.*, 2010). It has been considered zoonotic pathogen and described as an opportunistic parasite in immunocompromised human beings (Mathis *et al.*, 2005). *E. cuniculi* constitutes the most extensively studied mammalian microsporidium, and spontaneous infections with this parasite have been documented in rabbits, mice, rats, muskrats, guinea pigs, hamsters, ground shrews, goats, sheep, pigs, horses, domestic dogs, wild and captive foxes, domestic cats, a variety of exotic carnivores, and in non – human primates (Didier, 2005; Ozkan *et al.*, 2011). Three strains of *E. cuniculi* have been identified genetically. Strain I was first isolated from rabbits, strain II from rodents, and strain III from dogs, but these strains can infect other hosts as well (Ozkan *et al.*, 2011; Xiao *et al.*, 2001; Didier *et al.*, 1995). Histopathological lesions of natural Microsporidial infections that are described in the present study are similar to those reported by others (Kunzel and Joachim, 2010; Csokai *et al.*, 2009a; Csokai *et al.*, 2009b; Kunzel *et al.*, 2008; Valencakova *et al.*, 2008; Wasson and Peper, 2000; Fuentealba *et al.*, 1992). They are also similar to those described in rabbits infected experimentally with a rabbit isolate of *E. cuniculi* (Shadduck *et al.*, 1979). However, in experimentally – induced encephalitozoonosis the lesions were confined to the cerebrum, meninges, and kidneys. At 6 weeks, focal gliosis and a few scattered lymphocytes were seen in the cerebral cortex. Brain lesions were more pronounced at 8 and 10 weeks after inoculation and early granuloma formation characterized by focal gliosis, lymphocytes, plasma cells, and epithelioid cells was noted. In lesions that were in the vicinity of blood vessels, proliferation of adventitial cells was evident. Focal scattered lymphocytic meningitis was found in all animals with brain lesions. Six weeks after inoculation, scattered foci of interstitial nephritis composed of lymphocytes, plasma cells, and macrophages were present. More severe lesions were found at 8 and 10 weeks and were characterized by infiltration of lymphocytes, plasma cells, macrophages, proliferation of fibroblasts, and tubular dilatation. Cloudy swelling of some tubular epithelial cells was also found. Lesions were not observed in the spleen or liver. Lesions of the brain and kidneys have been considered indicative of *E. cuniculi* infection when non – suppurative inflammatory changes in the brain and interstitial nephritis were found (Csokai *et al.*, 2009b). It has been pointed out that in naturally infected rabbits, spore can be detected slightly more frequently in the kidneys than in the brain (Csokai *et al.*, 2009a, b). In comparison, *E. cuniculi* were found in the tubular epithelial cells and lumen in the area of interstitial nephritis in experimentally infected rabbits. Attempts to demonstrate the organisms in the brains of experimentally infected rabbits were unsuccessful (Shadduck *et al.*, 1979). Detection of the spores in tissue sections stained with hematoxyline – eosin is difficult and therefore special stains such as chromotropic staining (e.g. acid – fast trichrome or Ziehl – Neelsen), immunofluorescence or chromofluorescence should be used.

In this study, natural microsporidial infection was common in rats with a prevalence rate of 15.8%. Only few reports have been found in the literature describing natural or experimental infection with *E. cuniculi* in rats (Wasson and Peper, 2000; Shadduck *et al.*, 1979). Infections with other microsporidia have not been reported in rats (Wasson and Peper, 2000) and therefore it could be assumed that the species reported in rats in this study is *E. cuniculi*. In the present study, minimal histopathological changes were seen in the brain but extensive lesions including focal interstitial nephritis, focal non – suppurative hepatitis, and non – suppurative vasculitis and cholangitis in the portal areas, inflammatory infiltration in the lung parenchyma, serositis of the intestine, and lymphoid hyperplasia of the germinal centers of the white pulp of the spleen were seen. The parasites were found in the renal tubular epithelium and in the enterocytes of the intestinal villi. These histopathological lesions are similar to those reported in rats experimentally infected with a rabbit isolate of *E. cuniculi* (Shadduck *et al.*, 1979). In experimentally infected rats, the lesions were found in the gray matter of the cerebral cortex of two rats 10 weeks after inoculation. Discrete lesions consisted of glial cells, lymphocytes and plasma cells were seen. Many glial cells were edematous and moderate infiltration of lymphocytes around larger meningeal blood vessels was observed in the vicinity of the brain lesions. Lesions were not observed in the spleen, liver, or kidneys (Shadduck *et al.*, 1979).

### Research Article

In the present study, prevalence rate of Microsporidial infection in laboratory mice was 10.1%. Spontaneous infections with *E. intestinalis*, *E. hellem*, or *Enterocytozoon bieneusi* have not been described in mice (Wasson and Peper, 2000). Therefore, it could be assumed that the species reported in mice in this study is *E. cuniculi*. As in rabbits, *E. cuniculi* infection of immunocomponent mice is usually subclinical and the lesions composed of mononuclear inflammatory foci in the liver, lungs, and brain have been attributed to subclinical *E. cuniculi* infection (Wasson and Peper, 2000). Athymic nude or severe combined immunodeficient (SCID) mice infected experimentally with *E. cuniculi* demonstrate infection of the liver, spleen, pancreas, lungs, hearts, kidneys, brain, peritoneum, and pleura and the infection is characterized by random, multifocal milliary granulomas with various amounts of cell debris and suppurative necrosis. The parasites were found free within foci of inflammation or intracellularly in macrophages, epithelium, or endothelium. In mice that were inoculated orally there were focal ulcerative intestinal mucosal lesions that often extend to the submucosa and tunica muscularis (Didier *et al.*, 1994; Hermanek *et al.*, 1993; Koudela *et al.*, 1993). Shadduck *et al.*, (1979) described the histopathological lesions seen in experimentally – induced encephalitozoonosis in mice using a rabbit isolate of *E. cuniculi*. One mouse showed small glial nodule with few lymphocytes in the gray matter of the cerebral cortex, two weeks following intracerebral inoculation. A more severe, discrete lesion, characterized by focal gliosis, lymphocytes and plasma cells, and adjacent lymphocytic perivascular cuffing was seen at 4 weeks. In all cases with lesions of encephalitozoonosis, scattered lymphocytic meningitis was present. Necrotizing hepatitis was found in mice with brain lesions. Randomly scattered lesions composed of neutrophils, lymphocytes, plasma cells, and liver parenchymal cells undergoing coagulative necrosis were noted. Reticuloendothelial cell hyperplasia with minimum reaction in the splenic white pulp was seen. No lesions were found in the kidneys (Shadduck *et al.*, 1979).

In the present study, among domestic animals, the highest prevalence rate of microsporidian infection was in horses (14.4%). This rate of prevalence is lower than that reported in horses in Czech Republic (24.2%) (Wagnerova *et al.*, 2012). *E. cuniculi* is considered the most frequent microsporidium found in horses (Wagnerova *et al.*, 2013; Wagnerova *et al.*, 2012; Santin *et al.*, 2010). In dogs, the prevalence rate of microsporidiosis was 13.8%. This prevalence in dogs is similar to that reported in dogs in Spain (11.7%) (Lores *et al.*, 2002) and lower than that reported in Iran (31%) (Jamshidi *et al.*, 2012) and Slovakia (37.8%) (Halanova *et al.*, 2003). In fish (the common carp *Cyprinus carpio* L) in Iraq the prevalence of microsporidian infection was found to be 12.4%. For comparison, prevalence of microsporidia species in the Red Sea fish (*Sauridatumbil*) has been reported to be 45.8% (Abdel – Gaffar *et al.*, 2012). In cattle, the prevalence of Microsporidial infection was 10.4%. In USA, one survey found that the prevalence of microsporidian species in cattle was 5.6% in Florida, 14.3% in Maryland, 3.6% in Michigan, 12.5% in New York, 7.7% in North Carolina, 13.6% in Pennsylvania, and 24.3% in Virginia (Sulaiman *et al.*, 2004). In the present study, the prevalence of Microsporidial infection was 9.9% in chickens and 9.8% in zebra finches. In comparison, the prevalence of microsporidiosis was 24.5% in birds in Brazil (Lallo *et al.*, 2012) and 25% in lovebirds (Peach – faced lovebirds, masked lovebirds, and Fischer's lovebirds) in Texas, USA (Barton *et al.*, 2003). Prevalence of Microsporidial infection in cats in this study was 9.4%. This prevalence rate is higher than that reported in cats in Virginia, USA (Hsu *et al.*, 2011) and in cats in Iran (7.5%) (Jamshidi *et al.*, 2012) and lower than that reported in cats in Thailand (31.3%) (Mori *et al.*, 2013). In donkeys, the prevalence of Microsporidial infection was 7.7%. A similar low prevalence rate of Microsporidial infection was found in sheep (6.9%). These findings were difficult to evaluate in view of absence of similar studies. However, in Spain the prevalence of Microsporidial infection in goats was reported to be 14.2%. In the present study, the least frequency of Microsporidial infection (6%) was found in pigeons. In Brazil, the prevalence of Microsporidial infection in pigeons was 31.1% (Lallo *et al.*, 2012). Haro *et al.*, (2005) reported that the prevalence of microsporidia pigeons from urban parks to be 29.0%. In Amsterdam, the Netherlands, prevalence of microsporidia in pigeons was reported to be 11% (Bart *et al.*, 2008).

### Conclusion

Results of this study suggest that spontaneous Microsporidial infection is fairly common in domestic and laboratory animals as well as in fish and birds from Nineveh Province, Iraq. These animals may

## Research Article

serve as important source of spore contamination for opportunistic infections in humans. Furthermore, pathological lesions that were seen in spontaneous Microsporidial infection involved many organ systems indicating a hematogenous spread. Finally, further studies are needed to elucidate the occurrence of Microsporidial infection in humans and to ascertain the entity of the various microsporidian species.

## ACKNOWLEDGMENT

Research was supported by the College of Veterinary Medicine, University of Mosul, Mosul, Iraq.

## REFERENCES

- Abdel-Ghaffar S, Al-Bashtar AR, Morsy K, Mehlhora H, Al-Quraishy S, Al-Rasheid K and Abndel-Gaber R (2012).** Morphological and molecular biological characterization of *Pleistophora aegyptiaca* sp. Nov. infecting the Red Sea fish *Sauridatumbil*. *Parasitology Research* **110** 741-752.
- Bart A, Wentink – Bonnema EM, Heddema ER, Buijs J and Van Gool T (2008).** Frequent occurrence of human – associated microsporidia in fecal droppings of urban pigeons in Amsterdam, The Netherlands. *Applied Microbiology* **74**(22) 7056- 7058.
- Barton CE, Phalen DN and Snowden KF (2003).** Prevalence of microsporidian spores shed by asymptomatic love birds evidence for a potential emerging zoonosis. *Journal of Avian Medicine and Surgery* **17**(4) 197-202.
- Becnel JJ and Andreadis TG (1999).** Microsporidian in insects 1-6. In: *The microsporidia and microsporidiosis*, edited by Wittner M (ASM Press, Washington, D.C.)
- Beznoussenko GV, Dolgikh VV, Seliverstova EV, Semenov PB, Tokarev YS, Trucco A, Micaroni M, Di Giandomenico D, Auinger P, Senderskiv IV, Skarlato SP, Snigirevskaya ES, Komissarchik YY, Pavelka M, De Mattels MA, Luini A, Sokolova YY and Mironov AA (2007).** Analogs of the Golgi complex in microsporidia structure and vesicular mechanisms of function. *Journal of Cell Science* **120** 1288-1298.
- Bornay – Linares F, Da Sliva A, Moura H, Schwartz D, Visvesvara G, Pieniazek N, Cruz – Lopez A, Hernandez – Jouregui P, Guerrero J and Enriquez F (1998).** Immunologic, microscopic, and molecular evidence of *Encephalitozoon intestinalis* (*Septata intestinalis*) infection in mammals other than humans. *Journal of Infectious Diseases* **178** 820-826.
- Braunfuchsova P, Salat J and Kopecky J (2002).** Comparison of the significance of CD4+ and Cd8+ T lymphocytes in the protection of mice against *Encephalitozoon cuniculi* infection. *Journal of Parasitology* **88** 797-799.
- Capella – Gutierrez S, Marcet – Houben M and Gabaldon T (2012).** Phylogenomics supports microsporidia as the earliest diverging clade of sequenced fungi. *BMC Biology* **10** 47.
- Casal G, Matos E, Teles – Grilo ML and Azevedo C (2008).** A new microsporidian parasite, *Potasporamorhaphis* n. gen., n. sp. (Microsporidian) infecting the teleostean fish, *Potamorhaphis guianensis* from the river Amazon. Morphological, ultra structural and molecular characterization, *Parasitology* **135** 1053-1064.
- Chalupsky J, Vavra J and Gaudin J (1990).** Mise en evidence serologique de la presence d' encephalitozoonose et de toxoplasmose chez le lapin de Gareene (*Oryctolagus cuniculus*) en France. Bulletin Society of France. *Parasitology* **8** 91 95.
- Constantine J (1999)** Fact sheet estimating the cost of *Loma salmonae* to B.C. aquaculture. Animal Health Branch, Aquaculture Program, BC Ministry of Agriculture and Food. *Abbotsford Agriculture Centre, Abbotsford*.
- Cooney KA, Chappell JR, Calle RJ and Connally BA (2013).** Veterinary euthanasia techniques A practical guide. 1st edition, A John Wiley & Sons, Ltd., Publication, Wiley- Blackwell Press, California, USA.
- Csokai J, Gruber A, Kunzel F, Tichy A and Joachim A (2009).** Encephalitozoonosis in pet rabbits (*Oryctolagus cuniculus*) pathohistological findings in animals with latent infection versus clinical manifestation. *Parasitology Research* **104** 629-635.



# **Research Article**

- Csokai J, Joachim A, Gruber A, Tichy A, Pakozdy A and Kunzel F (2009).** Diagnostic markers for encephalitozoonosis in pet rabbits. *Veterinary Parasitology* **136** 18-26.
- Didier ES (2005).** Microsporidiosis an emerging and opportunistic infection in humans and animals. *Acta Tropica* **94** 61- 76.
- Didier ES, Stovall ME, Green LC, Brindly PJ, Sestak K and Didier PJ (2004).** Epidemiology of microsporidiosis source and modes of transmission. *Veterinary Parasitology* **126** 145-166.
- Didier ES, Varner PW, Didier PJ, Aldras AM, Millichamp NJ, Murphey- Corb M, Bohm R and Shadduck JA (1994).** Experimental microsporidiosis in immunocompetent and immunodeficient mice and monkeys. *Folia Parasitologica* **41** 1-11.
- Didier ES, Vossbrinck CR, Baker MD, Rogers LB, Bertucci DC and Shadduck JA (1995).** Identification and characterization of three *Encephalitozoon cuniculi* strains. *Parasitology* **111** 411-421.
- Didier ES and Weiss LM (2006).** Microsporidiosis current status. *Current Opinion in Infectious Diseases* **19**(5) 485-492.
- Didier ES and Weiss LM (2008).** Overview of microsporidia and microsporidiosis. *Protistology* **5**(4) 243-255.
- Ebrecht DR and Mueller E (2004).** Zoonosis of microsporidia in rabbit. *TierärztlPrax* **32** (K) 363-9
- Fayer R (2004).** Infectivity of microsporidia spores stored in seawater at environmental temperatures. *Journal of Parasitology* **90**(3) 654- 657.
- Franzen C and Müller A (2001).** Microsporidiosis human diseases and diagnosis. *Microbes and Infection* **3** 389-400.
- Fuentealba IC, Mahoney NT, Shadduck JA, Harvill J, Wicher V and Wicher K (1992).** Hepatic lesions in rabbits infected with *Encephalitozoon cuniculi* administered per rectum. *Veterinary Pathology* **29** 5365-540.
- Garcia LS (2002).** Laboratory identification of the microsporidia. *Journal of Clinical Microbiology* **40**(6) 1982-1901.
- Garcia LS (2007).** Clinical microbiology procedures handbook. Second Edition Update, LSG & Associates, California.
- Halanova M, Cislakova L, Valencakova A, Balent P, Adam J and Travnicek M (2003).** Serologic screening of occurrence of antibodies to *Encephalitozoon cuniculi* in humans and animals in Eastern Slovakia. *Annals of Agricultural and Environmental Medicine* **10** 117-120.
- Harcourt - Brown FM and Holloway HKR (2003).** *Encephalitozoon cuniculi* in pet rabbits. *Veterinary Record* **152** 427-431.
- Haro M, Izquierdo F, Henriques – Gil N, Andres I, Alonso F, Fenoy S and Del Aguila C (2005).** First detection and genotyping of human – associated microsporidia in pigeons from urban parks. *Applied Environmental Microbiology* **71** 3153-3157.
- Hermanek J, Koudela B, Kucerova Z, Ditrich O and Travnicek J (1993).** Prophylactic and therapeutic immune reconstitution of SCID mice infected with *Encephalitozoon cuniculi*. *Folia Parasitologica* **40** 287-291.
- Hoffman RM, Borchardt M, Marshall MM and Sonzogni WC (2008).** Final Report FDP -- Development of Detection and Viability Methods for Waterborne Microsporidian. *United State Environmental Protection Agency* 1-4.
- Hsu V, Grant DC, Zajac AM, Witonsky SG and Lindsay DS (2011).** Prevalence of IgG antibodies to *Encephalitozoon cuniculi* and *Toxoplasma gondii* in cats with and without kidney disease from Virginia. *Veterinary Parasitology* **176** 23- 26.
- Jamshidi Sh, Tabrizi AS, Bahrami M and Momtaz H (2012).** Microsporidian in household dogs and cats in Iran; a zoonotic concern. *Veterinary Parasitology* **185** 121-123.
- Jeklova E, Jekl V, Kovarcik K, Hauptman K, Koudela B, Neumayerova H, Knotek Z and Faldyna M (2010).** Usefulness of detection of specific IgM and IgG antibodies for diagnosis of clinical encephalitozoonosis in pet rabbits. *Veterinary Parasitology* **170** 143-148.
- Jelinek J, Salat J, Sak B and Kopecky J (2007).** Effects of interferon gamma and specific polyclonal antibody on the infection of murine peritoneal macrophages and murine macrophage cell line PMJ2-R with *Encephalitozoon cuniculi*. *Folia Parasitologica* **54** 172-176.

## **Research Article**

- Keeling P (2009).** Five questions about microsporidia. *PLOS Pathogens* **5**(9) e1000489.
- Keeling PJ and Slamovits CH (2004).** Simplicity and complexity of microsporidian genomes. *Eukaryotic Cell* **3**(6)1363-1369.
- Khan IA and Moretto M (1999).** Role of gamma interferon in cellular immune response against murine *Encephalitozoon cuniculi* infection. *Infection and Immunity* **67**(4) 1887-1893.
- Khan IA, Moretto M and Weiss LM (2001).** Immune response to *Encephalitozoon cuniculi* infection. *Microbial Infection* **3**(5) 401-405.
- Khan IA, Schwartzman JD, Kasper LH and Moretto M (1999).** CD8+ CTLs are essential for protective immunity against *Encephalitozoon cuniculi* infection. *Journal of Immunology* **162** 6086-6091.
- Koudela B, Vitovec J, Kucerova Z, Ditrich O and Travnicek J (1993).** The severe combined immunodeficient mouse as model for *Encephalitozoon cuniculi* microsporidiosis. *Folia Parasitologica* **40** 279-286.
- Kunzel F, Gruber A, Tichy A, Edelhofer R, Nell B, Hassan J, Leschnik M, Thalhammer JG and Joachim A (2008).** Clinical symptoms and diagnosis of *Encephalitozoonosis* in pet rabbits. *Veterinary Parasitology* **151** 115-124.
- Kunzel F and Joachim A (2010).** *Encephalitozoonosis* in rabbits. *Parasitology Researches* **106** 299-309.
- Lallo MA, Calabria P and Milanelo L (2012).** *Encephalitozoon* and *Enterocytozoon* (microsporidia) spores in stool from pigeons and exotic birds, Microsporidian in birds. *Veterinary Parasitology* **190** 418-422.
- Lawlor EM, Moretto MM and Khan IA (2010).** Optimal CD8 T- cell response against *Encephalitozoon cuniculi* is mediated by Toll – like receptor 4 upregulation by dendritic cells. *Infection and Immunology* **78**(7) 3097- 3102.
- Lee SC, Corradi N, Byrnes III EJ, Torres – Martinez S, Dietrich FS, Keeling PJ and Heitman J (2008).** Microsporidian evolved from ancestral sexual fungi. *Current Biology* **18** 1675- 1679.
- Lee SC, Corradi N, Doan S, Dietrich FS, Keeling PJ and Heitman J (2010).** Evolution of the sex – related locus and genomic features shared in microsporidia and fungi. *PLOS ONE* **5**(5) e10539.
- Lores B, Del Aguila C and Arias C (2002).** *Enterocytozoon bienersi* (Microsporidian) in fecal samples from domestic animals from Galicia, Spain. *Memórias do Instituto Oswaldo Cruz Rio de Janeiro* **97**(7) 941- 945.
- Mathis A, Weber R and Deplazes P (2005).** Zoonotic potential of the microsporidia. *Clinical Microbiology Review* **18**(3) 423-445.
- McLaughlin DJ, Hibbett DS, Lutzoni F, Spatafora JW and Vilgalys R (2009).** The search for the fungal tree of life. *Trends in Microbiology* **1** 7488-497.
- Mladineo I and Lovy J (2011).** A new xenoma – forming microsporidia infecting intestinal tract of Atlantic Bluefin tuna (*Thunnus thynnus*). *Act Parasitologica* **56**(4) 339-347.
- Moretto MM, Lawlor EM, Xu Y, Khan IA and Weiss LM (2010).** Purified PTP1 protein induces antigen – specific protective immunity against *Encephalitozoon cuniculi*. *Microbes and Infection* **12** 574-579.
- Mori H, Mahittikorn A, Thammasonthijaren N, Chaisiri K, Rojekittikhun W and Sukthana Y (2013).** Presence of zoonotic *Enterocytozoon bienersi* in cats in a temple in central Thailand. *Veterinary Parasitology*.
- Muller A, Bialek R, Kamper G, Fatkenbeuer G, Salzberger B and Franzen C (2001).** Detection of microsporidia in travelers with diarrhea. *Journal of Clinical Microbiology* **39** 1630- 1632.
- Notermans DW, Peek R, De Jong MD, Wentink – Bonnema EM, Boom E and Van Gool T (2005).** Detection and identification of *Enterocytozoon bienersi* and *Encephalitozoon* species in stool and urine specimens by PCR and differential hybridization. *Journal of Clinical Microbiology* **43**(2) 610- 614.
- Ozkan O, Ozkan AT and Zafer K (2011).** *Encephalitozoonosis* in New Zealand rabbits and potential of transmission risk. *Veterinary Parasitology* **179** 234-237.
- Petrie A and Watson P (2013).** Statistics for Veterinary and Animal Science 3rd edition, Blackwell Publishing Ltd, USA.

# **Research Article**

**Peuvel – Fanget I, Polonais V, Brosseau D, Texier C, Kuhn L, Peyret P, Vivares C and Delbac F (2006).** EnP1 and EnP2, two proteins associated with the *Encephalitozoon cuniculi* endospores, the chitin – rich inner layer of the microsporidian spore wall. *International Journal of Parasitology* **36** 309-318.

**Reabel S (2012).** Molecular diagnostic methods for detection of *Encephalitozoon cuniculi* in pet rabbits. A thesis presented to the University of Guelph in partial fulfillment of requirements for the degree of Master of Science in pathobiology, *Guelph Press Office*, Canada, December, 2012.

**Rodriguez – Tovar LE, Speare DJ and Frederick Markham RJ (2011).** Fish microsporidia immune response, immunomodulation and vaccination. *Fish and Shellfish Immunology* **30** 999-1006.

**Ryan NJ, Sutherland G, Coughlan K, Globan M, Doultree J, Marshall J, Baird RW, Pedersen J and Dwyer B (1993).** A new trichrome – blue stain for detection of Microsporidian species in urine, stool, and nasopharyngeal specimens. *Journal of Clinical Microbiology* **31** 3264-3269.

**Sak B, Salát J, Horká H, Saková K and Ditrich O (2006).** Antibodies enhance the protective effect of CD4+ T lymphocytes in SCID mice perorally infected with *Encephalitozoon cuniculi*. *Parasite Immunology* **28** 95–99.

**Salat J, Horka H, Sak B and Kopecky J (2006).** Pure CD4+ T lymphocytes fail to protect perorally infected SCID mice from lethal microsporidiosis caused by *Encephalitozoon cuniculi*. *Parasitological Researches* **99** 682-686.

**Salat J, Jelinek J, Chmelar J and Kopecky J (2008).** Efficacy of gamma interferon and specific antibody treatment of microsporidiosis caused by *Encephalitozoon cuniculi* in SCID mice. *Antimicrobial Agents and Chemotherapy* **52**(6) 2169-2174.

**Salat J, Kopecky J, Janeckova B and Ditrich O (2005).** Different routes of infection with *Encephalitozoon intestinalis* affect the development of immune response in immunocompetent and immunodeficient mice. *Acta Parasitologica* **50**(2) 180-188.

**Santin M, Vecino JCA and Fayer R (2010).** A zoonotic genotype of *Encephalitozoon bienersi* in horses. *Journal of Parasitology* **96** 157- 161.

**Shadduck JA, Watson WT, Pakes SP and Cali A (1979).** Animal infectivity of *Encephalitozoon cuniculi*. *Journal of Parasitology* **65** 123-129.

**Southern TR, Jolly CE, Lester ME and Hayman JR (2007).** EnP1, a microsporidian spore wall protein that enables spores to adhere to and infect host cells in vitro. *Eukaryotic Cell* **7** 1354-1362.

**Sulaiman IM, Fayer R, Yang C, Santin M, Matos O and Xiao L (2004).** Molecular characterization of *Enterocytozoon bienersi* in cattle indicates that only some isolates have zoonotic potential. *Parasitology Research* **92**(2) 328-334.

**Suvarna SK, Layton C and Bancroft JD (2013).** Bancroft's theory and practice of histological techniques. 7th edition, *Churchill Livingstone Press*, New York, USA.

**Valencakova A, Balent P, Petrovova E, Novotny F and Luptakova L (2008).** *Encephalitozoon* in household pet Nederland Dwarf rabbits (*Oryctolagus cuniculus*). *Veterinary Parasitology* **153** 265-269.

**Wagnerova P, Sak B, Kvetonova D, Bunatova Z, Civisova H, Marsalek M and Kvac M (2012).** *Enterocytozoon bienersi* and *Encephalitozoon cuniculi* in horses kept under different management systems in Czech Republic. *Veterinary Parasitology* **190** 573-577.

**Wagnerova P, Sak B, Kvetonova D, Marsalek M, Langrova I and Kvac M (2013).** Humoral immune response and spreading of *Encephalitozoon cuniculi* infection in experimentally infected ponies. *Veterinary Parasitology*.

**Wasson K and Peper RL (2000).** Mammalian microsporidiosis. *Veterinary Pathology* **37** 113-128.

**Weber R, Bryan RT, Qwen RL, Wilcox CM, Gorelkin L and Visvesvara GS (1992).** Improved light – microscopical detection of microsporidia spores in stool and duodenal aspirates. *New England Journal of Medicine* **326**(3)161- 166.

**Xiao L, Li L, Visvesvara GS, Moura H, Didier ES and Lal AA (2001).** Genotyping *Encephalitozoon cuniculi* by multilocus analyses of genes with repetitive sequences. *Journal of Clinical Microbiology* **39** 2248-2253.

**Xu Y, Takovorian P, Cali A, Wang F, Zhang H, Orr G and Weiss LM (2006).** Identification of a new spore wall protein from *Encephalitozoon cuniculi*. *Infection and Immunology* **74**(1) 239-247.