

## Case Report

# NON ROTATION IN HORSESHOE KIDNEY

Madhumita Mukherjee<sup>1</sup>, \*Jasveer James<sup>2</sup> and Robert James<sup>3</sup>

<sup>1</sup>Department of Anatomy, Christian Medical College, Ludhiana, India

<sup>2</sup>Department of Anatomy, Punjab Institute of Medical Sciences, Jalandhar, India

<sup>3</sup>Department of Medicine, Punjab Institute of Medical Sciences, Jalandhar, India

\*Author for Correspondence

## ABSTRACT

The objective behind the current study was to report and add on to the already existing data on Horseshoe kidneys. Horseshoe kidney encountered in an old female cadaver with - parenchymatous isthmus; anteriorly placed wide hilum on both sides along with a medially placed additional hilum on the right side; absence of typical pattern of calyces; and a pair of renal arteries above and below the isthmus arising from the abdominal aorta. The variation that we report may be helpful in planning and conducting surgical procedures on horse shoe kidneys.

An explanation for the presence of the above points is attempted and also cited as an example of incomplete division of the kidney.

**Key Words:** Horseshoe Kidney, Pelvis, Isthmus, Hilum

## INTRODUCTION

Horseshoe kidney is predisposed to blunt trauma, may be compressed or injured across lumbar vertebrae. The knowledge of the vascular anatomy and pelviureteral pattern is most helpful not only to the surgeons but also to the radiologists.

In the present study the authors present an interesting case of horseshoe kidney with

- Parenchymatous isthmus
- Right Renal artery arising 1cm higher than the Left Renal artery, the right arising from the anterior aspect and the left from the lateral aspect of the abdominal aorta.
- Left renal artery divides into superior and inferior divisions in contrast to the typical pattern (Standring, 2008).
- Double hila on the right side, upper hilum small and medially facing
- Anteriorly placed wide hila on both sides
- Tortuous, exposed segmental arteries
- Narrow exposed calyces
- Saccular pelvis

## RESULTS

The following results were noted in the present study

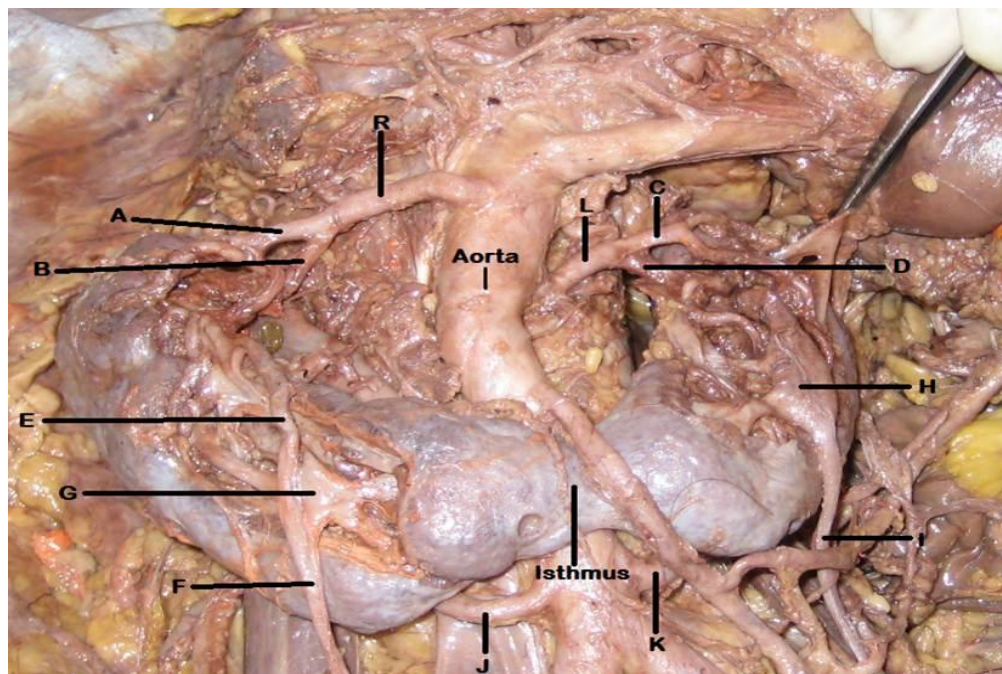
**Table 1: Showing various parameters of Horseshoe Kidney**

	Right kidney	Left kidney
<b>Supero-inferior Height</b>	8.5cm	9.5cm
<b>Number of Hila</b>	Two (Double) Upper: 2.5cm long, medially rotated. Lower: 4.5cm long, 2.5cm broad, anteriorly facing	One (Single) 4.5cm long 2.5cm broad Anteriorly facing
<b>Structures at the hila</b>	Upper hilum:	Hilum:

### Case Report

	<p>Anterior – Vein Middle – Dilated Funnel shaped Pelvis Posterior – Artery</p> <p><u>Lower hilum:</u></p> <p>i) 3 veins joining to form obliquely ascending renal vein ii) Segmental Arteries – 5 highly tortuous, exposed segmental branches of Renal Artery iii) Calyces – Narrow tubular calyces five in number opening into the pelvis iv) Saccular pelvis towards the lower part of the hilum receives narrow calyces and a ureter from the upper hilum which continues into a single ureter passing anterior to the isthmus.</p>	<p>Anterior - Vein 3 small veins joining to form obliquely placed Renal Vein ( crossing in front of Aorta to Inferior Vena Cava) Posterior – 4 highly tortuous, exposed segmental branches of Left Renal Artery</p> <p>Calyces: 5 narrow tubular calyces opening into saccular pelvis.</p> <p>Pelvis – Saccular and continues as the ureter passing anterior to the isthmus.</p>
<b>Segmental branches</b>	5	4
<p><b>Renal Artery Origin</b></p> <p><b>Level</b></p> <p><b>Length</b></p> <p><b>External diameter</b></p> <p><b>Branches</b></p>	<p>Anterior aspect of Abdominal aorta 1<sup>st</sup> Lumbar vertebra</p> <p>4.0cm 0.5cm Anterior &amp; Posterior divisions</p>	<p>Lateral aspect of Abdominal aorta 1<sup>st</sup> lumbar vertebra, lower border 4.5cm 0.5cm Superior &amp; inferior divisions</p>
<p><b>Accessory Renal Artery Origin</b></p> <p><b>Level</b></p> <p><b>Length</b></p> <p><b>External diameter</b></p> <p><b>Course</b></p>	<p>Abdominal aorta 3<sup>rd</sup> lumbar vertebra, just above bifurcation of Aorta 5.0 cm 0.5cm Upwards and enters the lower pole of the kidney posteriorly</p>	<p>Abdominal aorta 3<sup>rd</sup> lumbar vertebra, just above bifurcation of Aorta 4.0cm 0.5 cm Upwards and enters the lower part of the left kidney posteriorly</p>

## Case Report



**Figure 1: Picture showing the horseshoe kidney**

**R – Right renal artery**

**A-** Anterior division of Right Renal Artery

**B-** Posterior division of Right Renal Artery

**C-** Superior division of Left Renal Artery

**D-** Inferior division of Left Renal Artery

**E-** Ureter from upper hilum

**L – Left renal artery**

**F-** Right ureter

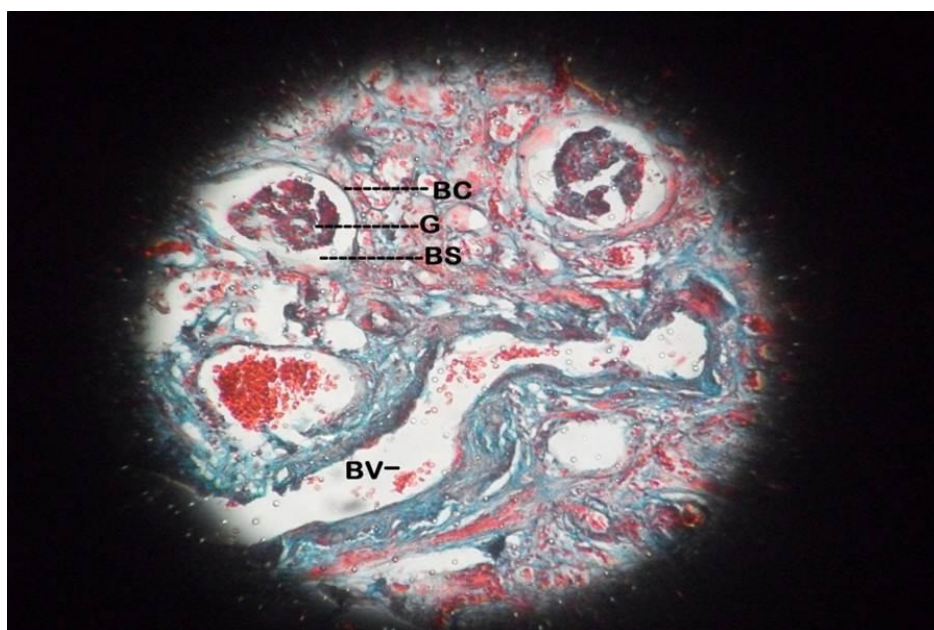
**G-** Right pelvis

**H-** Left pelvis

**I-** Left ureter

**J-** Right accessory artery

**K-** Left accessory artery



**Figure 2: Isthmus: Mason's trichrome stain**

*BC- Bowman's Capsule, G- Glomerulus, BS- Bowman's Space, BV- Blood vessel*

## Case Report

**Table 2: Isthmus**

<b>Level</b>	Anterior to L3 vertebra
<b>Transverse length</b>	3.5cm
<b>Supero-inferior height</b>	2.0cm
<b>Antero-posterior thickening</b>	0.5cm
<b>Relations</b>	Upper border – Inferior Mesenteric Artery Anterior surface – Left: Inferior Mesenteric Artery Right: Indented by the Ureter

## Histology of Isthmus

5mm sections taken through and through from isthmus were stained by haematoxylin and eosin stain and Mason's trichrome stain (Clayden, 1962).

*Parenchymatous:* Presence of Bowman capsule, Distal and Proximal convoluted tubules, large blood vessels.

## DISCUSSION

Right kidney is 1.0cm shorter than the Left kidney. Right side kidney show 2 hila separated by a band of nephric tissue 1cm broad. Though the upper hilum is small and medially facing, the arrangement of the structures here from before backwards is at variance with the typical arrangement.

The pelvis of the upper hilum continues into a narrow ureter which drains into the saccular pelvis of lower hilum indicating early division of the ureteric bud and incomplete division of the kidney on the right side (Moore and Persaud, 2009).

The parenchymatous isthmus of this HSK has come into being because of abnormal migration of posterior nephrogenic tissue (Rahilly and Muller, 2001) and the authors believe that this has led to:

Reduced amount of metanephric tissue in the lateral lip of the hilum for it to grow and undergo a so called medial rotation. Therefore the anteriorly facing hilum.

Reduced reciprocal induction between metanephric tissue and hilar divisions of ureteric bud (Hamilton *et al.*, 1976) resulting in marked reduction in the number of branches available to be assimilated to form dilated major and minor calyces. Instead there are formed narrow tubular calyces opening directly into the saccular pelvis.

Main Renal Arteries are accompanied by renal veins which course obliquely to the IVC while the lower pair is labeled Accessory Renal Arteries since they are not accompanied by veins (Sinnatamby, 2006). Their external diameter and length is approximately the same as that for the Main Renal Arteries.

The Left Renal Artery divides into superior and inferior division which is at variant to the typical pattern described (Strandring, 2008).

## REFERENCES

- Clayden EC (1962).** Practical Section Cutting And Staining. 4<sup>th</sup> edition JA Churchill Ltd London 76-87.
- Hamilton, Boyd and Mossman's (1976).** Human Embryology Prenatal Development Of Form and Function 4<sup>th</sup> edn. Macmillan Press Ltd London and Basingstoke Associated companies in New York Dublin Melbourne Johannesburg and Madras 377-394.
- Moore KL and Persaud TVN (2009).** The Developing Human Clinically Oriented Embryology, 8<sup>th</sup> edition Saunders Elsevier 253.
- O'Rahilly Ronan and Muller F (2001).** Human Embryology and Teratology. 3<sup>rd</sup> edition John Wiley and Sons, Inc., Publication New York, Chichester, Weinheim, Brisbane, Singapore, Toronto 305.
- Strandring S (2008).** Gray's Anatomy, The Anatomical Basis of Clinical Practice. 40<sup>th</sup> edition Edinburg, Churchill and Livingstone 1231-1233.
- Sinnatamby CS (2006).** Last's Anatomy, Regional and Applied. 11<sup>th</sup> edition Churchill Livingstone Elsevier Edinburgh London New York Oxford Philadelphia St Louis Sydney Toronto 296.