

Research Article

BILATERAL PETROUS INTERNAL CAROTID ARTERY ANEURYSMS PRESENTING WITH DIPLOPIA - A CASE REPORT

***Subhash Singla, Ankur Wadhera, Nittala Pramod Philip and Rajesh Chakravarti**

**Department of Radiodiagnosis, Christian Medical College and Hospital,
Ludhiana141008, India*

**Author for Correspondence*

ABSTRACT

The aneurysms of the extra-dural portions of the Internal Carotid Artery (ICA) are rare as compared to the intra-dural portions, with only few reported cases of bilateral petrous ICA aneurysms. We present one such case we encountered in a 63yr old man who came with complaints of bi-ocular diplopia for 1 year.

Key Words: *Petrous ICA, Aneurysm, CT Angiography, Diplopia*

INTRODUCTION

A 63 year old man, not a known hypertensive or diabetic, presented with symptoms of bilateral diplopia since the past one year. There is no history of prior head trauma, stroke or diminution of vision. He gives no history of smoking or drug abuse.

He was conscious and oriented and his vital signs were stable. Higher CNS functions were normal. He had bilateral diplopia, more on the left side, with relief on turning the head to the left side or with closing of the left eye.

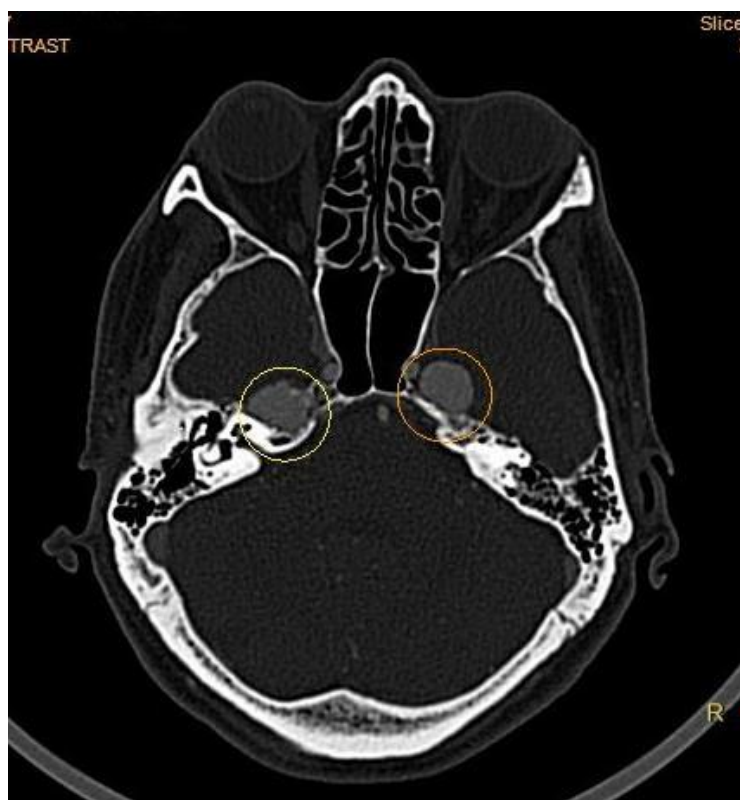


Figure1: Axial post contrast CT image in a bone window setting shows bilateral aneurysms at the petrous apex

Research Article

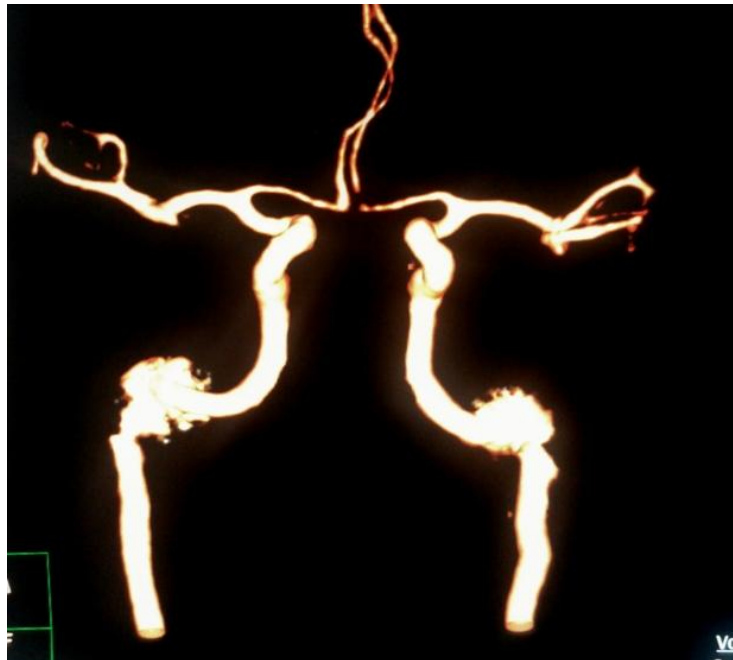


Figure 2: Volume rendered post processed CT angiography image shows the bilateral ICA aneurysms

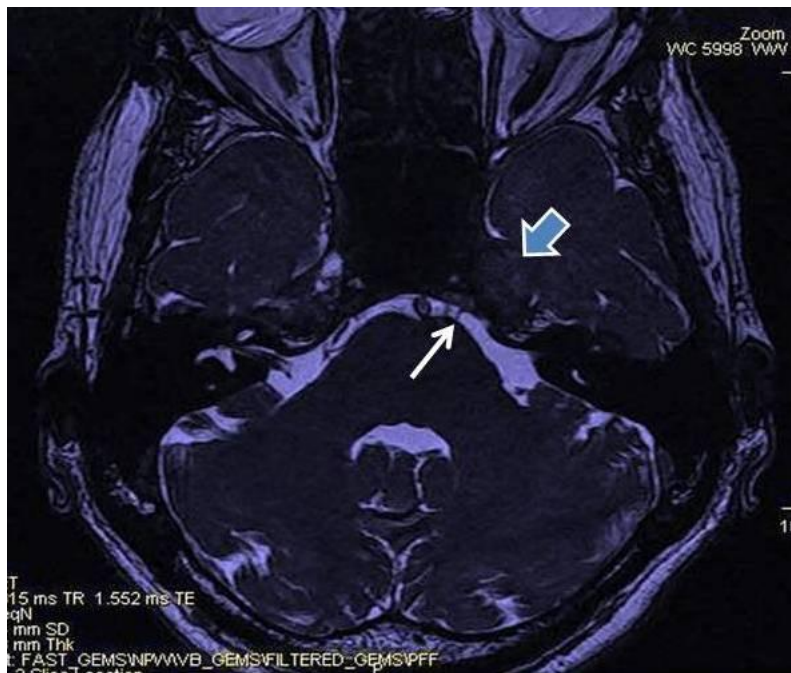


Figure 3: MR FIESTA image shows the aneurysm (thick short arrow) and the left abducens nerve (thin arrow) in the prepontine cistern

CT head with contrast was done which shows enhancing lesions in the medial portions of the temporal lobes with widening of the carotid canal and bony erosion of the left petrous apex (Figure 1). CT Angiography shows bilateral aneurysms of petrous portions of the ICA (Figure 2). Concurrent MRI high resolution FIESTA images reveal compression of the left trigeminal and abducens nerves by the left petrous ICA aneurysm (Figure 3).

Research Article

DISCUSSION

Vascular lesions involving the petrous segment of the extra-dural ICA are uncommon. This is because the petrous portion of the ICA is well protected within the bony carotid canal and the absence of vessel branches in this region. The most common cause of aneurismal formation in this location is following trauma. Aneurysms of the petrous ICA have also been reported following pituitary and sinus surgery and from gunshot injuries (Vasama *et al.*, 2001).

Mycotic aneurysms of the petrous ICA have been documented from bacterial and fungal infections and this has been postulated due to the close proximity of the intra-petrous ICA with the middle ear cavity (Tanaka *et al.*, 1998). In children, petrous aneurysms could be seen as part of congenital disorders such as neurofibromatosis, marfans syndrome and other connective tissue disorders.

Symptoms associated with petrous ICA aneurysms include headache, nasal congestion and midface pain. Otologic manifestations include conductive and sensorineural hearing loss and tinnitus (Reece *et al.*, 1999). Rupture as a presenting feature occurs in approximately 25% of cases with subsequent otorrhagia or epistaxis (Reece *et al.*, 1999 and Forshaw *et al.*, 2000). The triad of otorrhagia, epistaxis, and neurologic deficit is often seen in cases of ruptured petrous aneurysm.

Petrous aneurysms can be demonstrated on cross sectional imaging like CT or MRI. On CT, these usually appear as destructive lesions of the petrous bone oriented along the carotid canal. There is usually well-corticated expansion of the carotid canal. The differential diagnosis on CT for such an appearance will include cholesteatoma, chondrosarcoma, granulation tissue and aneurysms (Catherine *et al.*, 2003).

On MR imaging, the lesions demonstrate complex signal intensity owing to the turbulent flow within the aneurysm. There are regions of flow void and intense enhancement compatible with a vascular lesion. Differential diagnosis of such an appearance includes glomus jugulare or a high-riding jugular bulb.

The primary goal of management of petrous aneurysms is to provide symptomatic relief and to minimize the risks of thromboembolism and hemorrhage. Treatment of petrous aneurysms at present is by endovascular procedures like balloon occlusion or by stent placement. The success of the treatment depends upon the anatomy of the aneurysm, age of the patient, and existing co-morbidities.

Conclusion

Bilateral aneurysms of the petrous ICA are rare with only a handful of cases reported in literature thus far. Diplopia in our patient was because of lateral rectus palsy which is due to the compression of the bilateral sixth cranial nerves by the aneurysms as they exit the prepontine cistern near the petrous apex. Cross sectional imaging and knowledge of the various petrous apex lesions will help in reaching to correct diagnosis.

REFERENCES

- Vasama JP, Ramsay H and Markkola A (2001).** Petrous Internal Carotid Artery Pseudoaneurysm due to Gunshot Injury. *Annals of Otolaryngology, Rhinology, and Laryngology* **110** 491-493.
- Tanaka H, Patel U, Shrier DA and Coniglio JU (1998).** Pseudoaneurysm of the Petrous Internal Carotid Artery after Skull Base Infection and Prevertebral Abscess Drainage. *American Journal of Neuroradiology* **19** 502-504.
- Reece PH, Higgins N, Hardy DG and Moffat DA (1999).** An Aneurysm of the Petrous Internal Carotid Artery. *Journal of Laryngology and Otology* **113** 55-57.
- Forshaw MA, Higgins N, Hardy DG and Moffat DA (2000).** Rupture of an Internal Carotid Artery Aneurysm in the Petrous Temporal Bone. *British Journal of Neurosurgery* **14** 479-482.
- Catherine JH, Gul M and Robert WH (2003).** Bilateral Petrous Internal Carotid Artery Pseudoaneurysms presenting with Sensorineural Hearing Loss. *American Journal of Neuroradiology* **24** 1139-1141.