

Research Article

SHORT MUSCULOCUTANEOUS NERVE AND UNUSUAL INNERVATION OF MEDIAN NERVE

***A. HimaBindu and B. Narsinga Rao**

*Department of Anatomy, Maharajah's Institute of Medical Sciences,
Nellimarla, Vizianagaram, Andhra Pradesh, India*

**Author for Correspondence*

ABSTRACT

The muscles of upper limb are innervated through the branches of brachial plexus. Variations in the formation and branching of the brachial plexus are common and the communications between musculocutaneous and median nerve were described since nineteenth century. The present variation was found in a 65year old male cadaver during routine dissection for undergraduate students. There is an unusual formation of median nerve through a small lateral root and normal medial root. The musculocutaneous nerve after giving a branch to coracobrachialis joined the median nerve in the middle of the arm and the muscles of the arm are getting their motor innervations through median nerve. So knowledge of anatomical variations of these nerves at the level of upper arm is essential while performing surgeries in the axilla and surgical neck of humerus.

Key Words: *Axilla, Brachial Plexus, Median Nerve, Musculocutaneous Nerve*

INTRODUCTION

The upper limb is getting sensory and motor innervations through the branches of brachial plexus. Plexus is a complex of branching, reunion and reseparation of nerve fibres that usually happens near the root of limbs (Sontakke 2011). In the upper limb it occurs in the axilla. Due to this complex formation of brachial plexus, variations are frequently reported. Of these communications between musculocutaneous nerve and median nerve are most common.

Musculocutaneous nerve is a branch of lateral cord along with lateral pectoral nerve and lateral root of median nerve. The median nerve (MN) is formed from two roots, a medial root from medial cord and a lateral root from lateral cord of brachial plexus. In the present case, median nerve was formed by small lateral root (LRM) that passed anterior to third part of axillary artery (AA) and joined with medial root of median nerve (MRM) forming median nerve medial to the axillary artery. The musculocutaneous nerve supplied the coracobrachialis (CBM) and joined the median nerve on the anterior aspect of brachial artery. The muscles of front of arm were innervated by the median nerve. Knowledge of communications between musculocutaneous nerve and median nerve are valuable in traumatology of shoulder joint and in repair operations (Haeri 1982). The close relationship of the variant lateral root of the median nerve with the axillary artery may result in the arterial compression leading to ischaemic pain during certain postural maneuvers of the shoulder joint (Saeed 2003).

CASES

During routine dissection for undergraduate students, a variation in the formation of median nerve was found on the right side in a 65year old male cadaver. The median nerve was formed by a small lateral root and normal medial root in relation to the third part of axillary artery. The musculocutaneous nerve that is coming from lateral cord was thick and it supplied the coracobrachialis without piercing it (Figure 1).

Later it joined the median nerve in the middle third of the arm. This nerve was formed superficial to the brachial artery. After its formation in the middle of the arm, the median nerve gave two branches, which are coming from its lateral side. One branch innervated biceps brachii and another branch bifurcated into a motor branch to brachialis and a branch that passed between biceps and brachialis and continued as lateral cutaneous nerve of forearm (Figure 2). So this combined nerve supplied all muscles of the front of

Research Article

arm except coracobrachialis. A few centimeters above the elbow the median nerve passed from anterior to the medial side of the brachial artery.

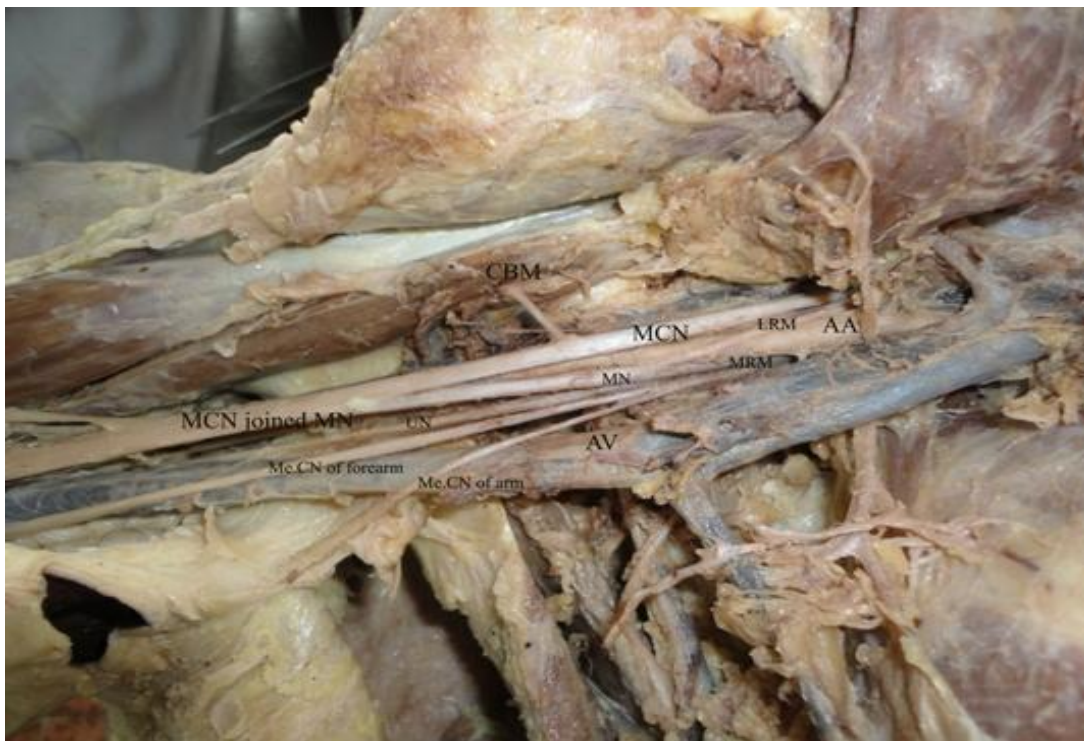


Figure 1: Showing small lateral root of MN and joining of MCN with MN

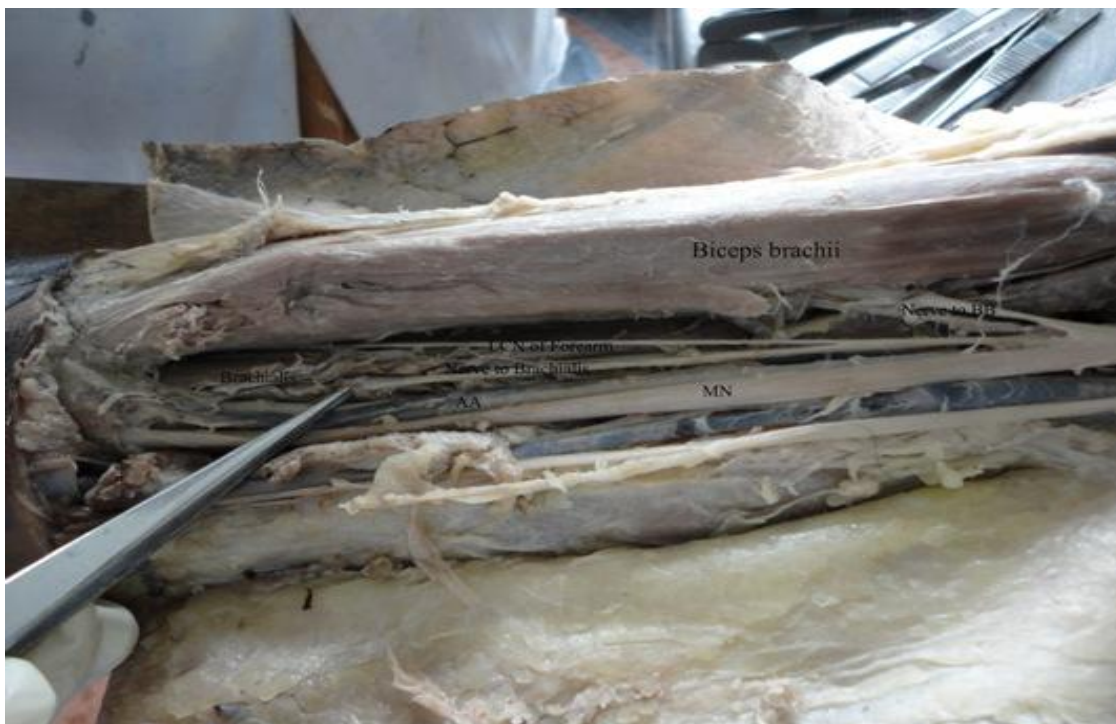

Figure 2: Showing MN innervating the flexor muscles of arm

Research Article

DISCUSSION

Normally the musculocutaneous nerve arises from lateral cord of brachial plexus but it has frequent variations. The nerve may be doubled, unusually short or even absent (Arora 2005).

The median nerve has two roots from the medial and lateral cords.

Some fibres of the median nerve ran along with the musculocutaneous nerve which after traversing some distance leaves the latter to join the parent trunk. (William1995). So the communications between median nerve and musculocutaneous nerve are common.

The communications are classified into five types (Le Minor1992):

Type I: No communication between median nerve and musculocutaneous nerve.

Type II: The fibres of medial root of median nerve pass through the musculocutaneous nerve and join the median nerve in the middle of the arm.

Type III: The fibres of lateral root of median nerve pass along the musculocutaneous nerve and after some distance leave it to form the lateral root of median nerve.

Type IV: The musculocutaneous fibres join the lateral root of the median nerve and after some distance musculocutaneous nerve arises from the median nerve.

Type V: The musculocutaneous nerve is absent and the entire fibres of musculocutaneous nerve pass through the lateral root and fibres to the muscles supplied by musculocutaneous nerve branch out directly from the median nerve.

It was found that if the lateral root of median nerve was small, the musculocutaneous was connected with the median nerve in the arm (Strandberg 2005). A study on ten cadavers mentioned failure of separation of musculocutaneous nerve from the median nerve and the latter gave the branches that arise from musculocutaneous nerve (Guha2005). As the roots of MCN and lateral root of median nerve are same, in the absence of MCN the muscles of front of arm are getting motor innervations by median nerve (Sontakke, 2011). The limb musculature is observed in the seventh week of intrauterine life opposite the lower cervical and upper thoracic segments. The ventral primary rami form plexus divide into dorsal and ventral branches, which unite to form peripheral nerves to supply the flexors and extensor group of muscles. The axons of spinal nerve grow distally to reach the limb bud mesenchyme (Brown 1991). The peripheral process of motor and sensory neurons grow in the mesenchyme in different directions. This is regulated by chemo attractants and chemorepulsants in a highly coordinated site specific fashion. Any alterations in signaling between mesenchymal cells and neuronal growth cones lead to variations (Sanes, 2000).

CONCLUSION

Variant nerves, in terms of origin and distribution are usually prone to injuries. Knowledge of variations of brachial plexus help the clinicians to prevent injury to these nerves while performing surgeries in the axilla. As these nerves are in close relation with the axillary artery, variant lateral root may cause arterial compression leading to ischemic pain.

REFERENCES

Arora L, Dhillon R (2005). Absence of musculocutaneous nerve and accessory head of biceps brachii: A case report. *Indian Journal of Plastic Surgery* **38**(2) 144-146.

Arora L, R Dhillon(2005) Absence of musculocutaneous nerve and accessory head of biceps brachii: A case report *Indian Journal of Plastic Surgery* **38**(2)144-146

Brown, M.C., Hopkins, W.G. and Keynes, R.J.(1991): Axon guidance and target recognition in : Essentials of neural development. *Cambridge University Press* Cambridge 46-66.

Guha R and Palit S(2005) - A rare variation of anomalous median nerve with absent musculocutaneous nerve and high up division of brachial artery. *Journal of Interacademia* **9**(3) 398-403.

Haeri, G.B. and Wiley, A.M. (1982): Shoulder impingement syndrome, results of operative release. *Clinical Orthopaedic* 168 128-132.

Research Article

Le Minor, J.M. (1992): A rare variant of the median and musculocutaneous nerves in man. *Archives Anatomy Histology Embryology* 73 33-42.

Saeed M, Rufai AA Median and musculocutaneous nerves(2003): variant formation and distribution. *Clinical Anatomy* 16(5) 453-7.

Sanes HD, Reh TA, Harris WA(2000). Development of the nervous system. 1st Ed. New York, Academic Press. 189–197.

Sontakke BR, Tarnekar AM, Waghmare JE, Ingole IV (2011)An unusual case of asymmetrical formation and distribution of median nerve, *International Journal of Anatomical Variations* 4 57-60.

Standring S, Ellis H, Healy JC, et al (2005)- *Gray's Anatomy*. In: General organisation and surface anatomy of the upper limb. 39th ed. Philadelphia Elsevier Churchill Livingstone, 803-804

Williams, P.L., Bannister, L.H., Berry, M.M., Collins, P., Dyson, M., Dussek, J.E. and Ferguson, M.W.J(1995) *Gray's Anatomy* In: Nervous system. 38th Edn; Churchill Livingstone. Edinburgh 1266-1274.