

Research Article

TOXICOLOGICAL EFFECT OF METANIL YELLOW ON THE TESTIS OF ALBINO RAT

***R. Sarkar and A. R. Ghosh**

Dept. of Environmental Science, The University of Burdwan, Burdwan – 713 104, W.B.

**Author for Correspondence*

ABSTRACT

Metanil Yellow, a monosodium salt of 3[[4(Phenylamino)phenyl]azo]benzene-sulfonic acid which is used in the textile, tannary industry for dyeing and colouring purposes had shown its chronic toxic effects on the testis of albino rat when they were given at a dose of 3.0 g/kg body weight with pellet diet everyday for a period of 30 as well as 45 days. Degenerations were shown in the seminiferous tubules and in the spermatocytes and vacuolations were also shown in the sertoli cells.

Key Words: *Metanil Yellow, Testis, Albino rat (*R. norvegicus*), Chronic toxicity*

INTRODUCTION

The increasing demand for food by an ever-increasing world population and for ready-to-eat foods resulting from changes in lifestyles in developed societies has necessitated the use of chemical additives to help preserve nutritionally fortify, and process the foods. Colour is a quality of foods that makes them visually acceptable and aids in their recognition. Foods containing added colours include candy and confections; bakery goods; soft drinks; cereals; dairy products such as butter, ice cream, and sherbet; margarine; snacks; jams and jellies; and desert powder. The colour additive Metanil Yellow (MY) is principally a non-permitted colour. The present investigation is carried out the toxic effect of MY on the testis of albino rat (*R. norvegicus*).

MATERIALS AND METHODS

Albino rats (*R. norvegicus*) in the age group of 2-3 months weighing 120-250 g were allowed to acclimatize to laboratory conditions for one week. Then the rats were divided into both control and two experimental groups. Rats of both control and treated groups were maintained on rat pellet diet. The rats of experimental groups were given 3.0 g/kg body weight of Metanil Yellow (MY) for 30 as well as 45 days. The rats of both control and treated were sacrificed under chloroform anesthesia and the testes were taken out and fixed in Bouin's fixative for 24 hours for histopathological study. Paraffin sections were cut at 4-5 micron and stained in Delafield's Haematoxylin and Eosin solution.

RESULTS AND DISCUSSION

Control

The testis under control condition showed normal seminiferous tubules, spermatogonia and spermatocytes (Figure 1.1). Sertoli cells were also found in good condition (Figure 1.2).

Experimental Group I:

(3.0 g/kg body weight for 30 days): The testis of albino rat after an exposure of 30 days in Metanil Yellow showed some changes. Degeneration occurred in the seminiferous tubules as well as spermatogonia (Figure 2.1). Vacuolations were found in the sertoli cells (Figure 2.2).

Experimental Group II:

(3.0 g/kg body weight for 45 days): Maximum changes were found in the testis of albino rats after an exposure of 45 days in non-permitted food colour Metanil Yellow (MY). The seminiferous tubules were necrosed (Figure 3.1) and pycnotic spermatocytes and highly vacuolated sertoli cells were also found (Figure 3.2).

Research Article

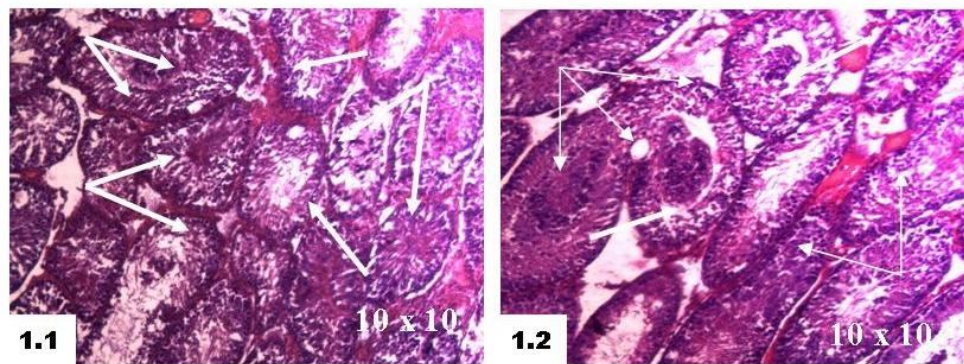


Figure 1: Micrographs of testis sections (4-5 μ m) stained with hematoxylin and eosin (HE).
 1.1 - Normal histological appearance of testis of control rat showing seminiferous tubules, spermatogonia and spermatocytes (Normal thick and thin arrows). The original magnification: [10x10].
 1.2 - Control testis with normal Sertoli cells (Normal thick and thin arrows). The original magnification: [10x10].

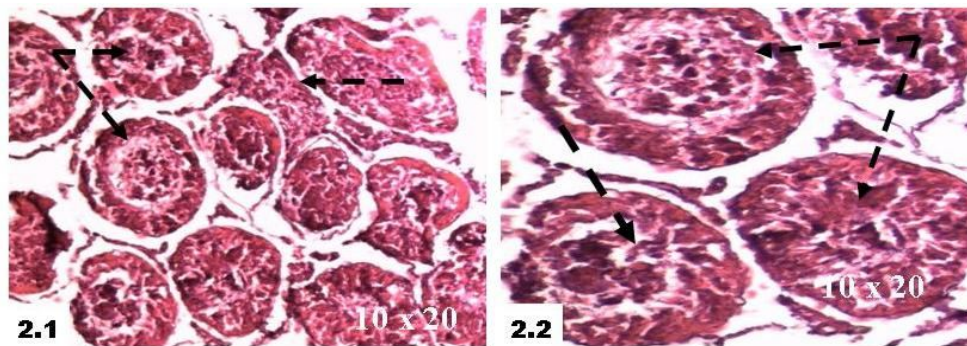


Figure 2: Micrographs of testis sections (4-5 μ m) stained with hematoxylin and eosin (HE).
 2.1 - Degenerated seminiferous tubules and spermatogonia (Broken thick and thin arrows). The original magnification: [10x20].
 2.2 - Highly vacuolated sertoli cells (Broken thick and thin arrows). The original magnification: [10x20].

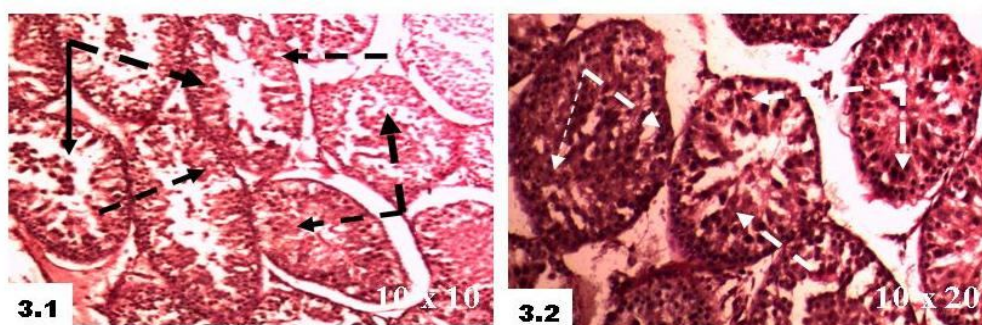


Figure 3: Micrographs of testis sections (4-5 μ m) stained with hematoxylin and eosin (HE).
 3.1 - Necrosed seminiferous tubules (Broken thick and thin arrows).The original magnification: [10x10].
 3.2 - Pycnotic spermatocytes and highly vacuolated sertoli cells (Broken thick and thin arrows).The original magnification: [10x20].

Research Article

Colour is one of the first and most important sensory qualities and it helps us to accept or reject particular foods. Colour is important in consumer perception of a food and it is often associated with a specific flavour and intensity of flavour. Metanil Yellow has been shown to cause testicular damage in gametogenic elements in guinea pigs, rats and mice (Khanna and Das, 1991). Colours are used in food for centuries to increase Consumers acceptability (Dixit *et al.*, 1995). The present study was undertaken to investigate the effect of Metanil Yellow on the testis of albino rats when administered MY as 3.0 g/kg body weight for a period of 30 as well as 45 days. Metanil Yellow has shown its serious effect on the sperm morphology, count and testicular weight (Mathur *et al.*, 2005b). Erythrosine has shown its potential toxic effect on spermatogenesis in mice when given 68-1360 mg/kg/day by gavage (Abdel Aziz *et al.*, 1997). The chronic toxicity of non-permitted food colour Metanil Yellow (MY) at a dose of 2.0 g/l for an exposure of 45 days on teleostean cat fish *Heteropneustes fossilis* has shown histopathological as well as ultrastructural changes in stomach, intestine, liver and kidney of *H. fossilis* (Sarkar and Ghosh, 2010).

ACKNOWLEDGEMENT

Thanks are due to Dr Naba Kumar Mondal, Assistant Professor and Head of the Department of Environmental Science, The University of Burdwan, Burdwan for necessary laboratory facilities.

REFERENCES

- Abdel Aziz AH, Shouman SA, Attia AS and Saad SF (1997).** A Study on the reproductive toxicity of erythrosine in male mice. *Pharmacological Research* **35(5)** 457-462.
- Dixit S, Pandey RC, Das M and Khanna SK (1995).** Food quality surveillance on colours in eatables sold in rural market of Uttar Pradesh. *Journal of Food Science and Technology* **32** 373-376.
- Khanna SK and Das M (1991).** Toxicity, carcinogenic potential and clinical Epidemiological studies on dyes and dyes intermediates. *Journal of Scientific and Industrial Research* **50** 964-974.
- Mathur N, Mehta M and Chaudhary V (2005b).** Sperm Abnormality Induction by Food Colour Metanil Yellow. *Journal of Ecophysiology and Occupational Health* **5** 157-160.
- Sarkar R and Ghosh AR (2010).** Metanil Yellow, A Food Additive, Induces the responses at Cellular and Sub-cellular Organisations of Stomach, Intestine, Liver, and Kidney of *Heteropneustes fossilis* (Bloch). *Pollution Research* **29(3)** 453-460.