

**Review Article**

## **HETEROTOPIC PREGNANCY: A DIAGNOSIS WE SHOULD SUSPECT MORE OFTEN**

**\*Sudha R, Umashankar KM, Sujata Datti N, Ramesh G and Jayanta Kumar DE**

*Department of OBG, MVJ Medical College and Research Hospital, Hoskote, Bangalore*

*\*Author for Correspondence*

### **ABSTRACT**

Heterotopic pregnancy is rare. Heterotopic Pregnancy occurs in < 1/ 30,000 pregnancies in natural conception and about 0.08% of all pregnancies. With artificial reproductive techniques, this incidence increases to between 1/100 to 1/500. Pregnancy test should be performed on all women of reproductive age who present with abdominopelvic pain and or vaginal bleeding. It's important to perform ultrasonography before termination of early pregnancy. A high index of suspicion should be raised in instances of acute pelvic pain in the face of documented intra uterine pregnancy. Conservative treatment can be done in unruptured Heterotopic pregnancies whereas operative management is the main stay in women with ruptured ectopic in the presence of intrauterine pregnancy.

We report two cases of Heterotopic pregnancy in a rural medical college in one year duration.

**Key Words:** *Heterotopic Pregnancy, Artificial Reproductive Technique*

### **INTRODUCTION**

Naturally occurring Heterotopic pregnancy is rare. It was first described by Duverney in 1708 at autopsy but now is diagnosed more in life. In natural conception cycles Heterotopic pregnancy is a rare event occurring in < 1/ 30,000 pregnancies. It occurs in about 0.08% of all pregnancies.<sup>6</sup> With Artificial reproductive techniques. However, this incidence increases to between 1/100 to 1/500. Patients usually present with amenorrhea followed abdominopelvic pain and or vaginal bleeding. A high index of suspicion should be raised in instances of acute pelvic pain in the face of documented intra uterine pregnancy. Ultrasonography has to be done to rule out Heterotopic pregnancy. Conservative treatment can be done in unruptured Heterotopic pregnancies whereas operative management is the main stay in women with ruptured ectopic in the presence of intrauterine pregnancy. We report two cases of Heterotopic pregnancy in a rural medical college within a span of one year.

### **CASES**

#### **Case 1**

A 25 yr old Gravida 3 Para 1 Living 1 Abortion 1 with 5 weeks amenorrhea presented to us on 13/07/ 2011. She came for pregnancy termination after failed termination with medical method. Her urine pregnancy test was positive. Her obstetric history revealed that she was married for last 4 yrs. Her first pregnancy ended as spontaneous abortion at 16 weeks and second pregnancy outcome was term normal delivery one and half years back. Her previous cycles were regular and her last menstrual period was on 07/06/2011. There was no history of vaginal bleeding, recurrent vaginal discharge or lower abdominal pain.

On examination her pulse was 74/min and Blood pressure was 110/70 mm Hg. Systemic examination was found to be normal. Abdomen was soft with no distension. Her complete blood count report was within normal limits with hemoglobin of 13.4g/dl. Her blood group was B positive. She was subjected to ultrasound examination of the pelvis which revealed a 0.4 cm intrauterine gestational sac corresponding to 4 weeks 3 days gestation and a mixed echogenic lesion (gestational sac like structure) measuring 2 \* 1.9 cm in the left adnexa adherent to left ovary along with significant free fluid in the pouch of Douglas. With this a diagnosis of Heterotopic pregnancy was made. Her initial  $\beta$ - HCG value was found to be 188m IU/ml. She was admitted and monitored for vitals and increase in the abdominal girth. Repeat serum  $\beta$ -

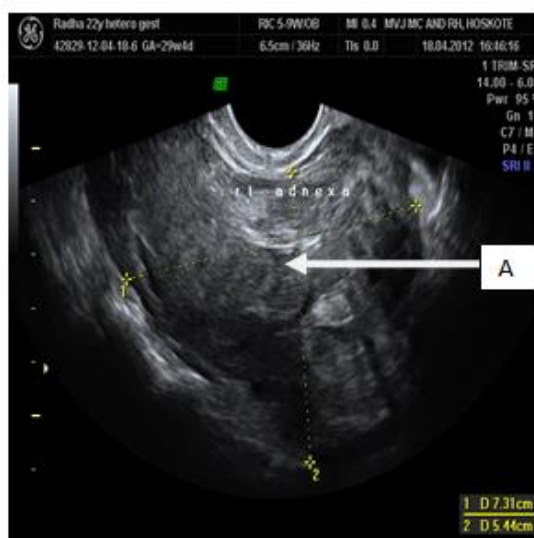
## Review Article

HCG after 48 hrs was found to be 1895m IU/ml. A decision for medical termination of ectopic pregnancy and surgical evacuation of the intrauterine pregnancy was made after discussing with patient and her husband. Her liver function tests and renal function tests were normal. She underwent dilatation and evacuation with no complications on 20/07/2011 and products were sent for histopathological examination. Methotrexate injection 45 mg was given intramuscularly on 20/7/2011 followed by leucovorin 5 mg injection 24 hrs later for the treatment of ectopic pregnancy. Antibiotics were started. Serum B – HCG was done 48 hrs later which was found to be 265.48 m IU/ml. Repeat pelvic ultrasound showed normal study. Patient was discharged and followed up with weekly urine pregnancy test. Urine pregnancy test was negative at 5 weeks.

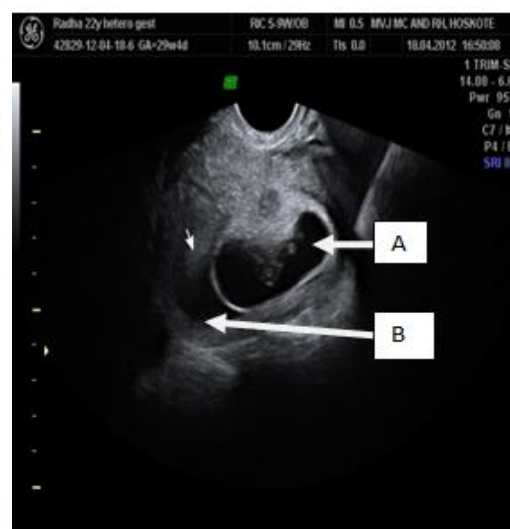
### Case 2

25 year old Primigravida with 8 weeks of amenorrhea presented to us on 18/04/2012. She came with history of pain in the lower abdomen since 2 hrs sudden in onset and increasing since then and continuous. She also gave history of spotting per vagina, reddish brown in color staining the clothes since 22hrs prior to admission. Her obstetric history revealed that she was married for the last 5 yrs, and she was evaluated for infertility. This conception was in acromiphene induced cycle. Ultrasound scan of the pelvis was done a day prior to admission which revealed features suggestive of Heterotopic pregnancy. Her last menstrual period was on 17/02/2012.

On examination she had mild pallor. Her pulse rate was 80 beats per minute and blood pressure was 110/70 mmHg. Systemic examination was normal. Abdomen was soft, no distension and non-tender. She was subjected to an ultrasound examination of the abdomen and pelvis which revealed single live intrauterine gestation of 8 weeks 3 days +/- 5 days with perisac bleeding as depicted in figure 1. Right adnexa findings were suggestive of ectopic gestation with hematoma and hem peritoneum of around 300 ml. Figure 2 shows ultrasound picture of right adnexa. She was resuscitated with crystalloids. Her investigations revealed hemoglobin 8.7gm/dl and other parameters being normal. She was taken up for emergency laparotomy under spinal anesthesia. Intra operative findings were blood clots 100gms, haemoperitoneum 300 ml. Uterus was 10 weeks size, right isthmus ruptured ectopic gestation of 4x2 cm. Left fallopian tube was normal. Figure 3 shows intraoperative findings. Both ovaries were polycystic. Right sidesalpingectomy was done and specimen sent for histopathology.

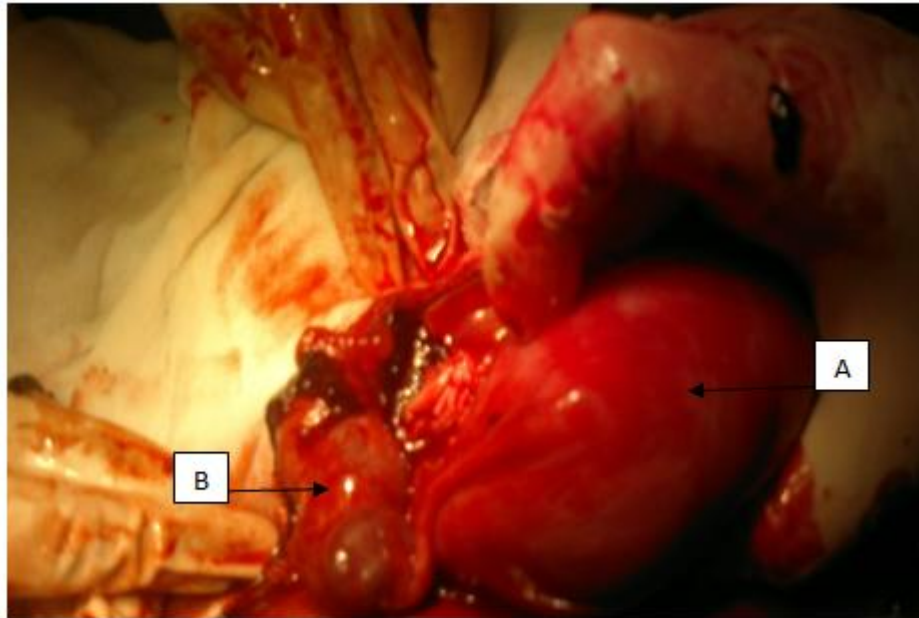


**Figure 1: Shows Ultrasound Picture**  
A: Intrauterine Gestation



**Figure 2: Shows Right Adnexal Findings**  
A: Right Adnexa with Hematoma; B: Perisac Bleeding

### **Review Article**



**Figure 3: Shows Intraoperative Findings**

**A.** Bulky uterus

**B.** Right Tubal Ruptured Ectopic Gestation

One unit of whole blood was given in post-operative period and post-operative period was uneventful. HPE report revealed features consistent with ruptured ectopic pregnancy. Repeat USG on 26-4-2012 showed single live intra uterine gestation of 9 weeks and 6 days. At present patient is 27 weeks 3 days gestation and is attending antenatal clinic at our hospital.

### **DISCUSSIONS**

Heterotopic pregnancy was first described by Duverny in 1708. Traditionally this was believed to be a rare condition. However recent studies suggest that the frequency may be higher, especially in patients undergoing assisted reproduction as high as one in 7,963 to one in 900 reported.<sup>5</sup> It may manifest as an intrauterine pregnancy in conjunction with bilateral tubal ectopic pregnancies, tubal abortion, or even with a concomitant Adnexal (ovarian) mass separate from the pregnancies. There is also a report of Heterotopic pregnancy in association with a term gestation. Thus, a real diagnostic dilemma exists.

There are several aspects of both of these cases presented that need to be addressed. In case report on the patient came for termination of pregnancy and Heterotopic pregnancy was diagnosed on ultrasound in an asymptomatic patient. Management was straight forward as the patient wanted termination of pregnancy. In this case diagnosis was made with the help of transvaginal sonography (TVS). However the sensitivity of TVS in diagnosing Heterotopic pregnancy is only 56% at 5-6 weeks.<sup>3</sup> the second case was conception in a clomiphene induced cycle. Patients taking fertility agents such as clomiphene citrate, are at increased risk for Heterotopic pregnancy since multiple ovulations occur in these instances.<sup>2</sup> this patient presented with pain abdomen and spotting per vagina. four common presenting signs and symptoms, abdominal pain, Adnexal mass, peritoneal irritation and an enlarged uterus are defined in the literature. Abdominal pain was reported in 83%, hypovolemic shock with abdominal tenderness was reported in 13% of the Heterotopic pregnancies.

The management of Heterotopic pregnancy still remains controversial. Operative management is still a main stay but involves surgical and anesthetic risk to the mother and fetus. Although it has been reported that laparotomy does not seem to interrupt intrauterine pregnancy, others have reported a 40% loss of

## **Review Article**

viable fetuses. An index of suspicion should be raised in patients presenting with abdominopelvic pain in the face of confirmed intrauterine pregnancy, particularly in those having undergone ovulation induction or having participated in IVF programs, since both modalities markedly increase the likelihood of Heterotopic pregnancy.

## **CONCLUSIONS**

The literature reveals that Heterotopic pregnancy is much more common than once believed, especially in those patients who have undergone ovulation induction or having participated in assisted reproductive techniques. Pregnancy test should be performed on all women of reproductive age who present with abdominopelvic pain and or vaginal bleeding. It's important to perform ultrasonography before termination of early pregnancy. A high index of suspicion should be raised in instances of acute pelvic pain in the face of documented intra uterine pregnancy. Conservative treatment can be done in unruptured Heterotopic pregnancies whereas operative management is the main stay in women with ruptured ectopic in the presence of intrauterine pregnancy.

## **REFERENCES**

**Demirel LC, Bodur H, Selam B, Lembet A and Ergin T (2009).** Laparoscopic management of Heterotopic cesarean scar pregnancy with preservation of intrauterine gestation and delivery at term: case report. *Fertile Sterile* **91** 1293.

**Divry V, Hadj S, Bordes A, Genod A and Salle B (2007).** Case of progressive intrauterine twin pregnancy after surgical treatment of cornual pregnancy. *Fertile Sterile* **87** 190.

**Dundar O, Tutuncu L, Mungen E and Yergok YZ (2006).** Heterotopic pregnancy: Tubal ectopic pregnancy and mono chorionic mono amniotic twin pregnancy: A case report. *Perinatology Journal* **14** 96-100.

**Glassner MJ, Aron E and Eskin BA (1990).** Ovulation induction with clomiphene and rise in Heterotopic pregnancies. *Journal of Reproductive medicine* **35** 175-178.

**James D Perkins, Mark R Mitchell (2004).** Heterotopic pregnancy in a large inner-city hospital: A report of two cases. *Journal of the National medical association* **96**(3) 363-366.

**Karim ISBN Majdoub Hassani, Abderrahim EI Bouazzaoui, Mohammed Khatouf and Khalid Mazaz Heterotopic pregnancy (2010).** A diagnosis we should suspect often. *Journal of Emergencies and Shock* (3) 304.

**Louis Sylvestre C, Morice P and Chapron C (1997).** The role of laparoscopy in the diagnosis and management of Heterotopic pregnancies. *Human Reproduction* **12** 1100-1102.

**Reece EA, Petrie RH, Sirmans MF, Finster M and Todd WD (1983).** Combined intrauterine and extra uterine stations: a review. *American Journal of Obstetrics and gynecology* **146** 323-330.