

EFFECT OF ETHANOL LEAF EXTRACT OF *CROTON LOBATUS* ON INDOMETHACIN-INDUCED GASTRIC ULCERATION IN ALBINO RATS

Ezugwu H.C^{1,2}, Anosike A.C¹, Berinyuy E.B³, *Dasofunjo K^{1, 4}, Ezugwu M.U⁵ and Achu H.O²

^{1,2}Department of Biochemistry, University of Nigeria, Nsukka, Nigeria

²Department of Chemical Sciences, University of Mkar, Mkar, Benue State, Nigeria

³Faculty of Medicine and Biomedical Sciences, University of Yaounde 1, Cameroun,

^{1,4}Department of Medical Biochemistry, Cross River University of Technology, Okuku Campus

⁵Department of Polymer and Textile Engineering, Federal University of Technology, Owerri, Imo State

*Author for Correspondence: dasokay22@gmail.com

ABSTRACT

Croton lobatus leaf is said to possess anti-oxidant property with healing effects on many experimental toxic injuries. The possible effect of *Croton lobatus* leaf extract on indomethacin-induced gastric ulceration in albino rats was investigated. The percentage yield of the extract was determined to be 24.67% and the extract showed the presence of alkaloids, saponin, steroid, flavonoids, tannin, anthraquinone, terpenoid and polyphenols. A dose of 2000 mg/kg body weight was found to be safe in the LD₅₀ study of the extract. A total of 25 albino rats weighing 120-150g were selected for this study and randomly divided into five groups of five animals per group. Animals in group i (normal control) was served feed and normal saline only, group ii animals (ulcerated control) was once administered 30mg/kg body weight indomethacin prior to 24hrs fasting. Group iii (standard control) was treated with 20mg/kg body weight omeprazole for 21 days after induction with 30mg/kg body weight indomethacin, groups iv and v were treated with 100mg/kg body weight and 200mg/kg body weight *Croton lobatus* leaf extract respectively for 21 days. Animals in group ii were sacrificed 4 hours after induction and those in groups i, iii, iv and v were sacrificed on the 22nd day. The ulcer index, the gastric volume and the pH of gastric juice were investigated. Animals in group iv showed a non-significant decrease ($p > 0.05$) in the ulcer index, while those in group V showed significant ($p < 0.05$) decrease in the ulcer index and gastric volume (7.25mm², and 5.76ml respectively) when compared with the ulcerated control rats (group ii) (21.52mm² and 14.71ml respectively). The pH level of the induced and treated (group iii, iv, v) animals was observed to be significant ($p < 0.05$) higher when compared to the group ii animals. The findings of this study expressed attenuation of gastric affronts of indomethacin by ethanol leaf extracts of *Croton lobatus*, which is indicative of the gastroprotective potential of the extract in albino rats.

Keywords: Flavonoids, ulceration, nonsteroidal anti-inflammatory drugs, pH, gastric juice, gastroprotective

INTRODUCTION

An ulcer is defined as disruption of the mucosal integrity of the stomach and/or duodenum leading to a local defector excavation due to active inflammation (Del Valle, 2005). Ulceration occurs due to the auto digestion of mucosa by gastric secretions such as pepsin and HCL (Satyanarayana *et al.*, 2006). The most common sites for ulcer are the stomach and the first few centimetres of the duodenum. Mostly ulcers are named after the location where they are found but peptic ulcer is an exception because it can be found anywhere in the stomach, oesophagus or duodenum. When a peptic ulcer is in the stomach it is called gastric ulcer. The aetiology of gastro duodenal, ulcers is influenced by various aggressive and defensive factors such as acid-pepsin secretion, blood flow, cellular regeneration, parietal cell, mucosa barrier, mucus secretion and endogenous protective agent (prostaglandins and epidermal growth factors) (Adinortey *et al.*, 2013).

Research Article

Gastric ulceration is the benign lesion on the mucosal epithelium upon exposure of the stomach to excess acid and aggressive pepsin activity (Khazei & Salehi, 2006). It is the most prevalent gastrointestinal disorder ever known accounting for an estimated fifteen (15) mortality out of every fifteen thousand (15.000) complications every year in the world (Shristi *et al.*, 2015).

Synthetic antiulcer drugs such as cimetidine, misoprostol, ranitidine, omeprazole and esomeprazole are used in treatment of NSAID induced gastric ulcer. However, each of these drugs confers simpler to severe side effects (Saheed *et al.*, 2016), prompting a search for non toxic, easily accessible and affordable antiulcer medication.

Croton lobatus belong to the class of therapeutic plants that are highly valued and widely used by the traditional medicine practitioners in northern Nigeria. *Croton lobatus* commonly known as “Namiji” in the Northern part of Nigeria (Hausa) is an extensive flowering plant genus in the spurge family, *Euphorbiaceae*. *Croton lobatus* is a herb sometimes woody at the base, leaves digitately 3-5 lobed near the base, up to 10cm long and broad (Ezeabara and Okonkwo, 2016). It originates from continental United State, Native Caribbean Territories, and Native Caribbean North America (ITTIS). In Nigeria its leaf decoction serves as a strong purgative and is used in the treatment of fever. The leaf sap is applied to lessen the pain of scorpion stings. Non-steroidal anti-inflammatory drugs are the commonest etiological factor associated with peptic ulceration (Konturek *et al.*, 1998). The deleterious effect of indomethacin on gastric duodenal mucosa is mainly attributed to direct damage of mucosal cell and its ability to reduce the formation of prostaglandins (Graham *et al.*, 1995). The most common indomethacin induced adverse reaction is associated with the upper gastrointestinal tract and include subjective discomfort, ulcers and bleeding; the incidence of ulceration and bleeding occurs in a dose dependent fashion (Anthony *et al.*, 1993).

MATERIALS AND METHODS

Materials

Plant collection and authentication

Fresh leaves of *Croton lobatus* were collected in July 2017 at Christopher Achu and Deborah Oyeye Incorporation (CADO)’s garden Niger State. The plant materials were authenticated at Benue State University, Makurdi, Nigeria.

Chemicals and assay kits

Distilled water was obtained from Biochemistry Laboratory, University of Mkar, Mkar, Benue State, Nigeria. Indomethacin and omeprazole. Assay kits used in the analyses were products of Randox laboratories England. Other chemicals used were of analytical grade from reputable companies in the world.

Experimental animals

Albino rats of the Wistar strain weighing between 120-150g were used for this study. The animals were obtained from National Institute of Trypanosomiasis Research (NITR) and reared following approval from the Independent Ethical Committee on the Use and Care of Laboratory Animals House of chemical Science Department University of Mkar.

Methods

Extraction of *Croton lobatus* leaf

Leaves of *Croton lobatus* were air-dried at room temperature for 10 days to a constant weight. The dried samples were then pulverized with an electric blender (model MS-223; Blender/Miller III, Taiwan, China), weighed and kept air-tight prior to extraction. Powdered sample 50g was extracted with 500ml of 95.5% ethanol using soxhlet extractor. The extract obtained was concentrated to a uniform weight, stored in an air tight bottle and kept in a refrigerator at 4°C till its use.

Determination of extract yield

The percentage yield of the ethanol extract of *Croton lobatus* leaf obtained was determined by weighing the dried sample and the concentrated extract and calculated by the formula shown below:

Research Article

$$\text{Percentage yield} = \frac{\text{Weight of concentrated extract}}{\text{Weight of dried sample powder}} \times 100$$

Qualitative phytochemical analysis

Preliminary phytochemical screening was performed to identify the presence or absence of bioactive compounds in ethanol and different solvent extracts of the *Croton lobatus* leaves. The methods employed to analyse phytochemicals such as flavonoids, glycosides, tannins, alkaloids, saponins, steroids and terpenoids were in accordance with the methods of Trease and Evans (1989) modified by Harbourne (1998), Sofowora (2008) and Tiwari *et al* (2011).

Acute toxicity and lethality (LD_{50}) test

The oral acute toxicity of the ethanol extract was determined according to the method described by Lorke (1983). Briefly, 9 albino rats (20- 30 g) of either sex were divided into 3 groups of 3 animals per group. The extract dispersed in normal saline was administered to the mice in doses of 10, 100 and 1000 mg/kg and the animals were monitored for 24 h for gross behaviour and mortality. From the results of the first phase showing no death, doses of 1600, 3000, and 5000 mg/kg were administered orally to 3 groups of 4 mice per group. The animals were monitored for 24 hours for mortality. The LD_{50} was calculated as the geometric mean of the maximum dose that caused 0% death and the minimum dose that caused 100% death, which is mathematically represented as thus:

$$LD_{50} = \sqrt{(D_0 \times D_{100})}$$

Where D_0 = Highest dose that gave no mortality and D_{100} = Lowest dose that produced mortality.

Determination of the extract doses

The ethanol extract of *Croton lobatus* leaves was subjected to acute toxicity studies to determine the dose for the *in vivo* studies according to the Organization for Economic Cooperation and Development guidelines (Deora *et al.*, 2010). In all cases, 5000 mg/kg oral dose of the test extract was found to be tolerable, as no mortality was observed during the study.

Preparation of indomethacin, omeprazole and extract solutions

Indomethacin solution used in this study was prepared by dissolving 1.8 mg of Indomethacin in 1.3 ml of normal saline solution at a stock concentration of 30 mg/ml. Omeprazole solution was prepared by dissolving 1.2 mg of omeprazole in 0.6 ml of distilled water at a stock concentration of 20 mg/ml. The ethanol leaves extract was prepared by dissolving 7.5 mg of the crude extract in 1.5 ml of normal saline at a stock concentration of 100 mg/ml. The ethanol leaves extract was prepared by dissolving 17 mg of the crude extract in 2.6 ml of normal saline at a stock concentration of 200 mg/ml.

Animal grouping and gastric ulcer induction

A total of twenty five (25) albino rats were randomized into five groups of five rats each. Animals in Group ii, iii, iv and v were induced with indomethacin by oral administration of 30 mg/kg body weight indomethacin dissolved in normal saline as vehicle. The administration was one dose after 24 hours fasting by oral intubator as described by Sayanti *et al* (2007). After four hours group 2 animals were sacrificed. The normal control animals (Group I) received an oral dose of normal saline.

Animal grouping and gastric ulcer treatment

Four (4) hours after induction, the animals in Group iii were given oral dose of 20 mg/kg body weight omeprazole, while those in Groups iv and v received oral doses of 100 mg/kg and 200 mg/kg body weight extracts respectively. The oral administration was done once per day by the use of gavages for 21 days. The animals were weighed prior to the commencement of the experiment and at the end of the experiment as outlined by Sayanti *et al* (2010).

Research Article

Isolation of stomach and collection of gastric juice

On the 22nd day (4 hr post ulcer induction), the animals were humanely sacrificed by putting to sleep using chloroform in an air tight container. The abdomen was opened and the stomach excised. The stomach was thereafter opened along greater curvature and gastric content was drained into a centrifuge tube. Distilled water (5ml) was added and the resultant solution was centrifuged at 3000 rpm for 10 min. The supernatant obtained was thereafter used for biochemical analysis. The cleaned stomachs were preserved prior to macroscopic examination and homogenization.

Determination of gastric secretion parameters

Gastric acid output (volume) was determined in the supernatant (2 ml) by titration with 0.0025N NaOH using Toepfer's reagent as indicator. The pH of gastric juice was determined using a pH meter.

Quantification of ulceration

Degrees of ulceration in the indomethacin treated animals were quantified using the procedure outlined by Szabo and Hollander, (1985). Briefly, cleaned stomachs were pinned on a corkboard and ulcers were scored using dissecting microscope with square-grid eyepiece based on grading on a 0–5 scale (depicting severity of vascular congestions and lesions/hemorrhagic erosions) as presented in Table 1 below.

Table 1 Ulcer scores and descriptive remark.

Score	Remark
0	Almost normal mucosa
1	Vascular congestions
2	One or two lesions
3	Severe lesions
4	Very severe lesions
5	Mucosa full of lesions

Areas of mucosal damage were expressed as a percentage of the total surface area of the glandular stomach estimated in square millimetres. Mean ulcer score for each animal was expressed as ulcer index (UI) and the percentage of inhibition against ulceration was determined using the expressions:

$$UI = [\text{Ulcerated area/total stomach area}] \times 100.$$

$$\% \text{ Ulcer inhibition} = \frac{[\text{UI in Group II} - \text{UI in test}] \times 100}{\text{UI in Group II}}$$

Statistical analysis

Inhibition against ulceration was expressed in percentage. Other results were expressed as mean of five determinations \pm standard error of the mean (SEM). The one-way analysis of variance (ANOVA) for multi-sample groups at $p < 0.05$ were used to assess statistical significance in various groups of animals by using SPSS program version 2.01 (SPSS, 2008).

RESULTS

Qualitative phytochemical composition of *Croton lobatus* leaf extracts

The result of phytochemical screening revealed the presence of alkaloids, saponins, steroid, flavanoid, tannins, anthraquinone, terpenoid and polyphenols (Table 2).

Effect of *Croton lobatus* leaf extract on ulcer index (UI)

The gross examination of the stomach lining of the control rats showed that the mucosa had a whitish colour with prominent rugae. However, the examination of the mucosal lining in indomethacin-induced and non-treated rats (Group II) revealed haemorrhages or linear breaks/erosions to the mucosal surface. In addition, the ulcer index in the rats of Group II was very high, with an average of $21.52 \pm 1.38 \text{ mm}^2$. However, indomethacin-induced and treated rats that received either omeprazole (Group III) or *Croton*

Research Article

lobatus extract (Group IV and V) showed fewer hyperaemic areas and linear brown lesions when compared to the Group II animals, with their mean ulcer index of $6.39 \pm 1.45 \text{ mm}^2$, $9.46 \pm 1.45 \text{ mm}^2$ and $7.25 \pm 1.11 \text{ mm}^2$ respectively. The ulcer index for the indomethacin-induced and treated animals (Groups III, IV, and V) was significantly ($P < 0.05$) lower than that of the indomethacin-induced and non-treated animals (Group II) (Figure 1).

Table 2: Preliminary analysis of phytochemicals in aqueous and different organic leaf extract of *Croton lobatus*.

S/N	Parameters	N-Hexane	H ₂ O	C ₂ H ₅ OH	CH ₃ OH
1	Alkaloid	-	+	+	+
2	Saponin	-	+	-	+
3	Steroid	-	+	+	-
4	Tannins	+	-	-	-
5	Anthraquinone	+	+	-	+
6	Flavonoids	++	-	+	++
7	Reducing sugar	-	-	-	-
8	Polyphenols	-	-	++	+
9	Terpenoids	++	++	-	+

KEY: - = Not detected, + = slightly detected, ++ = moderately detected

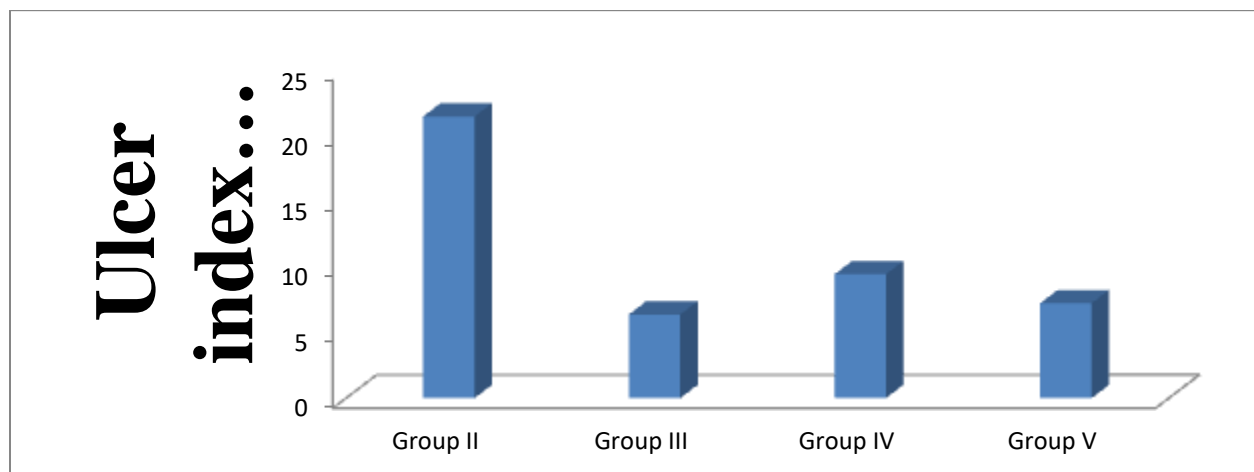


Figure 1: Effect of ethanol extract of *Croton lobatus* leaf on UI of indomethacin-induced ulcerated albino rats.

Group II: Ulcerated control, Group III: Positive control (Indomethacin-induced ulcerated and omeprazole treated), Group IV: Indomethacin + *Croton lobatus* leaf extract (100 mg/kg body weight) and Group V: Indomethacin + *Croton lobatus* leaf extract (200 mg/kg body weight)

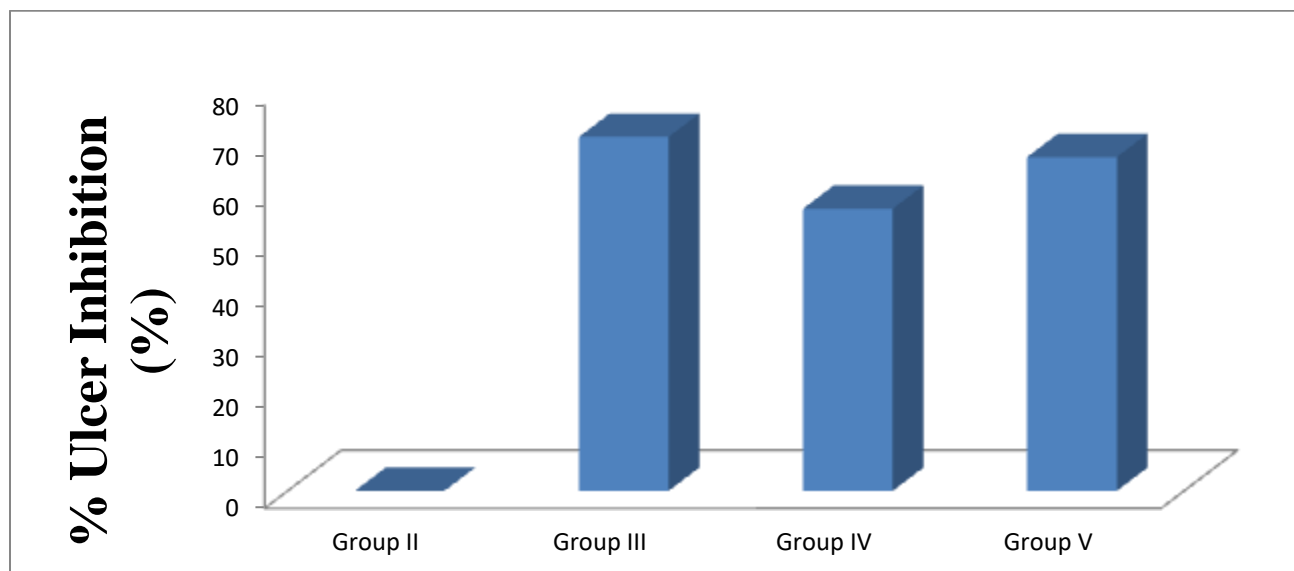


Figure 2: Effect of ethanol extract of *Croton lobatus* leaf on the percentage ulcer inhibition of indomethacin-induced ulcerated albino rats.

Group II: Ulcerated control, Group III: Positive control (Indomethacin-induced ulcerated and omeprazole treated), Group IV: Indomethacin + *Croton lobatus* leaf extract (100 mg/kg body weight) and Group V: Indomethacin + *Croton lobatus* leaf extract (200 mg/kg body weight)

Effect of ethanol extract of *Croton lobatus* leaf on gastric volume

Table 4 and Figure 4 show the effect of ethanol leaf extracts of *Croton lobatus* on gastric secretions of indomethacin-induced ulcerated rats. Treatment with the omeprazole (Group III) and the plant's extract (Groups, IV and V) produced significant decrease ($P < 0.05$) in gastric volume when compared with that of animals in non-treated group (Group II) (Table 4, Figure 3).

Effect of ethanol extract of *Croton lobatus* leaf on gastric juice pH

The pH of gastric juice was found to be decreased in indomethacin-induced non-treated rats (Groups ii, iii, iv and v) when compared with that of the normal control rats (Group I) (Table 4 and Figure 4). However, there was significant decrease ($P < 0.05$) in the pH of gastric juice of indomethacin-induced and treated rats (Groups iii, iv and v) when compared with that of the animals in ulcerated and non-treated group (Group ii) (Table 4 and Figure 4).

Table 4: Effects of ethanol leaf extracts of *Croton lobatus* on gastric volume and pH of indomethacin ulcerated rats.

Group	Treatments	Gastric volume (ml)	pH
A	Normal saline (normal control)	2.07±0.08	3.52±0.40
B	IND (ulcerated control)	14.71±2.32	2.46±0.40
C	IND + OMP	3.87±0.26 ^b	3.65±0.34 ^{ab}
D	IND + C.l (100 mg/kg b.w.)	7.99±2.09 ^b	4.72±0.28 ^b
E	IND + C.l (200 mg/kg b.w.)	5.76±0.93 ^b	5.26±0.23 ^b

Key: Result expressed as mean ±SEM (n=5); ^a Non-significant ($P > 0.05$) compared to the normal control group. ^b Significant ($P < 0.05$) compare to the indomethacin-ulcerated control (group II). IND, indomethacin (30 mg/kg b.w.); OMP, omeprazole (20 mg/kg b.w.); C.l, *Croton lobatus*.

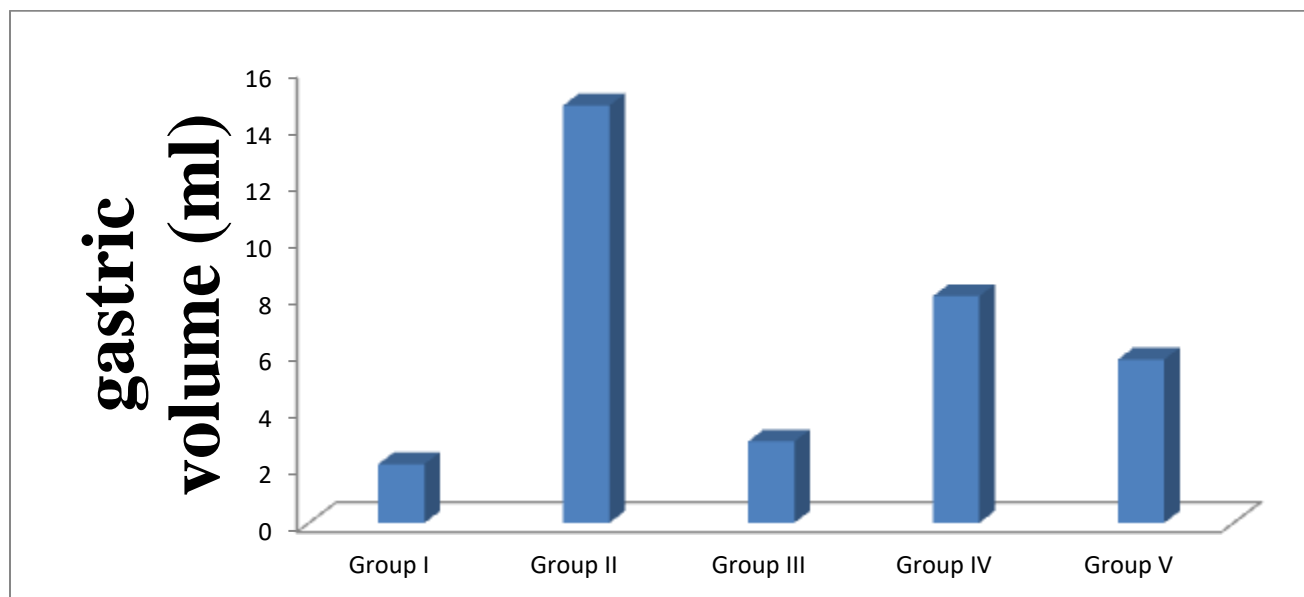


Figure 3: Effect of ethanol extract of *Croton lobatus* leaf on gastric volume (ml) of indomethacin-induced ulcerated albino rats.

Group I: Normal control, Group II: Ulcerated control, Group III: Positive control (Indomethacin-induced ulcerated and omeprazole treated), Group IV: Indomethacin + *Croton lobatus* leaf extract (100 mg/kg body weight) and Group V: Indomethacin + *Croton lobatus* leaf extract (200 mg/kg body weight)

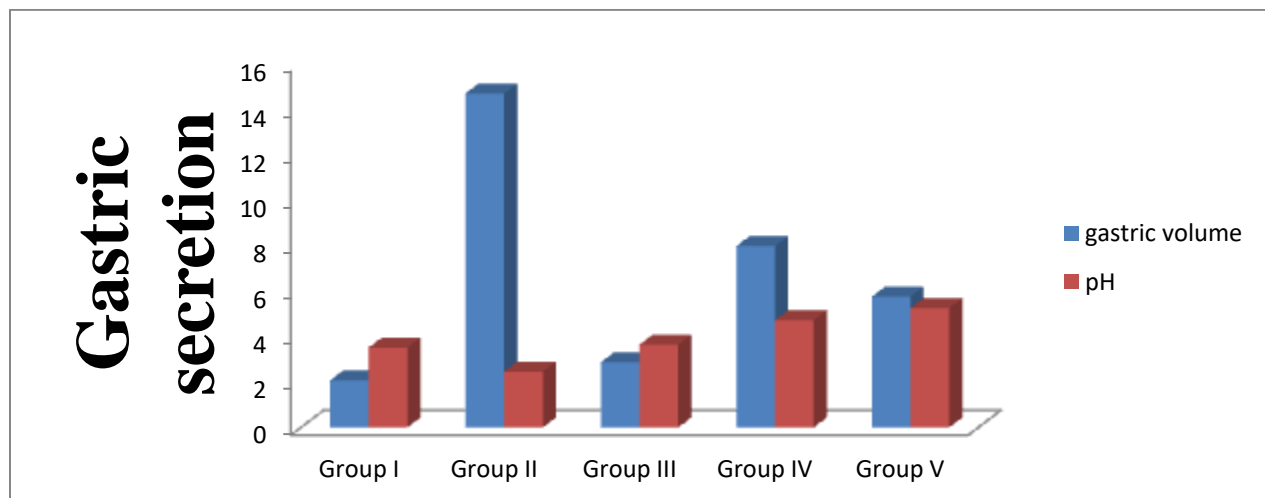


Figure 4: Effect of ethanol extract of *Croton lobatus* leaf on the gastric secretion of indomethacin-induced ulcerated albino rats.

Group I: Normal control, Group II: Ulcerated control, Group III: Positive control (Indomethacin-induced ulcerated and omeprazole treated), Group IV: Indomethacin + *Croton lobatus* leaf extract (100 mg/kg body weight) and Group V: Indomethacin + *Croton lobatus* leaf extract (200 mg/kg body weight)

Effect of ethanol extract of *Croton lobatus* leaf on combine acidity

Table 5 and Figure 6 show the effect of ethanol leaf extracts of *Croton lobatus* on combine acidity of indomethacin ulcerated rats. Indomethacin administration (Groups ii, iii, iv and v) resulted to significant ($p < 0.05$) increase in combine acidity, free acidity as well as corresponding total acidity when compared to

Research Article

those of the normal control animals (Group i). However, treatment with omeprazole (Group iii) and the plant's extract (Groups iv and v) produced significant ($P < 0.05$) decrease in these parameters when compared with those of ulcerated control rats (Group ii) (Table 5).

Table 5: Effect of ethanol leaf extracts of *Croton lobatus* on combine acidity of indomethacin ulcerated rats.

Group	Free Acidity(Meq/L)	Total Acidity(Meq/L)	Combined Acidity(Meq/L)
Control (I)	10.09±0.36	19.97±0.60	9.89±0.51
IND (II)	30.11±0.35	80.57±1.60	50.46±1.60
IND+OMP (III)	15.30±0.32 ^b	23.39±1.33 ^{ab}	8.10±1.43 ^{ab}
IND+100mg/kg (IV)	8.76±0.25 ^{abc}	37.28±0.47 ^{bc}	28.52±0.72 ^{bc}
IND+200mg/kg (V)	8.24±0.26 ^{abc}	31.31±1.23 ^{bc}	23.07±1.23 ^{bc}

Result expressed as mean ± SEM (n =5). ^a Non-significant ($P > 0.05$) compared to the normal control. ^b Significant ($P < 0.05$) compare to IND (ulcerated rats). ^c Significant ($P < 0.05$) compared to the standard drug (IND+OMP). IND, indomethacin (Group II 30 mg/kg b.w.); OMP, omeprazole (Group III, 20 mg/kg b.w.); C.l, *Croton lobatus*.

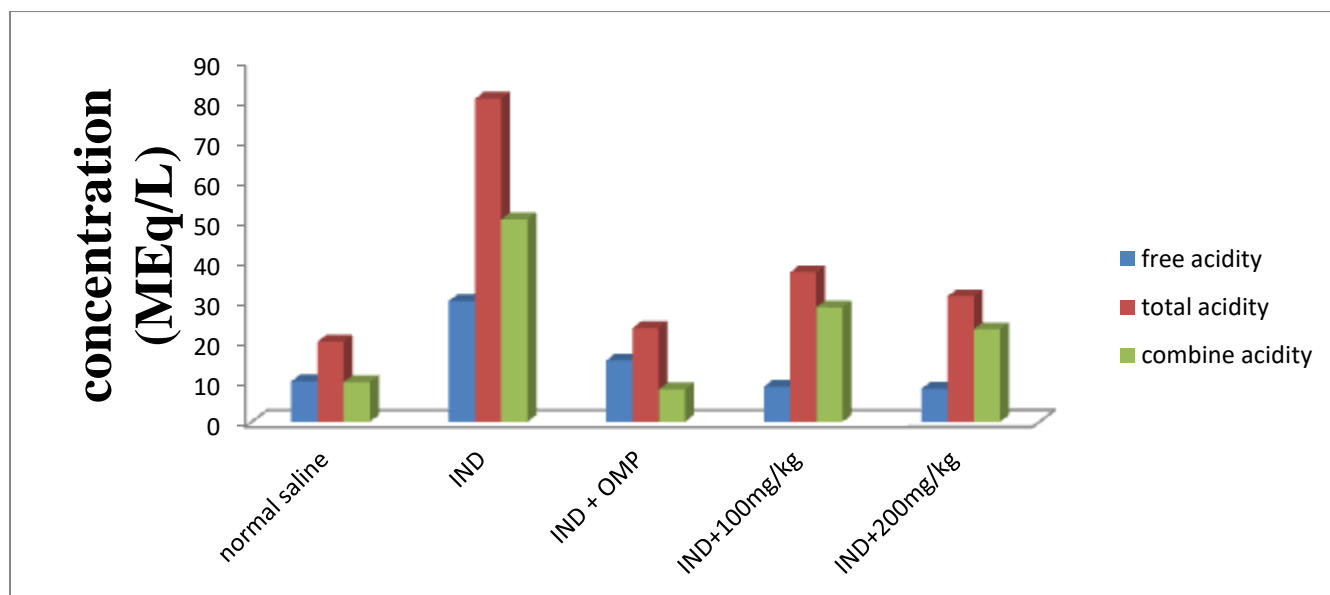


Figure 5: Effect of ethanol extract of *Croton lobatus* leaf on the concentration of acidity (MEq/L) of Indomethacin-induced Ulcerated albino rats.

Group I: Normal control, Group II: Ulcerated control, Group III: Positive control (Indomethacin-induced ulcerated and omeprazole treated), Group IV: Indomethacin + *Croton lobatus* leaf extract (100 mg/kg body weight) and Group V: Indomethacin + *Croton lobatus* leaf extract (200 mg/kg body weight)

Discussion

The present study assessed the effects of *Croton lobatus* leaf extract on gastric ulceration induced by indomethacin in albino Wistar rats. Like other NSAIDs, indomethacin is an analgesic that exhibits side effects such as ulcerogenic action on stomach (Malfertheiner *et al.*, 2009). Indomethacin administration caused significant ($p < 0.05$) increase in gastric volume of gastric content.

Research Article

Inhibitory action of indomethacin on prostaglandin synthesis coupled with free radicals formation has been opined as critical biochemical events in the pathogenesis of gastric ulceration (Ajani *et al.*, 2014; Hong *et al.*, 2014; Inas *et al.*, 2011; Lichtenberger, 2005).

The extracts at 200 mg/kg body weight offered better protection against ulceration than the 100 mg/kg body weight regimens. It is further explained in figure 8 and 9. The ulcer index confirms the effectiveness of the treatment in induced gastric ulcers.

Biochemical analysis of gastric secretions (for pH, gastric volume) and combine acidity for stomach is usually employed to ascertain its status following exposure to pharmacological agents (Biplab *et al.*, 2011). The pH gives an idea of the level of acidity and volume of gastric secretions. Low pH value is a manifestation of decreased hydrogen ion concentration in gastric juice. This has been linked to pathogenesis of ulcer and gastric damage in experimental animals (Lu'llmann *et al.*, 2000). In the present study, the significant increase in ulcer index and gastric volume following oral administration of indomethacin in the ulcerated rats may be attributed to either free radicals formation or inhibition of prostaglandin synthesis.

Decreased prostaglandin level has been attributed to impaired gastroprotection and increased gastric secretion which are important events in the etiology of mucosal ulceration. This agrees with the report of Bech *et al.* (2000), Biplab *et al.* (20011) and Muhammed *et al.* (2012) where indomethacin was reported to have caused alterations in gastric secretions of rats. Conversely, treatments with the extracts significantly reduced these parameters. In fact, the effects noticed for pH compared favorably well with both normal control and standard drug used in this study and indeed suggestive of their possible gastroprotective attributes.

The therapeutic effect elicited by ethanol leaf extracts of *Croton lobatus* against indomethacin-induced gastric ulceration in this study may be linked to their beneficial medicinal attributes occasioned by phytometabolite constituents. These include ability to scavenge free radicals and regulate mucosal membrane permeability thereby countering the effect of indomethacin on gastric acid secretion. This is in agreement with the submissions of Inas *et al.* (2011) and Muhammed *et al.* (2012), where gastroprotective potentials of plant extracts against indomethacin ulcerated rats were associated with their polyphenolic compounds and other various bioactive principles. Since omeprazole is a proton pump inhibitor, the effect produced by the two extracts might have perhaps mimic its mechanism of action by modulating cells in the mucosal lining of the stomach against excess acid secretion (Tulassay *et al.*, 2008; Fornai *et al.*, 2011).

Conclusion

The findings of this study expressed attenuation of gastric affronts of indomethacin by ethanol leaf extracts of *Croton lobatus*, which is indicative of the gastro protective potential of the extract in albino rats.

REFERENCES

- Aboagye, F A, Sam, G H, Massiot, G. Lavaud, and Julocrotine, C A. (2000). Glutarimide alkaloid from *Croton membranaceus*. *Fitoterapia*. 71. 461-462.
- Abrahamse, S. Kloots W and Amelsvoort J V. (2005). Absorption, distribution, and secretion of epicatechin and quercetin in the rat. *Nutritional Research Journal*. 25. (3) 305–317.
- Adeneye A A and Olagunju J A. (2009). Preliminary hypoglycemic and hypolipidemic activities of the aqueous seed extract of *Carica papaya* Linn in Wistar rats. *Journal of Biological Medicine*. 1. (1).1-10.
- Adinortey, M B. Ansah, C.Galyuon, I. and Nyarko, A. (2013). In vivo Models used for evaluation of potential antigastroduodenal ulcer agents. *Journal of ethnopharmacology*. 23(2)1-12
- Alkofahi, A. and Atta, A H. (1999). Pharmacological screening of the anti-ulcerogenic effects of some Jordanian medicinal plants in rats. *Journal of ethnopharmacology*. 67. (3)341-345.

Research Article

- Almeida, A A B. Melo, P S. and Hiruma-Lima C A. (2003).** Antiulcerogenic effect and cytotoxic activity of semi-synthetic crotonin obtained from *Croton cajucara* benth. *European Journal of Pharmacology*. 473. (3)205-212
- Ajani, E O. Sabiu, S. and Bamisaye, F A. (2014).** Hepatoprotective and antioxidative effect of ethanolic leaf extract of *Langenaria breviflora* (bitter gourd) on indomethacin-ulcerated rats. *Journal of Pharmacology Biological Sciences*. 9. 61–68.
- Aguilar-Guadarrama, A.B. and Rios, M.Y. (2004).** Three new sesquiterpenes from *Croton arboreous*, *Journal of Natural Products* 67, 914-917.
- Anthony, A. Dhillon, A P. and Nygard, G. (1993).** Early Histological Features of Small Intestinal Injury Induced by Indomethacin. *Journal of Alimentary and Pharmacological Therapy*; 7: 29 – 40.
- Attioua, B. (2005).** Contribution à l'étude phytocimique des feuilles et tiges de *Croton lobatus* (*Euphorbiaceae*), Ph.D., Dissertation, University of Strasbourg, 135.
- Attioua, B. Chabert, P. and Weniger, B. (2007).** Anti-plasmodial Activity of Constituents Isolated from *Croton lobatus* (*Euphorbiaceae*), *Pharmaceutical Biology*, 45, 1-4.
- Babili, F E. Moulis, C. Bon, M. Respaud, M J. and Fouraste, I. (1998).** Three furano diterpenes from the bark of *Croton campestris*. *Phytochemistry*. 48. (1) 165-169
- Barbosa P R, Fascio M, Martins D, Silva Guedes M L, and Roque, F. (2003).** Triterpenes of *Croton betulaster* (*Euphorbiaceae*), *Biochem. System. and Ecology*, 31, 307–308.
- Bech, P L. Xavier, R. and Lu, N. (2000).** Mechanisms of NSAID-induced gastrointestinal injury defined using mutant mice. *Gastroenterology*. 119,699–705.
- Berry, P. (2006).** Croton Research Network University of Wisconsin Board of Regent Madison, USA.
- Biplab, A. Sudhir, K Y. and Kshama, R. (2011).** Black tea and the aflavins assist healing of indomethacin-induced gastric ulceration in mice by antioxidative action. *Evidence Complementary and Alternative Medicine* 11:11–22.
- Braga, R. (1976).** 3rd edition Plantas do nordeste, especialmete doceara, Escola superior de Agricultura de mossoro, fortaleza, Brazil.
- Brucker, M C and Faucher, M A. (1997).** Pharmacologic management of common gastrointestinal problems in women. *Journal of Nurse-Midwifery*. 42. (3)145-162.
- Buer, J K. (2014).** Origins and impact of the term 'NSAID'. *Inflammopharmacology*. 22. (5). 263–267.
- Burkill, H M. (2004).** 2nd edition. The useful plants of west tropical Africa families. 636
- Cai, Y. Evans, F J. Roberts, M F. Phillipson, J D. Zenk, M H. and Gleba, Y Y. (1991).** Polyphenolic compounds from *Croton lechleri*, *Phytochemistry*. 30. 2033–2040.
- Campos, A R. Albuquerque, F A A. Rao, V S N. Maciel M A M. and Pinto, A C. (2002).** “Investigation one the antinociceptive activity of crude extracts from *Croton cajuacara* leaves in mice”. *Fitoterapia*. 73. (2)116-120
- Chabert, P. Attioua, B. Weniger, B. and Brouillard, R. (2006).** *Croton lobatus*, an African Medicinal plant: Spectroscopic and chemical elucidation of its many constituents, *BioFactors*, 27, 69-78.
- Chason, R. D. Reisch, J.S. and Rockey, D.C. (2013).** More favorable outcomes with peptic ulcer bleeding due to *Helicobacter pylori*. *American Journal of Medicine* 126(9): 811–818.
- Charlotte, W P. and Kathleen, C (2014).** Essential Biochemistry 3rd ed. John Wiley and Sons, Inc. 284
- Charlotte, P. and Kathleen, C. (2014).** Essential Biochemistry 3rd ed. John Wiley and Sons, Inc. 508.
- Corne, S J. Morrissey, S M. Woods, R J. (1974).** Proceedings: a method for the quantitative estimation of gastric barrier mucus, *Journal of Physiology*. 242. (2)116–117.
- Del Valle, J. (2005).** Peptic ulcer disease and related disorders. *Harrisons Principles of Internal Medicine*. McGraw-Hill Global Education Holdings, LLC. Chapter 293.
- Devasagayam, T P. Tarachand, U. (1987).** Decreased lipid peroxidation in the rat kidney during gestation, *Biochem Biophys Res Commun* 145. 134–138.
- Eating, Diet and Nutrion for peptic Ulcer disease. (2015).** National institute of diabetes and digestive & kidney disease.

Research Article

Ezeabara, C A. and Okonkwo E E. (2016). Comparison of phytochemical and proximate components of leaf, stem and root of croton hirtus l'herit and croton lobatus linn. *Journal of Medical and Health Research*.

Fornai, M. Colucci, R. and Antonioli, L. (2011). Effects of esomeprazole on healing of nonsteroidal anti-inflammatory drug (NSAID)-induced gastric ulcers in the presence of a continued NSAID treatment: Characterization of molecular mechanisms. *Pharmacology Research Journal* 63. 59–67.

Fowler, C. J. (2017). The contribution of cyclooxygenase-2 to endocannabinoid metabolism and action. *British Journal of Pharmacology*. 152. (5)594–601.

Gbore FA, Oginni O, Adewole, A.M. Aladetan, J.O. (2006). The effect of transportation and handling stress on haematology and plasma biochemistry in fingerlings of *Ciarias gariepinus* and *Tilapia zilli*. *World Journal of Agricultural Science*. 2(2):208-212.

Goyal, R K. (2008). 17th edition. Elements of pharmacology, B S. Shali Prakashan, New Delhi, India.

Graham, D. Y. Smith, J. L. and Opekum, P. A. (1995). Spicy food and the stomach. *Journal American Medical Association*; 260: 3473 – 3475.

Havsteen B.H. (2002). The biochemistry and medical significance of the flavonoids. *Pharmacology and Therapeutics*. 96(2–3) 67–202.

Hayllar, J. and Bjarnason, I. (1995). NSAIDs, COX-2 inhibitors and the gut. *The Lancet*. 346. (8974). 521-522

Higuchi K, Umegaki E, Watanabe T, Yoda Y, Morita E, Murano M, Tokioka S, Arakawa, T. (2009). Present status and strategy of NSAIDs-induced small bowel injury. *Journal of Gastroenterology*. 44 (9): 879–888.

Hinz B, Cheremina O, Brune K (2008). Acetaminophen (paracetamol) is a selective cyclooxygenase-2 inhibitor in man *The FASEB Journal*. 22 (2): 383–390.

Hong Y, Xingchang P, Zhixiu S (2014). Protective effect of wheat peptides against indomethacin-induced oxidative stress in IEC-6 cells. *Nutrients* 6:564–74.

Hoogerwerf, W A. and Pasricha, P J. (2001). Agents used for control of gastric acidity and treatment of peptic ulcers and gastroesophageal reflux disease. *Pharmacological Basis of Therapeutics*. 10th edition. Mc Graw-Hill New York, USA. 1005-1019

Inas, Z.A, Abdallah-Hala, A.H, Khattab, H, Gehan, H.H. (2011). Gastroprotective effect of Cordia myxa L. fruit extract against indomethacin-induced gastric ulceration in rats. *Life Sci J* 8: 433–45.

Jones, G A, Mcallister, T A, Muir A D, and Cheng K I. (1994). Effects of sainfoin *Onobrychis vicifolia* proteolysis by four strains of rumenal bacteria. *Applied Journal of Environmental Microbiology*. 60. 1375-1378.

Khazaei, M. and Salehi, H. (2006). Protective effect of falcaria vulgaris extract on ethanol induced gastric ulcer in rat. *Iranian Journal of Pharmacology and Therapeutics*. 5. 1-4.

Knights and Kathleen. (2013). Defining the COX Inhibitor Selectivity of NSAIDs: Implications for Understanding Toxicity.

Konturek, S J. Redek, T. Plastuck, I. Brzozowski, T. and Drodowicz, D. (1998). Gastroprotection by colloidal bismuth substrate (Denol) and sucralfate: Role of endogenous prostaglandin. *Gut*. 228. 201 – 205

Kronberg S L. (2010). Sheep ingestion of water containing quebracho or black wattle tannin. *Rangeland Ecology and Management*. 63. (2)258-262.

Lamarque, D. (2004). Pathogenesis of gasteoduodenal lesions induced by NSAIDs. *Gastroenterologie Clinique et Biologique*. 28. C18-C26

Lu'llmann H, Mohr K, Ziegler A, Bieger D. (2000). In: Liane P S, David F, eds. Color Atlas of Pharmacology. 2nd ed. New York: Thieme Stuttgart, 166–70.

Malfertheiner P, Chan F, McColl K. (2009). Peptic ulcer disease. *The Lancet*. 374(9699): 1449–1461,

Marklund, S. Marklund, G. (1974). Involvement of superoxide anion radical in the autooxidation of pyrogallol and a convenient assay for superoxide dismutase, *European Journal of Biochemistry* 47. 469–474.

Research Article

- McChesney, J D. Clark, A M. and Silveira, E R. (1991).** Antimicrobial Diterpenes of *Croton sonderianus*, 11, ent-Beyer-150en-18-oic acid. *Pharmaceutical Research*. 8. (10). 1243- 1247.
- McChesney, J D. Clark, A M. and Silveira, E R. (1991).** Antimicrobial Diterpenes of *Croton sonderianus*, 1, Hardwickic and 3,4- Secotrachylobanoic Acids, *Journal of Natural Products*. 54. 1625-1633.
- Muhammed A V K, Thamotharan G, Sengottuvelu S (2012).** Evaluation of antiulcer activity of *Ficus pumila* L. leaf extract in albino rats. *Global Journal Research in Medicinal Plants and Indigenous Medicine* 1:340–51.
- Najm, W I. (2011).** Peptic ulcer disease. 38. (3). 383-394
- Nardi, G M. Felippi, R. and Dalbo, S. (2003).** “Anti-inflammatory and antioxidant effects of *Croton celtidifolius* bark”. *Phytomedicine* 10(2)176-184.
- Peckenpaugh, N J. and Poleman C M. (1997).** 7th edition. *Notricao Essenciae Dietoterapia*, Editora Roca. Sao Paulo, Brazil.
- Priyanka P and Brahmshatriya P S. (2013).** Terpenes: Chemistry, Biological Role and Therapeutic Applications. *Natural Products* 2665-2691.
- Raji Y, Oyeyemi W A, Shittu S T, and Bolarinwa A F. (2011).** Gastroprotective effect of methanol extract of *Ficus asperifolia* bark on indomethacin-induced gastric ulcer in rats. *Nigeria Journal for Physiological Sciences* 26. 43–48.
- Rao, Devaji, S. (2014).** Clinical manual of surgery *Elsevier Health Sciences* 526
- Rao, C V. Sairam, k. and Goel, R K. (2000).** Experimental evaluation of *Bocopa monniera* on rat gastric ulceration and secretion. *Indian Journal of physiology and pharmacology* 44 (6)435-441.
- Rates, S M K. (2001).** Plants as source of drugs. *Toxicon* 39 (5)603-613.
- Rang, H P. (2003).** Pharmacology. Churchill livingstone. Edinburg UK.
- Rosa, M D S S. Mendonasafilho RR and Bizzo HR (2003).** Antileishmanial activity of a linalool-rich essential oil from *Croton cajucara*. *Antimicrobial agents and chemotherapy* 47 (6)1895-1901.
- Rumki N. Saswatiroy, Biplab, D. and Dutta Choudhury (2013).** Anticancer and antioxidant activity of croton 5 (2)63-69
- Sabiu, S. Wudil, A M. and Sunmonu, T O. (2014).** Combined administration of *Telfaira occidentalis* and *Vernonia amygdalina* leaf powders ameliorates garlic-induced hepatotoxicity in Wistar rats, *Pharmacology* 5 (5) 191–198.
- Saheed, S. Taofeeq, G. Taofik, O S. AbdulHakeem, O S. and Nurain, O I. (2016).** Indomethacin-induced gastric ulceration in rats: Ameliorative roles of *Spondias mombin* and *Ficus exasperate*. *Pharmaceutical Biology*. 54. (1)180-186,
- Sairam, K, Rao, C V. and Goel, R K. (2001).** Effect of *Convolvulus pluricaulis* Choisy on gastric ulceration and secretion in rats. *Indian Journal of Experimental Biology*. 39. (4) 350–354.
- Salatino, A. Salatino, M L F. and Negri, G. (2007).** “Traditional uses, chemistry and pharmacology of croton species (Euphorbiaceae)”. *Journal of the Brazillian Chemical Society*. 18. (1). 11-13.
- Satyanarayana, U. and Chakrapani, U. (2006).** 3rd edition. Digestion and Absorption. *Biochemistry*. Arunabha Sen Books and Allied (P) Ltd. 179.
- Sanyal, A R. Denath, O K. Bhattacharya, S K. and Gode, K D. (1971).** The effect of cyproheptadine on gastric acidity, in: *C.J. Pfeiffer*, Peptic ulcer, Scandinavian University Books, Munksgaard. 312–318.
- Sayanti B, Susri R C, Subrata C and Sandip KB (2007).** Healing properties of some Indian medicinal plants against indomethacin-induced gastric ulceration of rats, *Journal of Clinical Biochemistry and Nutrition*. 41. (2) 106–114.
- Schmeda-Hirschmann, G. And Yesilada, E. (2005).** Traditional medicine and gastroprotective crude drugs”. *Journal of Ethnopharmacology*. 100. (1-2):61-66.
- Shristi, B. Neha, J. Indu, B P. And Rajesh, G. (2012).** A review on some Indian medicinal plants for antiulcer activity. *Journal of Science Research Pharmacology*. 1. 6-9

Research Article

- Silva, M R. Santos, F A. Maciel, M A Rao, V S N and Pinto A C. (2001).** Blood glucose and triglyceride lowering effect of transdehydrocrotonin, a diterpene from *Croton cajuacaca* benth. in rats. *Diabetes, obesity and metabolism* 3 (6) 452-456.
- Simone Rossi (2006).** *Australian medicines handbook*. Adelaide: Australian Medicines Handbook Pty Ltd.
- Si-Yuan, P. Shu-Feng, Z. and Si-Hua, G. (2010).** New perspective on how to discover drugs from herbal medicine.
- Spirt M J. (2004).** Stress related mucosal disease: risk factors and prophylactic therapy. *Clinical Therapy*. 26. (2)197-213.
- Spirt M J, and Stanley S. (2006).** Update on stress ulcer prophylaxis in critically ill patients. *Critical Care Nurse*. 26. (1) 22-28.
- Suarez, A I, Compagnone R S and Salazarbookaman M M (2003).** Antinociceptive and anti inflammatory effects of *Croton malambo* bark aqueous extract” *Journal of ethnopharmacology*. 88. (1)11-14.
- Sutthivaiyakit, S. Nareeboon, P. Ruangrangsri, N. Ruchirawat, S. Pisutjaroenpong, S. and Mahidol, C. (2001).** Labdane and pimarane diterpenes from *Croton joufra*, *Phytochemistry*. 56. 811-814.
- Szabo, S. and Hollander, D. (1985).** Pathways of gastrointestinal protection and repair: mechanisms of action of sucralfate, *American Journal of Medicine*. 86. (6A) 23–31.
- Tadataka Yamada. (2008).** Peptic Ulcer Disease,. In *Textbook of Gastroenterology*. 941.
- Tang, R S, and Chan, F K L. (2012). Therapeutic management of recurrent peptic ulcer disease. *Drugs*. 72. (12). 1605–1616.
- Thongtan, J. Kittakoop, P. Ruangrungsri, N. Saenboonrueng, J. and thebtaranonth, Y. (2003).** New antimycobacteria and antimalaria 8, 9-secokaurane dipterpenes from *Croton kongensis*. *Journal of natural products*. 66. (6)868-870.
- Traversa G, Walker A M, Ippolito F M, Caffari B, Capurso L, Dezi A, Koch M, Maggini M, Alegiani S S. and Raschetti, R. (1995).** Gastroduodenal toxicity of different nonsteroidal antiinflammatory drugs.
- Valle, D L. (2005).** Peptic ulcer diseases and related disorder *Harrison’s principle of internal medicine*. Mc Graw-Hill New York. USA. 1746-1762.
- Vander, S L. (1998).** *Human Physiology* 7th ed. Oxford University Press, New York, 583.
- Vigor, C. Fabre, N. Fouraste, I. And Moulis, C. (2001).** Three clerodane diterpenoids from *Croton eluteria* Bennett”. *Phytochemistry*. 57 (8)1209-1212.
- Wallace, J L. Mcknight, W. Renter, B. K. and Vergnolle, N. (2000).** NSAID-Induced gastric damage in rats; requirement for inhibition of both cyclooxygenase 1 and 2 *Gastroenterology*. 119(3)706-714.
- Warden, S J. (2010).** Prophylactic Use of NSAIDs by Athletes: A Risk/Benefit Assessment . *The Physician and Sports Medicine*. 38(1)132–138. .
- Wang, Y. and ZOU, Z-M. (2008).** Sesquiterpenes from the Stems of *Croton caudatus* Geisel. var. *tomentosus* Hook. *Chinese Journal of National Medicine*., 6. 339-341.
- Weniger B, Lagnika L, Vonthron-Sénécheau C, Adjobimey J, Gbenou J, Moudachirou M, Brun R, Anton R. and Sanni A, (2004).** Evaluation of ethnobotanically selected Benin medicinal plants for their *in vitro* antiplasmodial activity, *Journal of Ethno Pharmacology*. 90, 279-284.
- Whittle, B I R. (2003).** Gastrointestinal effects of nonsteroidal anti-inflammatory drugs. *Fundamental and clinical pharmacology*. 17. (3). 301-313.
- Zhang M, Zhang H, Sun C, Shan X, Yang X, Li-Ling J, Deng Y. (2009).** Targeted constitutive activation of signal transducer and activator of transcription 3 in human hepatocellular carcinoma cells by cucurbitacin B. *Cancer Chemotherapy and Pharmacology* 63: 635-642.
- Zspdelhi.wordpress.com/2008/06/27/the-ethnomedicinal-use-of-croton.