

### Case Report

## SUCCESSFUL MANAGEMENT OF EXTERNAL OPHTHALMOMYIASIS IN A DOG – A CASE REPORT

A. Velavan,\*N. Krishnaveni, C. Ramani and Mohd. Shafiuzama

Department of Veterinary Surgery and Radiology

\*Author for Correspondence

### ABSTRACT

Six years old, Spitz cross intact male dog was presented to the Ophthalmology unit, Department of Clinics, Madras Veterinary College Teaching Hospital with the history of wound on right eye with severe swelling on face and serosanguinous discharge for two days. Clinical examination revealed large ulceration, oedematous swelling of periorbital tissue. On thorough examination it was only upper eyelid with numerous live maggots. The palpebral conjunctiva and other ocular tissues were intact. After instillation of topical 4% Lignocaine, numerous live maggots were removed with forceps. Cleaning of wound was done with 0.5 % Povidone Iodine solution and Scavon (Himalaya®, Animal Health) ointment was applied for a week. Systemic antibiotics and anti - Inflammatory were prescribed for 5 days. Swelling has reduced gradually and wound healing has occurred in two weeks.

**Keywords:** External Ophthalmomyiasis, Dog

### INTRODUCTION

Ophthalmomyiasis is the infestation of the eye by dipterous fly larvae and it can be external or internal (anterior or posterior) (Esmeralda Delgado, 2012).

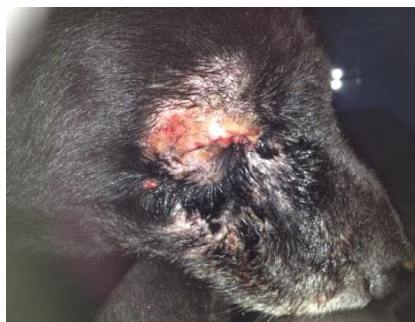Ophthalmomyiasis is divided into orbital, internal, and external, based on site of larval infestation (Sigauke, 2003). Orbital and internal ophthalmic myiasis is caused by larva with invading habits leading to blinding manifestations.

External ophthalmic myiasis refers to superficial infestations of ocular tissue such as conjunctiva and eyelids (Ratnesh Ranjan and Ravi Jain, 2014).

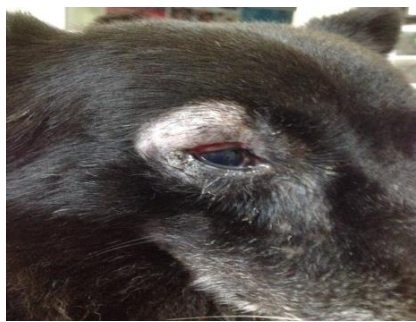
But external ophthalmomyiasis caused by invading larva can also result in serious complications such as corneal ulcer, iridocyclitis, globe invasion, endophthalmitis, and even blindness (Shankar *et al.*, 2012). Topical anaesthetic was used to reduce the motility of larvae (Thakur *et al.*, 2009).

### CASES

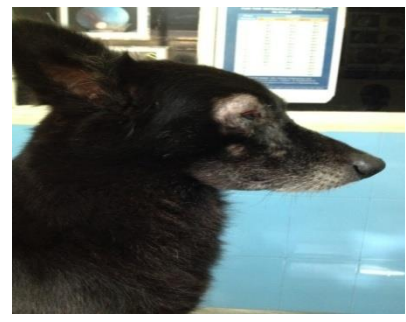
Six years old, Spitz cross intact male was presented with wound on right upper eyelid with swelling on periorbital tissue and face, serosanguinous discharge (Figure 1). On clinical examination revealed external ophthalmomyiasis.



**Figure 1: Wound on Right Upper Eyelid with Serosanguinous Discharge**



**Figure 2: After Treatment**



**Figure 3: Swelling on Face Reduced and Wound Healed**

### **Case Report**

#### **DISCUSSION**

On the day of presentation, after topical 4% Lignocaine, numerous live maggots were removed. Wound was cleaned with 0.5% Povidone Iodine solution and Scavon (Himalaya®, Animal Health) ointment was applied and continued for a week. Ivermectin @ 400 µg/kg body weight was given subcutaneously. Systemic antibiotics Ceftriaxone @ 10 mg/kg body weight and Prednisolone @ 0.5 mg/kg body weight were given orally for 5 days. Swelling has reduced gradually and wound healing has occurred within two weeks of treatment. No complications were recorded (Figure 2 and Figure 3).

#### **ACKNOWLEDGEMENT**

The authors thank Directorate of Clinics, TANUVAS for providing the facilities for this study.

#### **REFERENCES**

- Delgado E (2012).** Symblepharon secondary to ophthalmomyiasis externa in a dog. *Veterinary Ophthalmology* **15**(3) 200 – 205.
- Ranjan R and Jain A (2014).** External ophthalmomyiasis. *Oman Journal of Ophthalmology* **7**(3) 160 – 161.
- Sigauke E, Beebe WE, Gander RM, Cavuoti D and Southern PM (2003).** Case report: Ophthalmomyiasis externa in Dallas County, Texas. *American Journal of Tropical Medicine and Hygiene* **68**(1) 46–47.
- Shankar MK, Diddapur SK, Nadagir SD and Kota SG (2012).** Ophthalmomyiasis externa caused by *Oestrus ovis*. *Journal of Laboratory Physicians* **4**(1) 43–44.
- Thakur K, Singh G, Chuahan S, Sood AV, Vini and Vinci (2009).** External ophthalmomyiasis infection that occurred, and was diagnosed and treated in a single day: A rare case report. *Oman Journal of Ophthalmology* **2**(3) 130–132.