

Case Report

HIGH GRADE SEROUS PAPILLARY OVARIAN CANCER COMPANYING DERMATOMYOSITIS: A CASE REPORT AND REVIEW OF THE LITERATURE

Hongyan Cheng¹, Zhaojie Yang¹ *Guiyu Zhang¹ and Wentong Zhang²

¹Department of Obstetrics and Gynecology, Qilu Hospital, Shandong University, Ji'nan, Shandong
250012, PR China

²Shandong University School of Medicine, Ji'nan, Shandong 250012, PR China

*Author for Correspondence

ABSTRACT

Dermatomyositis (DM) has been researched that is associated with malignancy in adult patients. However, the exact risk in an individual patient is not known. There is little report on ovarian cancer companying DM. Here, we present one case about high-grade papillary serous ovarian cancer concurrent DM. A 47-year-old woman initially presented with abdominal mass and was misdiagnosed as appendicitis in local clinic. She was admitted to our hospital when the mass extended rapidly in three months and concurrent typical DM skin lesions. Elevated level of Ca125 and creatine kinase (CK), positive Anti-Nuclear antibody (ANA), ultrasonography and PET-CT showed large mass in pelvic. The severe DM condition cause dysphagia and dyspnea before surgery. Exploratory laparotomy showed a high grade serous papillary ovarian cancer and the patient was complete remission after surgery. The purpose of this report is to make gynecologist and physician aware the relationship between DM and ovarian cancer and reduce rate of misdiagnosis utmostly. Prompt cytoreductive operation could benefit to treat both ovarian cancer and DM.

Keywords: Ovarian Cancer, Dermatomyositis, Idiopathic Inflammatory Myopathy, Malignant Disease

INTRODUCTION

Ovarian cancer (OC) is the second morbidity while the most mortality cancer in female genital cancer. There are 238 thousand females diagnosed with OC per year worldwide, 151 thousand died of it (Torre *et al.*, 2012). DM is an idiopathic inflammatory myopathy (IIM) with characteristic cutaneous manifestations (Targoff and Ira, 1991). The morbidity of DM in the general population is 0.5-1.0 per 100,000 (Bohan and Peter, 1975). It has been associated with internal malignancy in 15-30% of adult patients (Callen *et al.*, 1981). The relationship between malignancy and myositis was first described in 1916. The temporal relationship between the two diseases can vary: malignancy may occur before, at the same time or following the diagnosis of DM (Zampieri *et al.*, 2010). The former authors have confirmed that IIM is associated with malignant disease with a frequency ranging 6-40% (Kalogiannidis *et al.*, 2008). DM is probably a paraneoplastic event in some patients. Ovarian, lung, and colorectal cancers were diagnosed frequently both before and after diagnosis of DM (Hill *et al.*, 2001). Because the rare correlation between OC and DM, we present a special case about OC concurrent DM and review the literature.

CASES

In August 2015, a 47-year-old woman initially presented with abdominal mass. Ultrasonography showed probably an ovarian cyst with a diameter about 2cm, she refused to receive any treatment because there were no abnormal pain or menstruation changes. Two months later, she presented with pruritic rash and tumidness on her face, heavy pain in her lower abdomen. She was treated with antibiotics cefotiam and tinidazole for nearly one month in local clinic. There was no clear response for her complaint. Then, she presented with muscle weakness in distal muscles, which made her have trouble holding or manipulating objects, also with dysphagia. She had to transformed to our hospital to search for treatment. Physical examination found there were heliotrope rashes on her upper eyelids (Figure 1. B left), erythematous and

Case Report

hyperpigmented macules on the chest [V neck sign], violaceous patches on the upper back and shoulders (Shawl sign), violaceous papules overlying the proximal interphalangeal joints of the hands (Gottron's Sign). Her face was oedematous. Her blood test showed elevated level CA125 of 1024U/ml, CA153 of 59.61U/ml, creatine kinase (CK) of 1774U/l, lactic dehydrogenase (LDH) of 519U/l, serum myoglobin (MB) of 1193.9ng/ml, and with a positive Anti-nuclear antibody. PET-CT scan showed there was about 10.2×7.8cm size mass with irregular shape and low-density soft tissue shadow around uterus in pelvic cavity, on both sides of the pelvic and lower abdominal mesenteric line area and retroperitoneal seen several high uptaken of FDG supplied about 1.9×1.7 cm size lymph nodes (Figure 1. A). The patient was diagnosed anaphylactic rhinitis for 6 years influenced by weather changes, also diagnosed epilepsy for 4 years and influenced by emotional changes. Both treated with traditional Chinese medicine. She was accepted excision of cyst thyroid in 2014. Other medical history and family history were no significance.

The patient was diagnosed DM based on the proximal, symmetric muscle weakness, specific skin lesions, dysphagia, laboratory examinations and electromyography complying Bohan's (Bohan and Peter, 1975) diagnostic criteria. Patient's condition was rapidly deteriorative after she was admitted. She couldn't eat, drink, move, even had trouble breathing. DM implicated patient's respiratory muscles and the blood gas analysis results showed Partial Pressure of Oxygen (PO₂) was only 62mmHg. We thought the sooner the patient was performed the surgery the more likely the patient would be rescued despite with huge risk. Before the operation, the patient was treated with glucocorticoid and intravenous gamma globulin for 3 days. Our exploratory laparotomy revealed both uterine and bilateral ovarian surface was full of millet sample nodules, bilateral ovarian oedematous about 4×3×4cm, bilateral oviduct became thick, Douglas pouch, peritoneum, omentum, mesenterium and appendix seen yellow-white metastatic lesions. Frozen section of the left oviduct and ovary suggested a diagnosis of poorly differentiated cancer primary in oviduct. The patient was accepted a total debulking surgery, and maximum cytoreduction with less than 0.5 cm of residual disease. The patient had to transmitted to intensive care unit (ICU) with breathing machine maintaining her breath owing to dyspnea for 3 days. When the patient's vital signs were stable, she was shifted to normal ward. After operation, her DM signs were gradually relief. Routine histopathology revealed a high grade serous papillary cancer of bilateral oviducts and ovaries, and pelvic, omentum and appendix were seen metastasis lesions (Figure 1. C). Staging was at FIGO Stage IIIC. She was given chemotherapy with docetaxel and carboplatin for 8 courses.

The patient was followed up for one year and her CA125 and CK level were normal. Unfortunately, elevation of CA125 and CK level and multiple pelvic metastases was found 1 year later. The patient is now undergoing chemotherapy until submission. Figure 2 showed the level variation of patient's CA125.

DISCUSSION

The malignant diseases most strongly associated with DM are ovarian, lung, gastric, colorectal, and pancreatic cancers, and non-Hodgkin's lymphoma (Hill *et al.*, 2001). OC with DM indicate a poor prognosis. Age maybe is a factor associated with malignancy in newly-diagnosed DM (De Souza and Shinjo, 2012). Speculations on the nosogenesis are environmental factors, paraneoplastic syndrome and malignant transformation (Maoz *et al.*, 1998). There is an increasing risk with all histological types and adenocancer is the most common cancer type associated DM in record (Hill *et al.*, 2001). Cortical steroids and immunosuppressant maybe effective in some cases (Ben-Zvi *et al.*, 2005). However, the side effects such as hypertension, Cushing Syndrome, the possibility of cancer metastasis are concerning. Intravenous immunoglobulin (IVIG) may improve the short-term prognosis of DM patients (Hill *et al.*, 2001). Sigurgeirsson (Sigurgeirsson *et al.*, 1992) undertook a population based cohort study of 788 patients diagnosed cancer with DM or PM in Sweden. Among 392 patients with DM, 57 males and 110 females died. The study showed there is higher rate mortality in patients have both malignant disease and DM. András *et al.*, (2008) performed a clinical assessment among 309 myositis patients. 89 patients had DM and 7 patients had PM. 37 cases were found malignant disease. The DM and PM with malignant diseases overall survival rate was considerably worse than other types of myositis. Zhou *et al.*, (2012) retrospectively analyzed 216 patients with DM. 25 patients of them complicated with malignant diseases

Case Report

and they were older than those who not. Patients aged over 40 years had a higher detection rate of malignancy complication. In Fang *et al.*, (2016) performed a retrospective review among 192 DM/PM patients in Taiwan province in China. 31 (16.1%) patients of them had an associated malignancy. The most common type of malignancies was Nasopharyngeal cancer (NPC). Other malignancies included breast cancer, lung cancer, non-Hodgkin lymphoma, prostate cancer. Survival was significantly lower in patients with cancer than in those without cancer.

Although, no research has confirmed the explicit association between DM and malignant disease. There are some risk factors may important for warning sign of cancer in patients with myositis. Such as older age at diagnosis, smoking, dysphagia, elevated CK, elevated tumor markers, Raynaud's phenomenon, positive antinuclear antibodies and positive anti-Jo-1 antibody (Tiniakou and Mammen, 2017).

If early detection of cancer is found by effective screening ways in patients with DM, which would potentially provide better prognosis for individuals. Routine examination and laboratory screening including chest X ray, fecal blood testing, abdominal ultrasound or CT scan, mammography, pelvic CT scan, or ultrasound, and gynecological examination are necessary. Tumor markers such as cancer antigens CA125 and CA199 could be useful screening markers for the DM. But they may not elevate in patients with OC stage I (Paramasivam *et al.*, 2005). Besides, tumor markers do not predict the occult tumors. Beth et al conducted a randomized controlled trial found that HE4 combined CA125 may be useful as a primary screening for OC (Karlán *et al.*, 2014). PET-CT is one of the most sensitive imaging inspection to detect malignant lesion and has been used in different cancer conditions and accomplished great successes (Patel *et al.*, 2008). In our case, elevated level of CA125, transvaginal ultrasonography and PET-CT scan contributed to OC detection. It is worth mentioning that our patient presented poor general condition before surgery and prompt surgery preventing further deterioration effectively. Our patient had excellent response for initially treatment with operation and chemotherapy. However, once ovarian cancer recurred, the patient is easy to suffer drug fast and indicates poor prognosis.

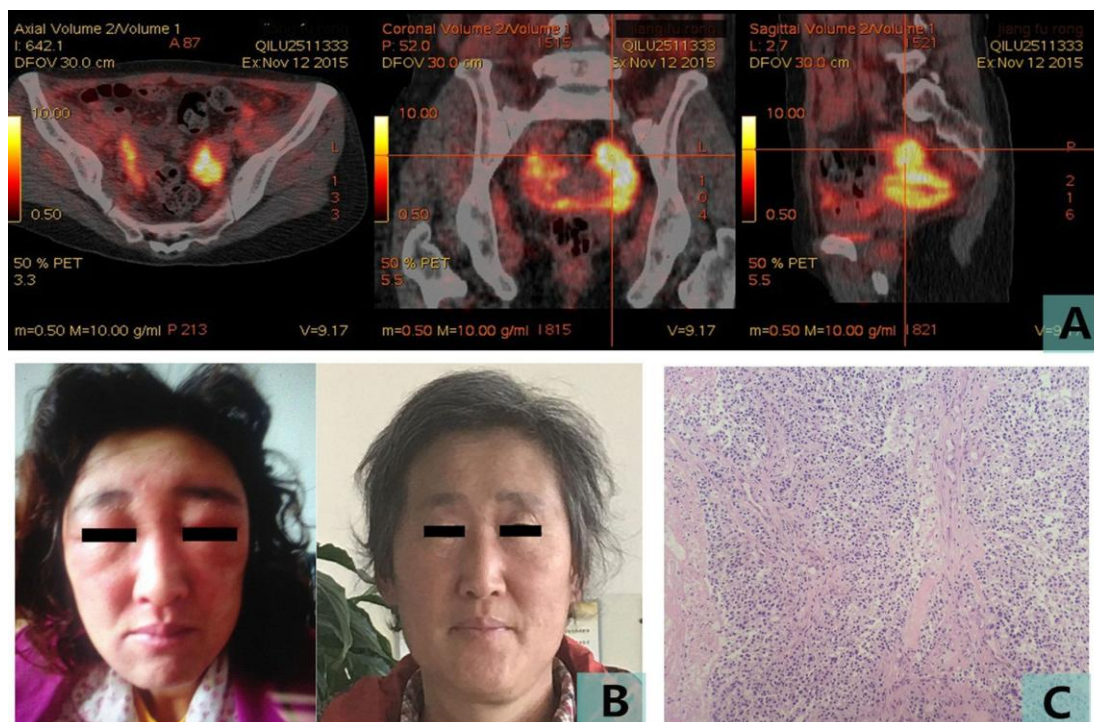


Figure 1: [A] PET-CT: 10.2×7.8cm Size Mass with Low-Density Soft Tissue Shadow around Uterus in Pelvic Cavity; [B] Left Showed Preoperative Patient's Facial Lesion and Right Showed Postoperative Normal Face; [C] Routine Histopathology Revealed a High Grade Serous Papillary Cancer [Magnification x20]

Case Report

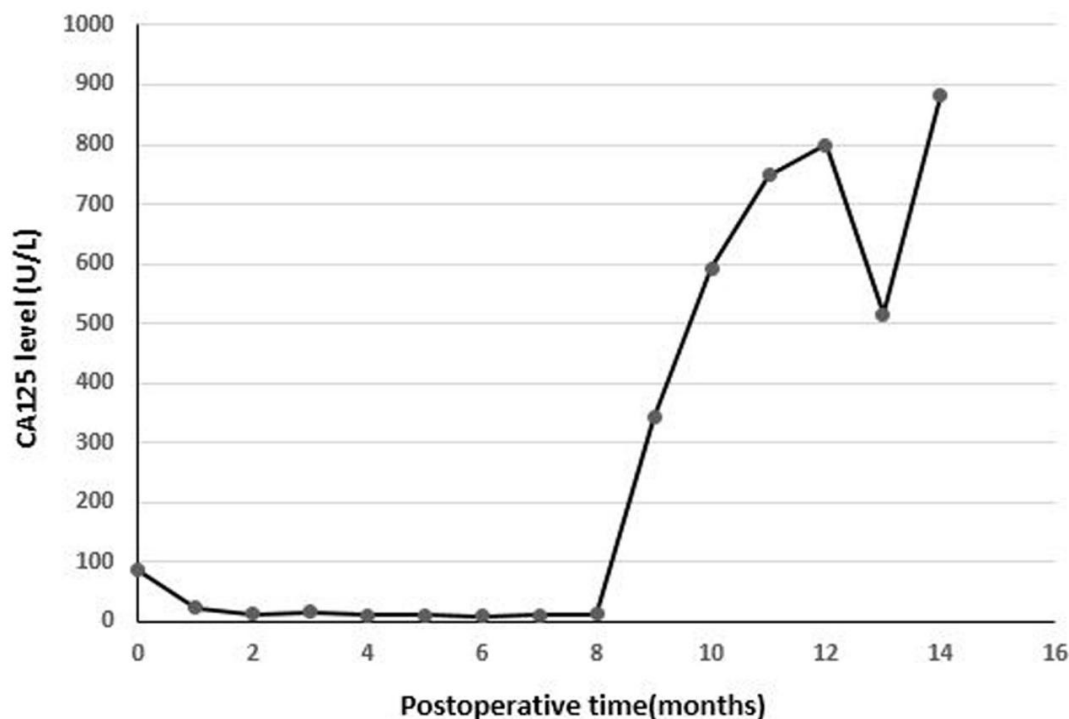


Figure 2: The Level Variation of Patient's CA125

Conclusion

In conclusion, malignant diseases sometimes occur following the diagnosis of DM. The association between DM and malignant diseases should not be neglected by physician. Routine examination and laboratory screening especially pelvic examinations, transvaginal ultrasonography, serum CA125 and HE4 levels and PET-CT may be useful screening and diagnosis tools for those whose age is over 40 years old and diagnosed DM recently. Once the ovarian cancer with DM is diagnosed, thoroughly exploratory laparotomy should be performed as soon as possible. This will help patients get the most benefits.

ACKNOWLEDGEMENTS

We wish to thank our patient and his family for their cooperation.

Competing Interests

The authors declare that they have no competing interests.

REFERENCES

- András C, Ponyi A, Constantin T *et al.*, (2008). Dermatomyositis and polymyositis associated with malignancy: a 21-year retrospective study. *Journal of Rheumatology* **35**(3) 438-44.
- Ben-Zvi N, Shani A, Ben-Baruch G *et al.*, (2005). Dermatomyositis following the diagnosis of ovarian cancer. *International Journal of Gynecological Cancer* **15**(6) 1124-1126.
- Bohan A and Peter JB (1975). Polymyositis and Dermatomyositis. *The New England Journal of Medicine* **292**(8) 403-7
- Callen JP, Hyla JF, Bole G *et al.*, (1981). The Relationship of Dermatomyositis and Polymyositis to Internal Malignancy. *Archives of Dermatology* **116**(3) 295-8.
- De Souza FH and Shinjo SK (2012). Newly diagnosed dermatomyositis in the elderly as predictor of malignancy. *Revista Brasileira De Reumatologia* **52**(5) 713-21.
- Fang YF, Wu YJJ, Kuo CF *et al.*, (2016). Malignancy in dermatomyositis and polymyositis: analysis of 192 patients. *Clinical Rheumatology* **35**(8) 1-8.

Case Report

Hill CL, Zhang Y, Sigurgeirsson B et al., (2001). Frequency of specific cancer types in DM and polymyositis: a population-based study. *Lancet* **357**(9250) 96-100.

Kalogiannidis I, Papanikolaou A, Xanthakis I et al., (2008). Clear cell ovarian cancer following polymyositis diagnosis: a case report and review of the literature. *Hippokratia* **12**(3) 181-5.

Karlan BY, Thorpe J, Watabayashi K et al., (2014). Use of CA125 and HE4 serum markers to predict ovarian cancer in elevated-risk women. *Cancer Epidemiology Biomarkers & Prevention* **23**(7) 1383-93.

Maoz CR, Langevitz P, Livneh A et al., (1998). High incidence of malignancies in patients with dermatomyositis and polymyositis: an 11-year analysis. *Seminars in Arthritis and Rheumatism* **27**(5) 319-24.

Paramasivam S, Tripcony L, Crandon A et al., (2005). Prognostic importance of preoperative CA-125 in International Federation of Gynecology and Obstetrics stage I epithelial ovarian cancer: an Australian multicenter study. *Journal of Clinical Oncology Official Journal of the American Society of Clinical Oncology* **23**(25) 5938-42.

Patel RR, Subramaniam RM, Mandrekar JN et al., (2008). Occult malignancy in patients with suspected paraneoplastic neurologic syndromes: value of positron emission tomography in diagnosis. *Mayo Clinic Proceedings* **83**(8) 917-922.

Sigurgeirsson B, Lindelöf B, Edhag O et al., (1992). Risk of Cancer in Patients with Dermatomyositis or Polymyositis. *New England Journal of Medicine* **326**(6) 363-7.

Targoff and Ira N (1991). Dermatomyositis and polymyositis. *Current Problems in Dermatology* **3**(5) 134-180.

Tiniakou E and Mammen AL (2017). Idiopathic Inflammatory Myopathies and Malignancy: a Comprehensive Review. *Clinical Reviews in Allergy & Immunology* **52**(1) 20.

Torre LA, Bray F, Siegel RL et al., (2012). Global Cancer Statistic. *Ca A Cancer Journal for Clinicians* **65**(2) 87-108.

Zampieri S, Valente M, Adami N et al., (2010). Polymyositis, dermatomyositis and malignancy: a further intriguing link. *Autoimmunity Reviews* **9**(6) 449-53.

Zhou YN, Chen AM, Zhou NH et al., (2012). Clinical analysis of patients with dermatomyositis complicated with malignancies. *Journal of Clinical Dermatology* **41** 133-135.