

Case Report

RECTAL STENOSIS IN A 6 YEARS OLD MALE CHILD

*Thakur V K¹, Hassan Z¹, Kumar V¹, Yadav RD¹, Rahul SK¹ and Kumar S²

¹Department of Paediatric Surgery, IGIMS, Patna-800014, India

²Department of Anaesthesiology & Critical Care, IGIMS, Patna-800014, India

*Authors for Correspondence

ABSTRACT

A number of congenital anomalies are frequently reported in children but congenital rectal stenosis is not so frequent. Rectal stenosis may be acquired or congenital, but when it is due to developmental defect called congenital rectal stenosis, which is usually very rare, while expecting acquired rectal stenosis in children is not easy and usually delayed appearance of such rectal stenosis creates perplexing to concerned clinician. Here, we are reporting a case of 6 years male child presented with complaint of soiling with faeces. On history he had been suffering from repeated episodes of loose motion. His rectal orifice was normal, but during digital rectal examination finger could not be able to go up into the rectum due to its narrowed lumen. Contrast enema examination showed hugely dilated rectum and sigmoid colon. For this primarily transverse loop colostomy was done and after six months second stages operation posterior sagittal anorectoplasty done along with excision of narrow segment from the distal part of rectum. During postoperative follow up the child was fine except faecal incontinence for initial few months.

Keywords: Congenital Rectal Stenosis, Contrast Enema Examination, Dilated Rectum and Sigmoid Colon

INTRODUCTION

Rectal stenosis is not a common anomaly in children. Congenital rectal stenosis is a developmental anorectal malformation and is considered to be a rare variant of high type. Acquired rectal stenosis of adult type in paediatric age group, is still very difficult to predict. Delayed presentation of rectal stenosis makes it confusing whether rectal stenosis is causing the problem or a complication of chronic inflammation itself.

CASES

A 6-year old male child presented with history of recurrent loose motion for past few years. Patient was treated for diarrhoea and dehydration on many occasions. Recently, he started to have faecal soiling for which surgical opinion was sought. There was no history of constipation or delayed passage of meconium. Patient was asymptomatic five years ago. On examination he was underweight for his age. Abdomen was found distended and non tender. Digital rectal examination anal orifice was normal, rectum was found of very small calibre and finger could not be negotiated up into the rectum. Haematological profiles were normal except low haemoglobin and low serum protein. X-ray abdomen was suggestive of excess gaseous prominence and colonic obstruction (Figure 1). Rectum and sigmoid colon were found hugely dilated on contrast enema examination.

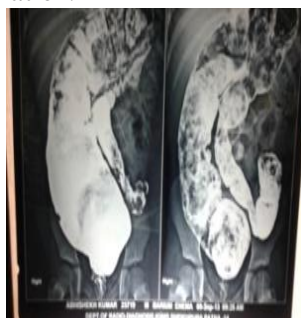


Figure 1: Barium Enema

Case Report

After pre-anaesthetic evaluation the patient was operated for transverse loop colostomy for diversion under general anaesthesia. In second stage after six months, patient was operated for posterior sagittal anorectoplasty. A narrow segment of 4-cm length found in distal part of rectum was excised (Figure 2). Anorectal anastomosis was done (Figure 3). Post operative anal dilatation was advised. After confirming adequacy of anastomosis, continuity of gut was restored. Histopathologic examination of resected specimen was suggestive of chronic inflammation and associated fibrosis. In follow up patient is doing well except faecal incontinence for first few months.

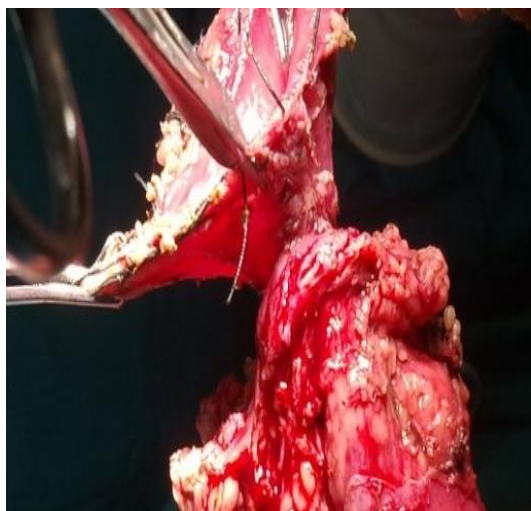

Figure 2: Site of Rectal Stenosis

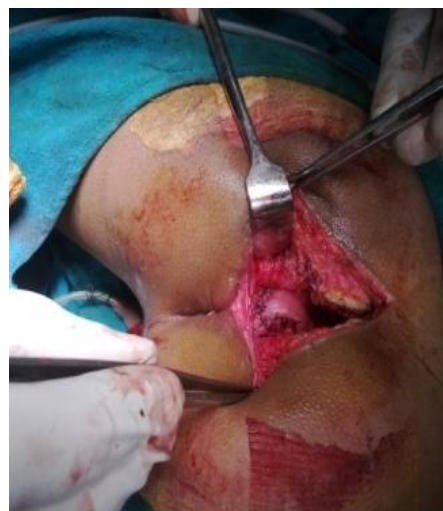

Figure 3: Anorectal Anastomosis

DISCUSSION

Congenital rectal atresia is a rare malformation constitutes for 1-2% of all anorectal malformations, characterized by a normally placed anus and well developed sphincter muscle. In case of delayed presentation, clinical features might be confusing with acquired rectal stenosis (Lieberman and Thorson, 2000). Rectal stricture (Stenosis) is caused by one or a combination of these factors; constipation or straining to have a bowel movement, anal or rectal fissures, trauma, irritation from constant diarrhoea, inflammatory bowel disease or rectal infection. Scar tissue, a product of chronic inflammation is not as flexible as healthy tissue, and the gradual build up can narrow constricting the rectum or anal canal (Kiely *et al.*, 1979).

The longer the stenosis remains untreated, the more severely dilated rectum is encountered. In the worst cases the rectum becomes grossly dilated, insensitive and apparently aperistaltic with serious consequences (Rashid *et al.*, 2008). Constipation being the main symptoms of rectal stenosis must be evaluated carefully in children. Over flow incontinence may present as chronic diarrhoea and even a stenosed anus often allows soft stool to escape easily. This should be kept in mind while evaluating the case of rectal stenosis (Rashid *et al.*, 2008).

Careful digital rectal examination can provide a lot of information in this case. We should look for the absolute size of the anus, suppleness of anal canal, calibre of rectum, whether admitting a finger or just allowing a feeding tube to pass up. It rules out other associated anomalies such as teratoma, duplication cyst and anterior meningo-myelocele that cause extrinsic compression on rectum (Rashid *et al.*, 2008; Weledji Elroy and Motaze, 2016; Gupta, 2005). Proper digital rectal examination can give us an idea even in case of chronic diarrhoea, as it can be over flow incontinence following chronic constipation in rectal stenosis. Barium enema X-ray remains confirmatory and gives idea of rectal calibre (Weledji Elroy and Motaze, 2016). Surgery is the mainstay of treatment. Rectal stenosis is considered to be a high and rare type of anorectal malformation (Garcea *et al.*, 2003). Usually, this is corrected in stages. After diverting colostomy, posterior sagittal anorectoplasty as described by Alberto Pena is performed followed by stoma

Case Report

closure (Gupta, 2005). In acquired cases, same posterior approach is preferred to excise stenosed segment and end to end anastomosis. Endoscopic-guided balloon dilatation using a multi diameter balloon is a simple and safe method for short segment stenosis only (Garcea *et al.*, 2003). Post operative anastomotic calibration using Hegar's anal dilator is a must to avoid anastomotic stricture (Umesh and Sowmya 2015). Histopathology of excised segment is done to rule out various inflammatory conditions involving rectum including tuberculosis. Stage surgical management of these cases whether congenital or acquired, gives us satisfactory result. Children having chronic constipation or even chronic diarrhoea with history of failure to thrive warrant a proper rectal examination and a barium enema x-ray. Rectal stenosis may have a low incidence but might be difficult to diagnose as it can present with overflow incontinence mimicking as chronic infective diarrhoea.

REFERENCES

- Garcea G, Sutton CD, Lloyd TD *et al.*, (2003).** Management of benign rectal stricture a review of present therapeutic procedures. *Diseases of the Colon & Rectum* **46** 1451-60.
- Gupta DK (2005).** Anorectal Malformation-Wingspread to Krickbeck. *Journal of Indian Association of Pediatric Surgeons* **10** 75-77.
- Kiely EM, Chopra R and Corkery JJ (1979).** Delayed diagnosis of congenital anal stenosis. *Archives of Disease in Childhood* **54** 68-79.
- Liberman H and Thorson AG (2000).** How I do it? Anal stenosis. *The American Journal of Surgery* **179** 325-9.
- Rashid KA, Wakhlu A, Tondon RK *et al.*, (2008).** Anorectal junction stenosis: diagnosis and management. *European Journal of Pediatric Surgery* **18** 303-6.
- Umesh N and Sowmya M (2015).** Clinical study of anorectal malformation. *Journal of Evolution of Medical and Dental Sciences* **4** 1466-73.
- Weledji Elroy P and Motaze S (2016).** Delay in diagnosis of congenital anal stenosis. *Journal of Pediatric Surgery Case Reports* **6** 5-8.