

## Case Report

# CENTIPEDE CAUSING OTITIS EXTERNA - A RARE CASE REPORT

\*Taruna Swami<sup>1</sup>, Reena Goyal<sup>1</sup>, Deep Shikhar Acharya<sup>1</sup> and Sohan Lal<sup>2</sup>

<sup>1</sup>Department of Microbiology & Immunology, Sardar Patel Medical College, Bikaner (Rajasthan), India

<sup>2</sup>Department of E.N.T, Sardar Patel Medical College, Bikaner (Rajasthan), India

\*Author for Correspondence

## ABSTRACT

A 12 Yr old boy came to ENT OPD with c/o itching sensation in right ear since 2 day. Itching was off and on, there was no other complaint. Patient was advised to take antihistaminic drug but was not recovered and complained of having foreign body sensation. On examination nothing significant finding was observed then the treating clinician put few drops of xylocaine. On subsequent swabbing centipede came out and patient recovered.

**Keywords:** Centipede, Otitis Externa

## INTRODUCTION

The centipedes are arthropods belonging to the class Chilopoda. They are usually nocturnal predators, which are distributed widely in warm, temperate and tropical regions. Their habitat includes underground or rockpiles. The common effects of centipede bite include erythema, in duration and necrosis, as well as mild constitutional symptoms like local pain and pruritis (Norris, 2006; Vazirianzadeh *et al.*, 2007).

## CASES

A 12 Yr old boy came to ENT OPD with c/o itching sensation in right ear since 2 days. Itching was off and on, there was no other complaint. The treating doctor examined the patient and found nothing wrong except some wax and erythema was there.

The clinician who was an intern advised him to take antihistaminic drug like cetirizine for 2 days but the patient came back the next day with same complain with no relief and saying some foreign body sensation like feeling so the clinician put few drops of xylocaine for 15 min and then cleaned the ear with sterile swab stick.

He found some brownish red thread like structure on swab which he sent to microbiology lab suspecting some worm.

The worm was taken on slide, some normal saline was added and cover slip was applied. On scanning and subsequently low power microscopy, the worm was suspected as an arthropod as it was of 3-4 cm in size, segmented and each segment was bearing one pair of legs.

The picture was taken (photo 1-4) and expert opinion of Entomologist was accounted who confirmed it as centipede. On further investigation it was found that patient was from rural background and engaged in farming work with his father.

## DISCUSSION

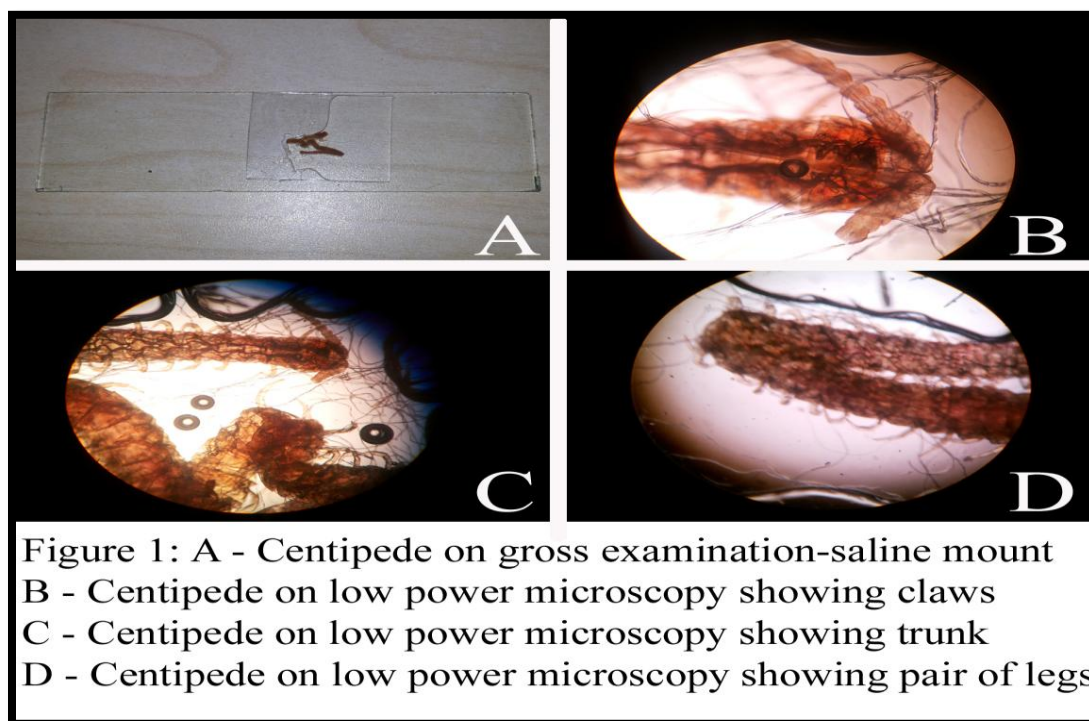
Centipedes are elongated, multi-segmented arthropods with a single pair of legs on each body segment. They spend most of their time underground or beneath rockpiles and usually come out at night to actively hunt their prey. Their size varies from few mm to 30 cm which are larger ones (Minton and Bachtel, 1995; Ozsarac *et al.*, 2004).

Small centipedes may scratch a person without breaking the skin whereas larger centipedes have strong jaws and can cause painful bites. In this particular patient probably the worm crawled inside while he was sleeping.

The size of worm is 3-4 cm approximately and has not caused much harmful effect in patient except some discomfort and erythema. As the patient was perfectly alright after the worm was taken out of ear this relates the worm as causative agent of otitis externa.

This is first case report of centipede causing otitis externa in India to our existing knowledge so far.

### Case Report



### ACKNOWLEDGEMENT

We are thankful to Dr V. S. Acharya, Assistant Professor, Entomology, S.K.K. University Bikaner for identification of worm as centipede.

### REFERENCES

- Minton SA and Bachtel HB (1995).** Arthropod envenomation and parasitism. In Auerbach PS, edition *Wilderness Medicine: Management of Wilderness and Environmental Emergencies*, 3 edition, (USA, St Louis, MO, Mosby) 742-768.
- Norris RL (2006).** Centipede envenomation, *Medicine Specialities* 1 1
- Ozsarac M, Karcioglu O, Ayric C, Somuncu F and Gumrukcu S (2004).** Acute coronary ischemia following centipede envenomation: case report and review of literature. *Wilderness and Environmental Medicine* 15 109-112.
- Vazirianzadeh B, Rahmani HA and Maravvej SA (2007).** Two cases of Chilopoda (centipede) biting in human from Ahwaz, Iran. *Pakistan Journal of Medical Sciences* 23 956-958.