

## Case Report

# MYELOPEROXIDASE EXPRESSION IN ACUTE LYMPHOBLASTIC LEUKEMIA- A RARE CASE REPORT

\*Ashim Manta, Nitu Mani Khakhlari, Gayatri Gogoi and Projnan Saikia

Department of Pathology, Assam Medical College, Dibrugarh

\*Author for Correspondence

## ABSTRACT

Expression of myeloperoxidase (MPO) is considered diagnostic in acute myeloid leukemias (AML). Whereas the expression of MPO in lymphoblastic leukemia is very unusual. Herein we report a case of MPO positive, in otherwise typical acute lymphoblastic leukemia (ALL) without the expression of other myeloid markers. Complete haemogram showed anaemia with leukocytosis. Peripheral blood smear revealed fair numbers of blasts with thrombocytopenia. Cytochemistry was negative for MPO. Immunophenotyping revealed positivity for CD10, HLA DR, CD19, CD79a, CD20, and MPO. Impression: B-cell ALL with MPO positivity. The study primarily shows that MPO expression in childhood acute leukemia revealing typical lymphoblastic morphology does rarely exist.

**Keywords:** Myeloperoxidase (MPO), Acute Lymphoblastic Leukemia (ALL)

## INTRODUCTION

Acute lymphoblastic leukemia (ALL) is the most common childhood malignancy, accounting for approximately 30% of all childhood malignancies (Wintrobe's, 12th edition). It is a neoplastic disorder that is rapidly fatal if untreated. The diagnosis and lineage assignment of acute leukemias follow the criteria of the French-American British (FAB) Cooperative Group and rely on morphology and cytochemical analysis. The presence of greater than 3% myeloperoxidase (MPO) positive leukemic blasts by light microscopy is considered as the diagnostic criteria for acute myeloid leukemia (Kantarjian *et al.*, 1990).

Recent studies have demonstrated lineage fidelity (myeloid or lymphoid) is not preserved in many cases of acute leukemia. Lineage heterogeneity has been pursued through morphological, cytogenetic, immunophenotyping and molecular studies (Kantarjian *et al.*, 1990).

Here we present a case of acute lymphoblastic leukaemia which showed MPO as the only myeloid marker positive in the blasts population detected by flowcytometry.

## CASES

The patient was a 14 year old female who presented in the paediatrics out patient department with the symptoms of headache, fever, bleeding gums and abdominal distension for 2 weeks. Blood sample for complete haemogram and peripheral blood smear examination were studied. Subsequently cytochemistry and immunophenotyping were done.

Clinically patient had pallor and hepatosplenomegaly Routine blood examination revealed anemia and marked leukocytosis. Differential count showed 75% of blasts.

Peripheral blood examination smear revealed severe microcytic hypochromic anemia, moderate anisocytosis and microspherocytes. There was marked leukocytosis with fair number of blasts and thrombocytopenia. Two populations of blasts were seen with predominance of small blasts showing scanty cytoplasm and inconspicuous nucleoli while another population of blasts had abundant cytoplasm showing one to two nucleoli.

Morphological diagnosis: ALL L2 (figure 1 & 2)

Cytochemistry was negative for Myeloperoxidase (MPO).

Immunophenotyping was done in BD FACS Canto II machine. Sample was prepared by Stain-lyse-wash method, number of events acquired were 10,000; number of events gated were 7485 (74.9%) on SSC/CD45 plot; around 12% of the blasts population showed MPO positivity with dim intensity. No

### Case Report

other myeloid markers were positive. Immunophenotyping revealed positivity for CD19, CD79a, C10, CD20, HLA DR, Tdt & MPO.

**Impression:** B-cell ALL with dim MPO expression.

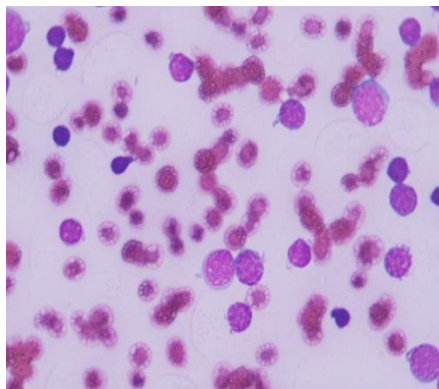


Figure 1: PBS 100x view showing blasts

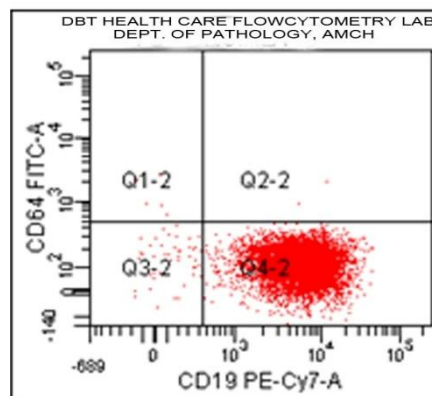


Figure 2: CD19 positive

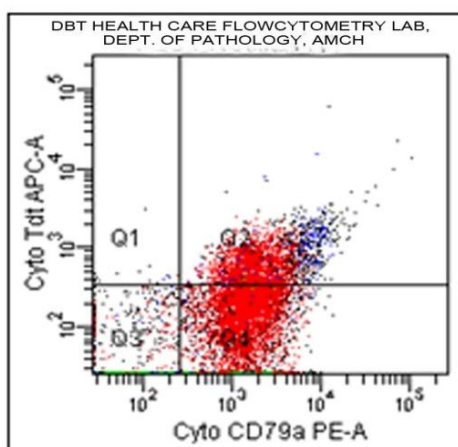


Figure 3: CD79a positive

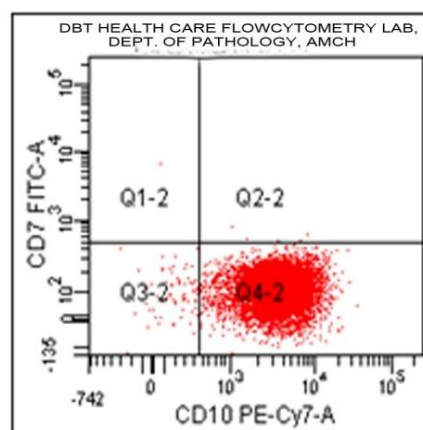


Figure 4: CD10 positive

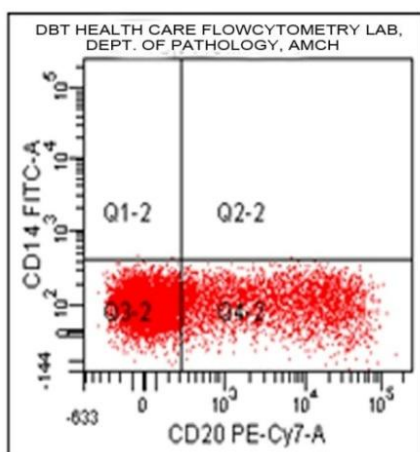


Figure 5: CD 20 positive

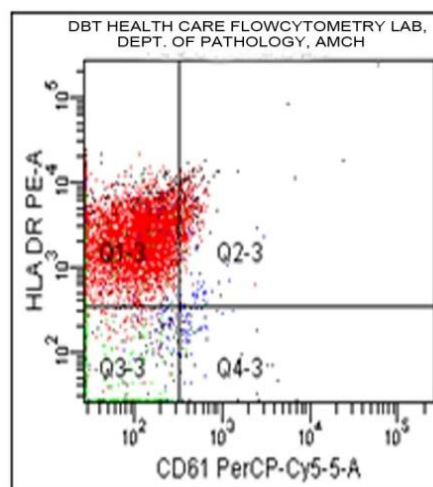
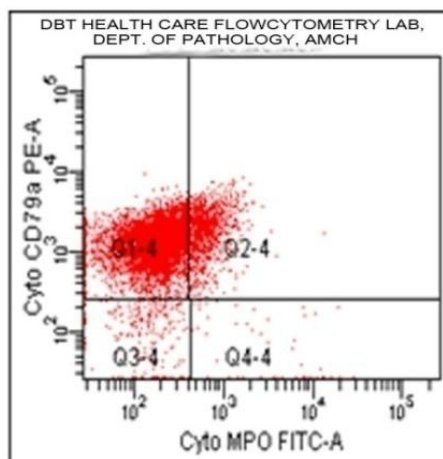


Figure 6: HLA DR positive

## Case Report



**Figure 7: MPO positive**

## DISCUSSION

We studied a total of 102 cases of Acute Leukemia, of which 32 cases were ALL and MPO with dim expression as single myeloid marker was found in only one case.

Cytochemistry was negative for MPO. However, immunophenotyping revealed ~12.% of the cells with Myeloperoxidase positivity. All the other markers of myeloid/monocytic lineage were negative. The cells were typically of the B-cell ALL type with strong positivity for B lymphoid markers.

Rytting *et al.*, (2009) studied 5 cases of adult ALL that demonstrate typical ALL immunophenotypes without myeloid surface markers but show strong (>20%) MPO activity by enzymatic (functional) and immunologic (flow cytometric) methods.

Tauchi *et al.*, (1991) studied a case of ALL that expressed CD10, CD19, CD20, HLA-DR, Cytochemistry was negative for MPO, but ultrastructural study demonstrated some of the cytoplasmic granules with MPO positivity.

Serrano *et al.*, (1997) described two cases of acute leukemia in which blast cells had lymphoid morphology, ultrastructure, immunophenotype and molecular rearrangements, but expressed significant levels of MPO gene (MPO mRNA) by reverse transcriptase polymerase chain reaction (RT-PCR), in the absence of translation to protein.

Kantarjian *et al.*, (1990) reported seven adult patients with untreated acute lymphocytic leukemia (ALL) who manifested 5% to 40% myeloperoxidase (MPO) -positive blasts by electron microscopy (EM).

## Conclusion

Myeloperoxidase (MPO) is an enzyme found primarily in the granules of myeloid cells. MPO positivity has been considered the hallmark that distinguishes ALL from acute myeloid leukemia, despite the numerous surface markers that are currently used to characterize leukemias. However, several recent reports indicated that ALL cells also may exhibit MPO mRNA and even MPO protein. So this suggests there can be expression of lineage-specific genes in acute leukemia cells with diverse phenotypic characteristics. The presented case is a B cell ALL showing strong positivity for all the B lymphoid markers but significant percentage of the blasts showing MPO (dim expression) as the positive myeloid marker. This might add a dilemma whether to categorize it as Mixed phenotypic acute leukemia. We analysed the findings according to scoring system of European group for the immunological classification of leukemias (EGIL) and the scoring is less than 2. So it can be concluded that it is a case of B cell ALL with coexpression of a myeloid marker i.e. MPO.

## REFERENCES

**James A Whitlock and Paul S Gayon (1889).** Acute Lymphoblastic Leukemia in children. *Wintrobe's Clinical Hematology*, 12th edition 2.

### **Case Report**

**Kantarjian H, Hirsch-Ginsburg C and Yee G et al., (1990).** Mixed-lineage leukemia revisited: Acute lymphocytic leukemia with myeloperoxidase-positive blasts by electron microscopy. *Blood* **76** 808–813.

**Rytting M, Kantarjian H and Albitar M (2009).** Acute Lymphoblastic Leukemia with Burkitt-like Morphologic Features and High Myeloperoxidase Activity. *American Journal of Clinical Pathology* **132** 182-185.

**Serrano J, Roman J, Sanchez J and Torres A (1997).** Myeloperoxidase gene expression in acute lymphoblastic leukemia. *British journal of Hematology* **97** 841-843.

**Tauchi T, Ohyashiki K, Ohyashiki JH, Saito M, Nakazawa S, Enomoto Y, Hosoda Y and Toyama K (1991).** Acute lymphoblastic leukemia with azurophilic granules that contain ultrastructural Myeloperoxidase activity. *American Journal of Hematology* **36**(4) 288-90.