

Case Report

INFECTED NON-UNION TIBIA TREATED BY DOUBLE CORTICOTOMY AND BONE GRAFTING USING LIMB RECONSTRUCTION SYSTEM

Pankaj Kumar and *Sunil Saini

Department of Orthopaedics, Assam Medical College and Hospital, Dibrugarh, Assam

*Author for Correspondence

ABSTRACT

The specific method of skeletal fixation and soft tissue management in open fracture of tibia, continues to be a topic of debate in orthopaedic traumatology. These open fractures with infection are commonest cause of infected non-union with bone gap. Infection is found in both soft tissue and bone ends in most cases of infected non-union tibia. Thorough debridement followed by reconstruction, also lead to the formation of a large gap. We present a case of infected non-union tibia, where union was achieved with LRS application, later re-arrangement of schanz pins and autogenous cancellous bone grafting were done at docking site.

Keywords: Bone Grafting, Limb Reconstruction System, Non-union

INTRODUCTION

Tibia is the most common major long bone to be affected by open fractures. Open fractures with infection are perhaps the most common cause of infected non-union with bone gap. Infection is found in both soft tissue and bone ends in most cases of infected non-union tibia (ElRosasy, 2007). Thus, while attempting reconstruction, both the bone and soft tissue need to be debrided extensively, which may also lead to the formation of a large gap. Infected non-union is a state of failure of union and persistent infection at the fracture site for 6-8 months and union is not likely to occur without active intervention (Harilaos *et al.*, 1964). After radical debridement, it presents with a large gap of bone as well as soft tissues, which is usually managed by either Ilizarov apparatus or Limb Reconstruction System (LRS). Distraction osteogenesis using external fixator is the key to bridge both soft tissue and bony defect if the gap is more than 3 cm (Meyer *et al.*, 1975; Canale *et al.*, 2008). It involves mechanical induction of new bone formation between bony surfaces that have been gradually pulled apart. Bone transport may have various docking site problems including non-union. The disadvantage of Ilizarov ring fixator system include heavy frame, increased chances of pin track infection, joint stiffness, difficult surgical technique, and decreased patient compliance (Canale *et al.*, 2008; Rozbruch *et al.*, 2006). We present a case of non-union at docking site managed by double corticotomy and autologous iliac cancellous bone grafting to achieve bony union using LRS.

CASES

A 22 year old male patient, who was a post-operative case of Type IIIA Open (GUSTILO & ANDERSON) fracture both bone, with right leg operated elsewhere by CRIF and IM interlock nail, presented to the Orthopaedics Department, AMCH after 7 months with infected non-union. The patient was treated with IM nail removal, radical wound debridement and necrotic bone removal till punctate bleeding was found (Paprika sign). The radical debridement resulted in a bone gap of 6cms between the fragments. LRS was then applied in anteromedial plane maintaining the limb length discrepancy.

For the control of infection and wound healing, parenteral antibiotics were given for two weeks followed by oral antibiotics (after pus culture reports). Along with this, corticotomy was done at proximal tibial metaphysis & distraction was started on 7th day at the rate of 1mm/day (Figure 1).

On follow-up, docking site non-union with pin tract infection developed at the distal end after six months of LRS application (Figure 2). After this LRS rearrangement was done (Figure 3), which involved changing placement of Schanz pin from anteromedial to the anterior plane after wound debridement and

Case Report

necrotic bone removal. LRS was applied with four templates and corticotomy was done at the distal diaphyseal-metaphyseal junction. Distraction was started after seven days at the rate of 1mm/day, but we still faced the complication of docking site non-union even after six months of second corticotomy. Following this, a fresh autogenous iliac cancellous bone graft was done at docking site after removal of dead and necrotic tissues (Figure 4). At two and half year follow up of the patient, a complete bony union was achieved & LRS removal was done after six months of fracture consolidation (Figure 5).

DISCUSSION

External fixation has been the skeletal stabilization of choice with the lowest reported deep sepsis rates with relatively high rate of fracture union, pin tract infection, malunion, and nonunion and most complications can be successfully managed without frame removal (Dervin *et al.*, 1996; Keeling *et al.*, 2008).

The main options available for infected non-union with bone loss are –Bone grafting with soft tissue reconstruction and distraction histogenesis with Ilizarov ring fixator or Monorail fixator.

Ilizarov is a complex technique requiring a lot of resources and time, and it also has numerous complications (Paley *et al.*, 1990).

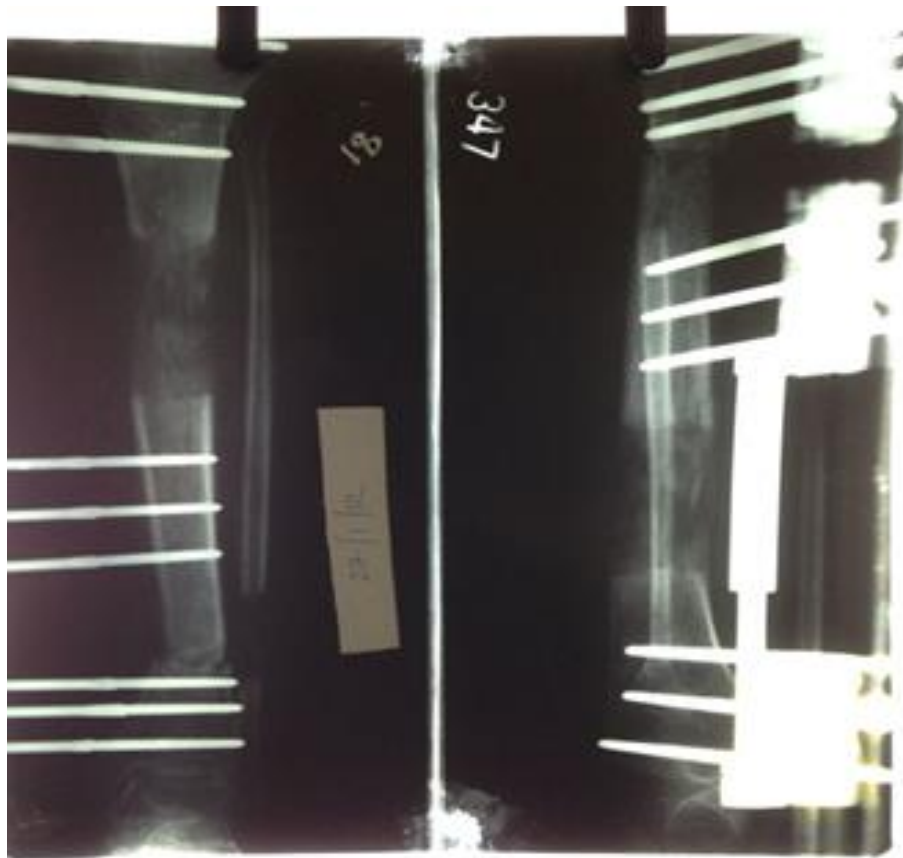


Figure 1: LRS application, Corticotomy and Distraction

LRS is based on the same principles as that of Ilizarov and has a short learning curve. It is a light weight, easy to construct, uniplanar dynamized external fixator which provides stable external fixation. Also by changing the stiffness of fixation, the fracture environment can be more precisely controlled.

Edwards in his large series of open Grade III tibial fractures treated with LRS reported union rate of 93% with a median time of nine months and the healing time and satisfactory clinical function of 89% (Edwards *et al.*, 1988).

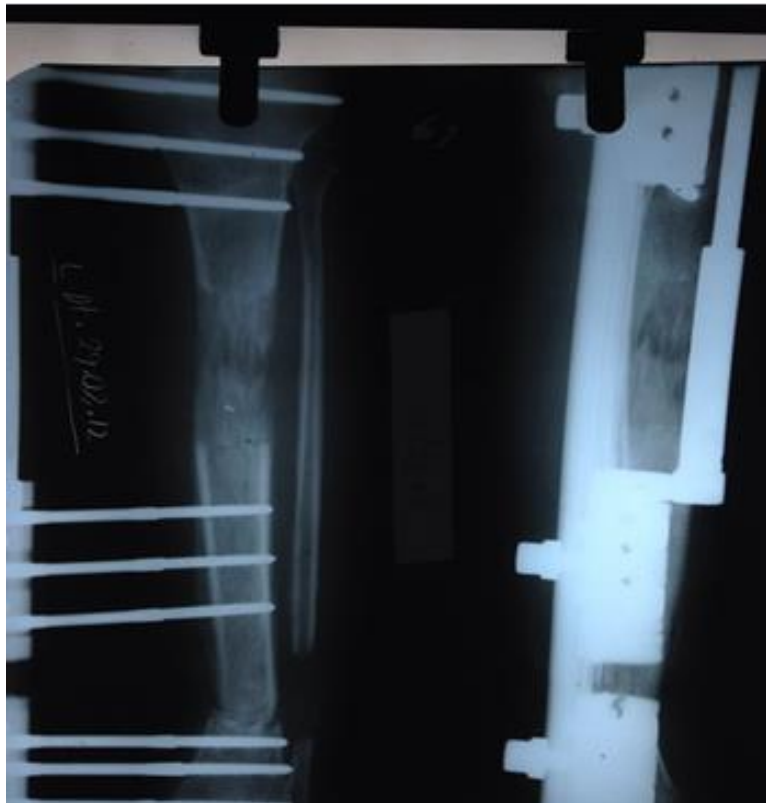


Figure 2: Docking site non-union with pin tract infection

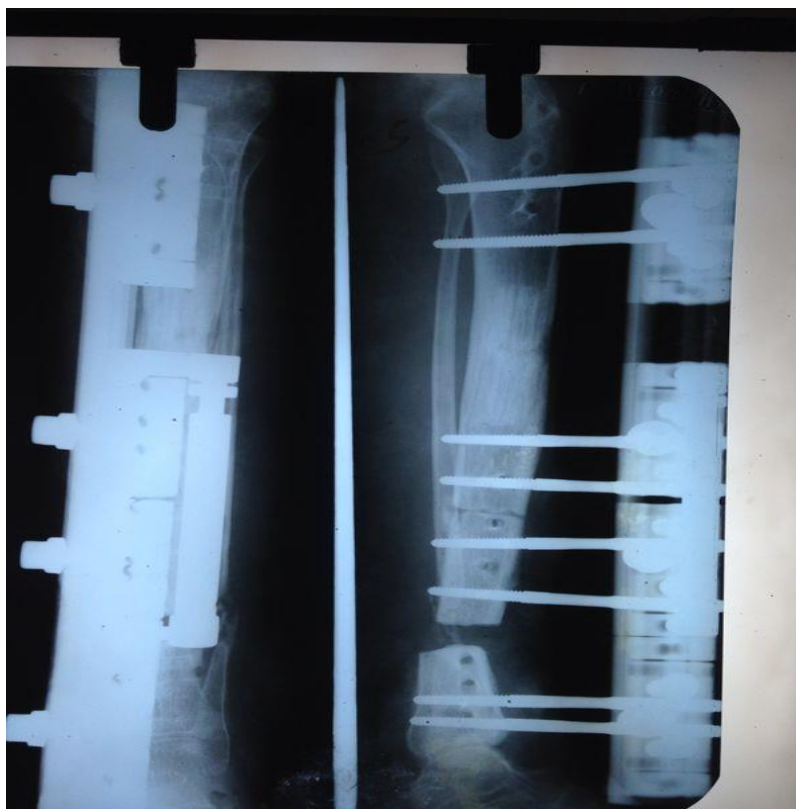


Figure 3: LRS re-arrangement and distraction at rate of 1mm per day

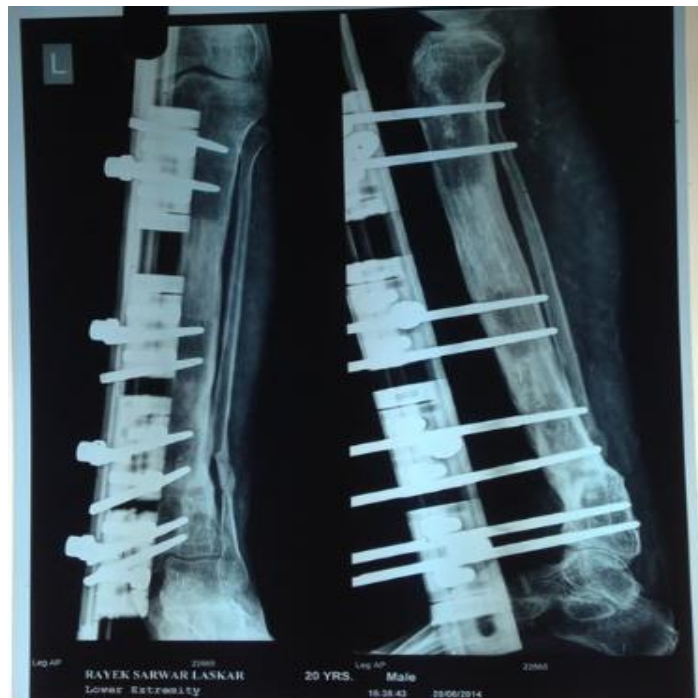

Figure 4: Fresh autogenous iliac cancellous bone grafting at docking site

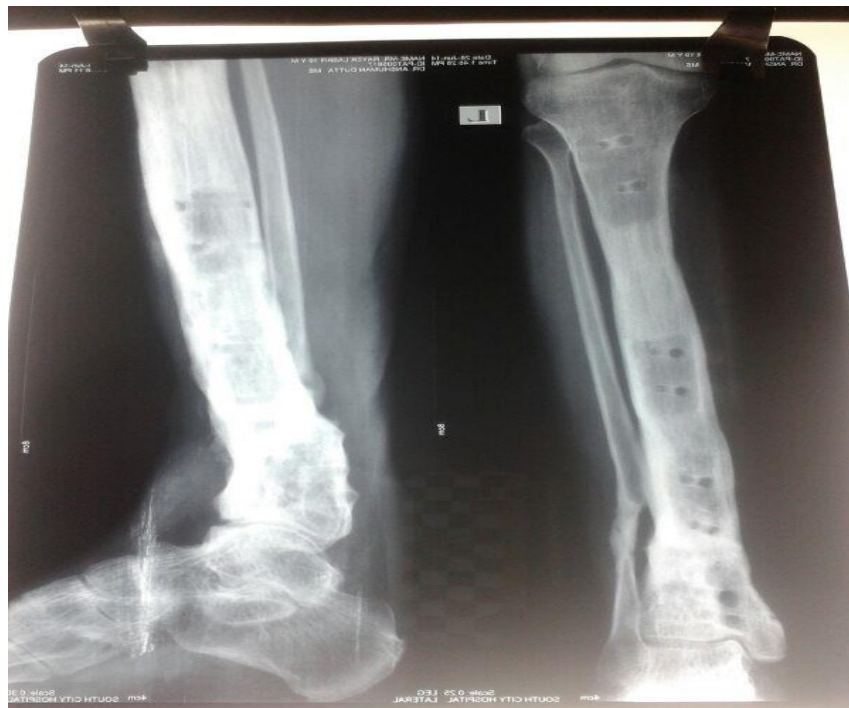

Figure 5: Follow up at 21/2 year, union achieved, LRS removal

Due to its strong construct and variable spread of fixation, LRS is found to be mechanically very stable. Also, no additional major surgery is needed after application except the one for adjustment in alignment (Seenappa *et al.*, 2013). Definitive contributing factors for the better results are the experience of the surgeon and patients commitment.

Case Report

Conclusion

Bone transport with LRS is a safe, effective, and minimally invasive technique to treat post-traumatic tibial infected non-union with a bone defect. LRS is a versatile mono lateral external fixator through which revision and reapplication in different angulations can be done to achieve bony union.

REFERENCES

- Canale S and Beaty J (2008).** *Delayed Union*, 11th edition (Elsevier) 3529-3575.
- Dervin GF (1996).** Skeletal fixation of grade IIIB tibial fractures, The potential of metaanalysis. *Clinical Orthopaedics and Related Research* **332** 10-15.
- Edwards CC, Simmons SC, Browner BD and Weigel MC(1988).** Severe open tibial fractures. Results treating 202 injuries with external fixation. *Clinical Orthopaedics and Related Research* **230** 98-115.
- ElRosasy MA (2007).** Acute shortening and re-lengthening in the management of bone and soft-tissue loss. *Journal of Bone and Joint Surgery* **89-B** 80-88.
- Harilaos Tand Sakellarides Peter A et al., (1964).** Delayed Union and Non-Union of Tibial-Shaft Fractures a review of 100 cases. *Journal of Bone and Joint Surgery* **46** 557-569.
- Keeling JJ, Gwinn DE, Tintle SM, Andersen RC and Fx M (2008).** Short-term outcomes of severe open wartime tibial fractures treated with ring external fixation. *Journal of Bone and Joint Surgery American Volume* **90**(12) 2643-51.
- Meyer S, Weiland AJ and Willeneger H (1975).** The treatment of infected non-union of fractures of long bones. *Journal of Bone and Joint Surgery* **57A** 836-842.
- Paley D (1990).** Problems, Obstacles and complications of limb lengthening by the Ilizarov technique. *Clinical Orthopaedics and Related Research* **250** 81-104.
- Rozbruch SR and Ilizarov S (2006).** Simultaneous treatment of tibial bone and soft-tissue defects with the Ilizarov method. *Journal of Orthopaedic Trauma* **20** 197-205.
- Seenappa H, Shukla MK and Narasimhaiah M (2013).** Management of complex long bone nonunions using limb reconstruction system. *Indian Journal of Orthopaedics* **47**(6).