Indian Journal of Medical Case Reports ISSN: 2319–3832(Online)
An Online International Journal Available at http://www.cibtech.org/jcr.htm
2013 Vol.2 (3) July-September, pp.35-38/Ece et al.

Case Report

CHRYSEOBACTERIUM INDOLOGENES PNEUMONIAE IN A PATIENT WITH ACUTE MYELOID LEUKEMIA

***Gulfem Ece[1], Serkan Ocakci[2] and Seckin Cagirgan[2]**
[1]*Izmir University School of Medicine, Department of Medical Microbiology*
[2]*Izmir University School of Medicine, Department of Internal Medicine Hematology Unit*
**Author for Correspondence*

ABSTRACT
Acute myeloid leukemia (AML) is an aggressive and frequently fatal hematological malignancy.*Chryseobacterium* spp. are Gram-negative bacilli which is found in soil and water. In hospital environments, they are isolated from water systems and wet medium. Infections caused by *Chryseobacterium indologenes* are rare. Risk factors for *C. indologenes* can be underlying disorders, immunosuppression and indwelling catheters. We reported a patient with pneumoniae infection due to *C.indologenes* and diagnosed with acute myeloid leukemia. We aimed to present this case to emphasize the importance of infections due to rare pathogens in patients with hematological malignities and appropriate treatment.

Key Words: *C.indologenes,Acute Myeloid Leukemia, Gram Negative Bacilli, Pneumoniae*

INTRODUCTION
Acute myeloid leukemia (AML) is an aggressive and frequently fatal hematologic malignancy (Fathi and Chen, 2011). The disease in which too many immature white blood cells that are not lymphoblasts are found in the bone marrow and blood (National Cancer Institute).
Chemotherapy administration and immunosuppressive treatment in AML patients are more prone to infections. Besides these patients are undergoing invasive procedures and indwelling catheters which are also risk factors for infection as well.
Chryseobacteria are Gram negative bacilli and and nonfermentative. This is an unusual human pathogen mostly isolated from various sources in the hospital setting. Most infections were found in hospitalized patients with underlying disorders and indwelling catheters. Although they posess less virulence, they are resistant to many antimicrobial agents (Bhuyar *et al.*, 2012).
We aimed to present this case to emphasize the importance of infections due to rare pathogens in patients with hematological malignities and appropriate treatment.

CASES
32 year old male patient was admitted to a tertiary care in Izmir province. The complete blood count (CBC) report showed 195000/mm^3 leukocytes, Hb: 6.8 g/ml, platelet: 195000/mm^3. Peripheral smear revealed 92% blast formation. Bone marrow aspiration and biposy was carried out. He was diagnosed as acute myeloid leukemia (AML). His leukocyte count was 116100/mm3, Hb:8.2 g/dl and platelet count was 116100/mm3. Hydroxy urea 3g/day was initiated. Then he was admitted to Izmir University School of Medicine Medicalpark Hospital Department of Hematology.
The physical examination of the patient was normal except bilateral inguinal LAP and 1 cm hepatomegaly. Fever was not detected. The patient was administered cytosine-arabinoside/daunorubicin (200mg/m^2/day). On the sixth day of hospitalization, the patient developed neutropenic fever. Blood, and urine cultures were taken due to neutropenic fever. Sputum culture was taken because of cough complaint on the sixth day. The Gram stain of the sputum culture showed polymorphonuclear leukocytes and Gram negative bacilli. The sputum was cultivated on blood agar, eosin methylene blue agar and chocolate agar. Lung X-ray image revealed no pathological symptoms (Figure 1). Prophyilactically valacyclovir, posaconazole and levofloxacin treatment were initiated. Neutropenic fever continued on the eighth day.

Case Report

Urine culture did not report growth. The colonies of the sputum culture were smooth, circular, yellow-pigmented on sheep blood agar (Figure 2). The identification and the antimicrobial susceptibility was studied by automatized Vitek system version 2.0 (Biomerieux, France). The isolate was identified as *Chryseobacterium indologenes*. The strain was susceptible to quinolones. The patient continued quinolone treatment. Enviromental cultures were taken and no growth was detected after two days. The patient was not considered as colonisation due to this report and immunosuppression. Urine, blood and sputum cultures were repeated. Neutropenic fever continued on the tenth day. The second sputum culture reported *C.indologenes*. On the tewelveth day cough and sputum symptoms continued. Simultaneously blood, urine and sputum cultures were taken. Third sputum culture also reported *C.indologenes*. Tazobactam/piperacillin was added to treatment according to antibiotic susceptibility pattern because of cough and sputum symptoms continued. During this period the patient was interpreted as pneumoniae due to elonged neutropenia which did not reveal radiological findings. First blood culture was negative. Second blood culture reported Coagulase Negative Staphylococci. Teicoplanin (800mg/day) was initiated. Control cultures did not reveal any pathological results. On the eighteenth day antibiotherapy continued. All of the cultures were negative. Neutropenic fever was partially controlled. On the twentieth day the fever was partially controlled and neutropenic period was finished. On the twenty second day the general status of the patient was fine. Antibiotic therapy was discontinued. At the twentysixth day %2 blast formation was detected in control bone marrow aspiration and total remission was achieved and was discharged. The patient had allogenic bone marrow transplantation. The transfer was sucessfully done.

RESULTS AND DISCUSSION

Discussion

Chemotherapy administration and immunosuppressive treatment in AML patients are more prone to infections. Besides these patients are undergoing invasive procedures and indwelling catheters which are also risk factors for infection as well. Opportunistic and rare infectious pathogens may cause serious problems in these patients *C. indologenes* does not exist in human flora. They can live in in the hospital environment. They can stay in wet surfaces and can act as potential sources of infection (Calderon *et al.*, 2011).

Bayraktar et al reported *Chryseobacterium indologenes* isolated from blood samples from a 5-month-old infant with bloodstream infection. Environmental sampling was performed. The infant was infected by this water (Bayraktar *et al.*, 2007). In our case report there was no cross contamination and the strain was not isolated from enviromental cultures.

Calderon et al reported a case of ventilator-associated pneumonia caused by *C. indologenes* in a newborn baby boy with congenital heart disease. The child recovered with piperacillin-tazobactam (Calderon *et al.*, 2011). Our patient was an adult individual with an underlying hematological disorder and immunosuppression may be a major predisposing factor. Our patient was also treated by tazobactam/piperacillin. In our case report there was not an application of mechanical ventilation.

Chou *et al.*, (2011) reported ten patients with *C. indologenes* bacteremia. The authors think that this microorganism needs to be considered in patients with bacteremia and hospitalized for a long time in intensive care units (Chou *et al.*, 2011).

Christakis et al reported a case of bacteremia not related with a indwelling catheter and caused by *C. indologenes* in a patient with a solid tumor. The patient was not in a neutropenic status and recovered with piperacillin-tazobactam. The authors emphasized that *C. indologenes* infections can take place in patients without having a catheter (Christakis *et al.*, 2005). In our case the patient also had malignity and the patient had piperacillin-tazobactam treatment.

de Souza Ferreira *et al.*, (2010) reported a case of *C. indologenes* isolated from the tracheal aspirate in a patient on prolonged mechanical ventilation. The patient was a 30 year old male and he had high fever not resolved with antipyretics followed by dizziness and dyspnea. He had no respiratory sytem pathology. [8] In our case we reported *C.indologenes* isolated from consecutively collected sputum cultures and the patient

had no cough or expectoration at the admission; but the fever continued. On the sixth day of his admission the patient developed cough and sputum. We also administered levofloxacin treatment relevant with the antibiotic susceptibility pattern and tazobactam/piperacillin was also added according to antimicrobial susceptibility pattern.

We reported a *C.indologenes* pneumoniae infection in a patient with acute myeloid leukemia. We discussed this case in light of current literature. Patients with hematological malignities and under immunosuppressive therapy are under the risk of opportunistic infections. In our case the patient had no radiological sign; but he developed cough and sputum. The sputum culture revealed *C.indologenes;* and the patient was treated according to antibiotic susceptibility pattern. In these cases the isolation of the pathogen and appropriate treatment are important. This case showed that *C. indologenes* is a pathogen that has to be paid attention and it can lead to severe infections.

Figure 1: Lung X-ray image of the patient

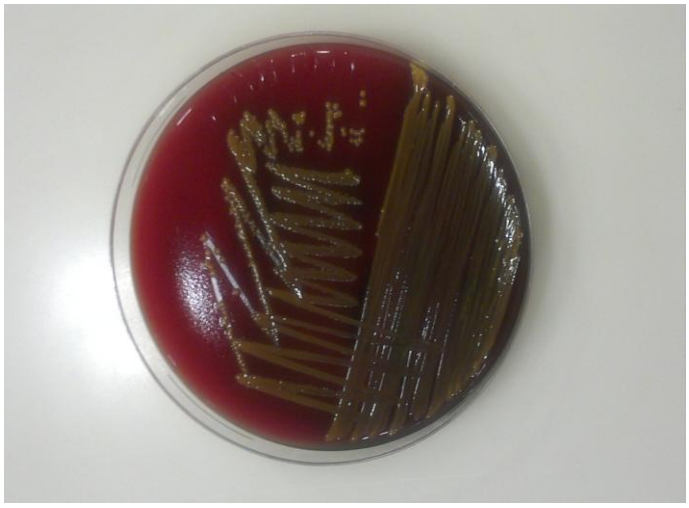

Figure 2: *C.indologenes* isolate on blood agar

REFERENCES

Bayraktar MR, Aktas E, Ersoy Y, Cicek A and Durmaz R (2007). Postoperative Chryseobacterium indologenes Bloodstream Infection Caused by Contamination of Distillate Water. *Infection Control and Hospital Epidemiology* **28** 368-369.

Bhuyar G, Jain S, Shah H and Mehta VK (2012). Urinary tract infection by *Chryseobacterium indologenes*. *Indian Journal of Medical Microbiology* **30** 370-2.

Calderon G, Garcia E, Rojas P, Garcia E, Rosso M and Losada A (2011). *Chryseobacterium indologenes* infection in a newborn: a case report. *Journal of Medical Case Reports* **5** 10.

Chou DW, Wu SL, Lee CT, Tai FT and Yu WL (2011). Clinical Characteristics, Antimicrobial Susceptibilities, and Outcomes of Patients with *Chryseobacterium indologenes* Bacteremia in an Intensive Care Unit. *Japanese Journal of Infectious Diseases* **64** 520-524.

Christakis GB, Perlorentzou SP, Chalkiopoulou I, Athanasiou A and Legakis NJ (2005). *Chryseobacterium indologenes* Non-Catheter-Related Bacteremia in a Patient with a Solid Tumor. *Journal of Clinical Microbiology* **43**(4) 2021–2023.

De Souza Ferreira, Barbosa Brandao FF and Lobo SM (2010). *Chryseobacterium indologenes* infection: a case report Revista Brasileira de Terapia Intensiva **22**(1) 96-98.

Fathi AT and Chen YB (2011). Treatment of FLT3-ITD acute myeloid leukemia. Am J Blood Res **1**(2) 175-189.

National Cancer Institute (No Date). Lukemia. Available at: http://www.cancer.gov/cancertopics/types/leukemia (last acession: 14.07.2013).